

2015

A Case of Phaeohyphomycosis Caused by *Exophiala oligosperma* in a Renal Transplant Patient Successfully Treated with Posaconazole

A. C. Levy
Hofstra Northwell School of Medicine

S Rehman

D.A. Sutton

K.I. Burris
Hofstra Northwell School of Medicine

D.A. Hirschwerk
Hofstra Northwell School of Medicine

See next page for additional authors

Follow this and additional works at: <https://academicworks.medicine.hofstra.edu/publications>

 Part of the [Dermatology Commons](#)

Recommended Citation

Levy AC, Rehman S, Sutton D, Burris K, Hirschwerk D, Wiederhold N, Lindner J, Bhaskaran M, Rilo H, Molmenti E, . A Case of Phaeohyphomycosis Caused by *Exophiala oligosperma* in a Renal Transplant Patient Successfully Treated with Posaconazole. . 2015 Jan 01; 11(1):Article 358 [p.]. Available from: <https://academicworks.medicine.hofstra.edu/publications/358>. Free full text article.

This Article is brought to you for free and open access by Donald and Barbara Zucker School of Medicine Academic Works. It has been accepted for inclusion in Journal Articles by an authorized administrator of Donald and Barbara Zucker School of Medicine Academic Works. For more information, please contact academicworks@hofstra.edu.

Authors

A. C. Levy, S. Rehman, D.A. Sutton, K.I. Burris, D.A. Hirschwerk, N.P. Wiederhold, J. Lindner, M. Bhaskaran, H.L. Rilo, E.P. Molmenti, and +3 additional authors

A Case of Phaeohyphomycosis Caused by *Exophiala oligosperma* in a Renal Transplant Patient Successfully Treated with Posaconazole

¹Asaph C Levy, ¹Sameer Rehman, ²Deanna A Sutton, ¹Katy I Burris, ¹David A Hirschwerk, ¹Sheng Chen, ²Nathan P Wiederhold, ²Hongxin Fan, ²Jonathan Lindner, ¹Madhu Bhaskaran, ¹Nicole M Ali, ¹Horacio L Rilo and ¹Ernesto P Molmenti

¹Hofstra North Shore-LIJ School of Medicine, North Shore University Hospital, North Shore-LIJ Health System Manhasset, NY, United States
²Department of Pathology, Fungus Testing Laboratory, University of Texas Health Science Center at San Antonio, San Antonio, Texas, United States

Article history

Received: 20-04-2015
 Revised: 27-04-2015
 Accepted: 15-06-2015

Corresponding Author:

Asaph C Levy
 Hofstra North Shore-LIJ
 School of Medicine, North
 Shore University Hospital,
 North Shore-LIJ Health System
 Manhasset, NY, United States
 Email: asaphlevy@gmail.com

Abstract: Phaeohyphomycosis is an uncommon mycotic infection caused by dematiaceous fungi. We report a 53-year-old male who presented with phaeohyphomycosis on his upper extremities, 6 months after renal transplantation. Biopsy revealed pigmented moniliform hyphae and cultures grew *Exophiala oligosperma*. The lesions completely resolved after 3 months of treatment with posaconazole.

Keywords: Phaeohyphomycosis, *Exophiala oligosperma*, Dematiaceous, Posaconazole

Introduction

Phaeohyphomycosis is an uncommon infection that is caused by an increasing number of dematiaceous, or pigmented fungi. Infections caused by these pigmented moulds are thought to be opportunistic fungal diseases. The pigment is due to the presence of melanin in their cell walls. Infections can either be localized to subcutaneous tissue, or they can progress to disseminated disease, which can affect solid organs, such as the lungs, as well as the CNS (Murray *et al.*, 2012). Post-transplant mycoses are mostly comprised of mycelial organisms (Schieffelin *et al.*, 2014). There are a large number of these dark genera that cause human infection, however, the most common include: *Alternaria*, *Bipolaris*, *Cladosporium*, *Curvularia*, *Exophiala* and *Exserohilum* species (Murray *et al.*, 2012). Phaeohyphomycosis typically presents as a localized subcutaneous or deep-seated infection; commonly as a cyst or abscess (Pai *et al.*, 2013).

These opportunistic fungal infections are becoming progressively more relevant to post-transplant patients. Fungal infections caused by filamentous fungi make up a large proportion of fungal infections and non-*Aspergillus* species, including those genera inciting

phaeohyphomycosis, make up 27% of invasive mycelial fungal infections (Schieffelin *et al.*, 2014). It is thought that as the number of solid organ transplant recipients continues to increase, as will the incidence of phaeohyphomycosis in these immunocompromised patients (Schieffelin *et al.*, 2014).

Case Report

A 53-year-old retired male with a past medical history of adult polycystic kidney disease, status post kidney transplant 7 years prior and a deceased donor kidney transplant 6 months prior, was incidentally found to have erythematous, non-pruritic, papular lesions on his upper extremities bilaterally, during an admission for Superior Vena Cava (SVC) syndrome (Fig. 1, Supplementary Data). He did not recall any trauma to his arms. He received thymoglobulin and hydrocortisone for induction and was continued on tacrolimus and mycophenolate for his recent transplant. He was then transitioned to cyclosporine and ultimately to belatacept and prednisone for maintenance therapy. His vital signs were stable and he remained afebrile throughout the admission. Upon examination, he was found to have erythematous slightly tender nodules, some with central

vesicles, on bilateral upper extremities. No regional lymphadenopathy was appreciated. Routine labs including complete blood count, basic metabolic panel and hepatic function tests were within normal limits, in the context of his recent transplant. However, due to the patient's immunocompromised state, these lesions raised clinical suspicion for possible infection and dermatology was consulted. A punch biopsy and tissue culture were performed. Histopathology revealed a suppurative granuloma in the dermis containing slightly pigmented moniliform fungal hyphae (Fig. 2 and 3, Supplementary Data). Periodic acid-Schiff (PAS) and Grocott's Methenamine Silver (GMS) staining were positive, confirming fungal infection (Fig. 4, Supplementary Data). Acid Fast Bacilli (AFB) stain was performed, which was negative for mycobacteria. Initial tissue cultures were positive for few mold-like fungi and gram stains were negative. The presumptive diagnosis of phaeohyphomycosis was made at this time. Further identification of the isolate and antifungal susceptibility testing were performed at the Fungus Testing Laboratory at the University of Texas Health Science Center at San Antonio (UTHSCSA), which revealed *Exophiala oligosperma* as the causative pathogen. MRI of the brain and CT scan of the sinuses and chest were all subsequently ordered to evaluate for disseminated infection. All imaging and blood cultures were negative and the diagnosis of subcutaneous phaeohyphomycosis was confirmed. The patient was then started on a course of posaconazole. His posaconazole level was maintained in therapeutic range throughout the admission and he remained compliant upon discharge. The lesions appeared to improve after 10 days of treatment, with marked improvement after 2 months of therapy. The lesions have completely resolved after 3 months of treatment.

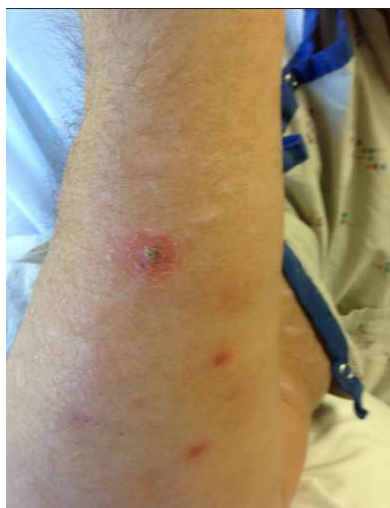

Fig. 1. Multiple erythematous nodular lesions on the posterior aspect of his right forearm

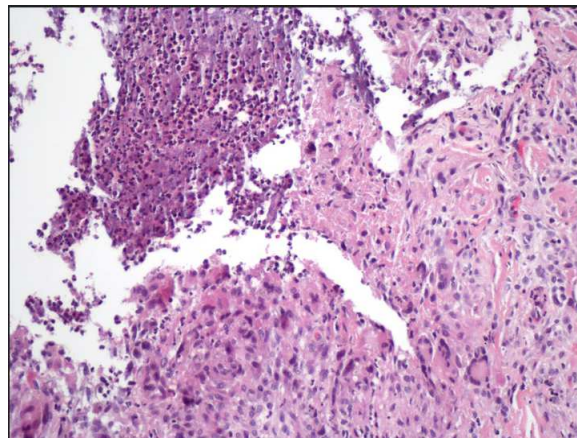


Fig. 2. Skin biopsy shows the presence of suppurative granulomas in the dermis. H and E stain, $\times 20$

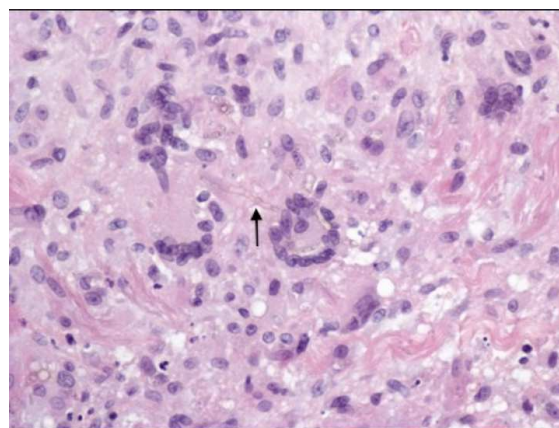


Fig. 3. Scattered light brown fungal organisms (indicated by arrow) are vaguely visible in the background of granulomas. H and E stain, $\times 40$

Mycology

The isolate was accessioned into the Fungus Testing Laboratory collection as UTHSCSA DI15-4. Colonies on Potato Flakes Agar (PFA) prepared in-house were olivaceous to black and initially mucoid, becoming velvety after 12 days of incubation at 25°C (Fig. 5A, Supplementary Data). Microscopic observations on a PFA slide culture under the same conditions revealed both annellated yeast cells and conidia. Anelloconidia were produced from relatively short, inflated conidiogenous cells, as well as from intercalary loci. (Fig. 5B-C, Supplementary Data). For molecular identification, a portion of the cultured isolate was suspended in Buffer G2 (Qiagen, Valencia, CA) followed by lysing in a bead beater instrument (BioSpec Products, Inc., Barlesville, OK). Proteinase K was added and the samples were incubated at 56°C for one hour. After incubation, the DNA was extracted using the EZ1 DNA tissue kit on the BioRobot EZ1 instrument (Qiagen) according to the manufacturers instructions.

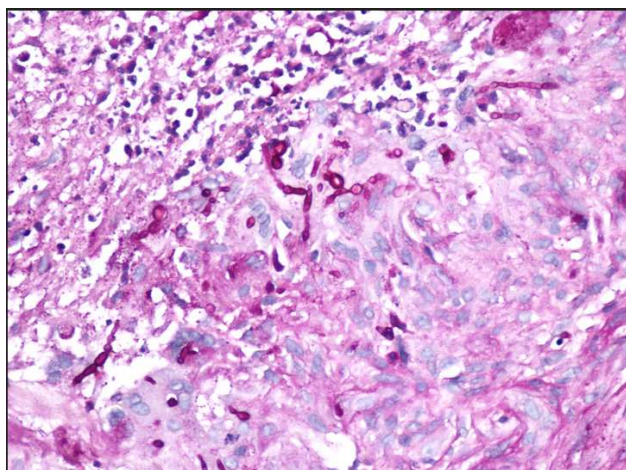


Fig. 4. The presence of many fungal organisms is highlighted by PAS stain. X 40

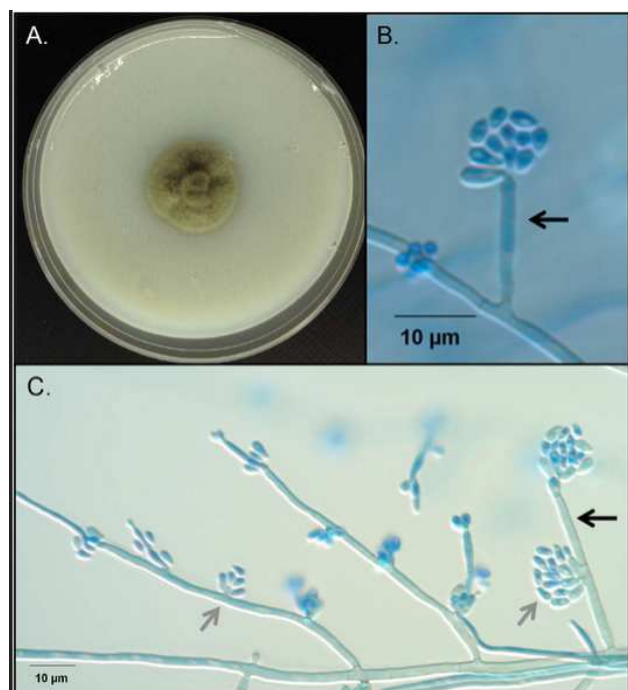


Fig. 5. A. Macroscopic morphology of *E. oligosperma* after 12 days incubation on PFA at 25°C. B and C. Microscopic features of *E. oligosperma* on a PFA slide culture after 12 days incubation at 25°C showing annelloconidia formed from medium-length annellides (dark arrow) as well as from conidiogenous loci along the sides of the hyphae (light arrow)

Extracted DNA was used for PCR amplification of ITS and D1/D2 regions as described (Romanelli *et al.*, 2010). PCR products were then sequenced using the ITS1 and ITS4 primers as well as NL1 and NL4 primers at the UTHSCSA Molecular Diagnostics

Laboratory (White *et al.*, 1990). Sequences were assembled and analyzed using DNASTAR SeqMan Pro version 9.1 (DNASTAR, Inc., Madison, WI) and queried in GenBank using the BLASTn algorithm available on the NCBI site (www.ncbi.nlm.nih.gov) and were also compared to those available in the CBS-KNAW Fungal Biodiversity Centre database (www.cbs.knaw.nl). The ITS sequence showed 100% identity to both *E. oligosperma* (GenBank Accession No. AB480204.1) and *E. jeanselmei* (GenBank Accession No. AJ866273.1), while the D1/D2 sequence showed 100% identity with *E. jeanselmei* (GenBank Accession No. KC311520.1). By barcode analysis, there was 100% match with *E. oligosperma* (UTHSC 91-870) (Heinrichs *et al.*, 2012). Based on the above, the isolate was identified as *E. oligosperma*. The ITS and D1/D2 nucleotide sequences have been deposited into GenBank under accession numbers KP938216 and KP938217, respectively. Antifungal susceptibility testing was performed according to the methods described in the Clinical and Laboratory Standards Institute (CLSI) M38-A2 document for filamentous fungi (CLSI, 2008). The Minimum Inhibitory Concentration (MIC) for amphotericin B was 2 µg MI⁻¹, 8 µg MI⁻¹ for fluconazole and 0.25 µg MI⁻¹ each for posaconazole and voriconazole.

Discussion

E. oligosperma was first described in 2003 by De Hoog *et al.* (2003) by sequencing of its ribosomal DNA. *Exophiala* species are environmental fungi that are associated with decaying wood and soil organic wastes. *E. jeanselmei* is the most frequently cited of the *Exophiala* species as a human pathogen, however sequence data has subsequently shown that *E. jeanselmei* is a species complex and that many of these case reports would represent other species if characterized at the molecular level. The most common clinically relevant species in the United States is *E. dermatitidis* (Zeng *et al.*, 2007). Other species such as *E. moniliae*, *E. oligosperma* and *E. spinifera* have been implicated as well (Zeng *et al.*, 2007). Clinical manifestations for this species include mycetoma, localized cutaneous infections, subcutaneous cysts, endocarditis, and cerebral and disseminated infections (UA, 2001). The cutaneous manifestations are nonspecific, therefore it is important to have a high index of suspicion for fungal infection in order for early diagnosis.

Phaeohyphomycosis is most commonly diagnosed in immunocompromised patients, however, there have been

reported cases of infection in immunocompetent patients; including a case reported by Venkateshwar *et al.* (2014). Over past 12 years there have been a handful of infections with *E. oligosperma*, including a case reported by Rimawi *et al.* (2013) that describes a patient with a 10-year history of lupus and history of severe asthma, taking mycophenolate and methylprednisolone, who was successfully treated for *E. oligosperma* infection with a 3 month course of voriconazole (Rimawi *et al.*, 2013). The included literature review noted 6 other reported cases of *E. oligosperma* infection that were susceptible to voriconazole and included 1 renal transplant patient reported by Gonzalez-Lopez *et al.* (2007). This renal transplant patient presented with phaeohyphomycosis 7 years after transplantation and was successfully treated with a 3-month course of itraconazole; with full resolution (Gonzalez-Lopez *et al.*, 2007). The Gonzalez-Lopez *et al.* (2007) case is similar to ours, as the patient was immunosuppressed with mycophenolate, prednisone, and tacrolimus. However, our patient presented within 6 months of transplantation. Our patient received higher doses of immunosuppressive therapy; which may have been a contributing factor to his earlier development of

phaeohyphomycosis in the postoperative period. A summary of previously reported skin infections with *E. oligosperma* is shown (Table 1) (Bossler *et al.*, 2003; Tokuhisa *et al.*, 2011; Kan *et al.*, 2013; Sato and Yaguchi, 2013; Fukai *et al.*, 2013).

Optimum treatment has been thought to be surgical excision and anti-fungal therapy; although there have been reports suggesting local hyperthermia as an effective treatment as well (Fukai *et al.*, 2013). Surgical excision is typically reserved for those patients who have solitary lesions. As our patient had multiple nodules, we decided systemic anti-fungal therapy was the best option for treatment. Voriconazole and itraconazole have had the best record for treatment; however, we demonstrate that posaconazole is effective as well. Although susceptibility was ordered, we did not obtain it before starting him on posaconazole. Since he had a favorable response to the therapy, he was continued on a 3-month course. If there had been evidence of disseminated infection, the plan was for combination therapy with both posaconazole and amphotericin B. To our knowledge, this is the first case of subcutaneous *E. oligosperma* infection that has been successfully treated with posaconazole.

Table 1. Summary of previously reported cases of skin infections due to *E. oligosperma*

Reference	Age	Gender	Relevant	Duration of History	Site	Presentation	Treatment
Bossler <i>et al.</i> (2003)	62	M	Wegener's granulomatosis	8 months	Left elbow	Painless swelling in left elbow	Intrabursal injection of amphotericin
Gonzalez-Lopez <i>et al.</i> (2007)	72	F	Renal transplantation	3 months	Right leg	Multiple subcutaneous nodules	Oral itraconazole
Tokuhisa <i>et al.</i> (2011)	57	F	None	1 year	Left cheek	Slightly pruritic, hyperkeratotic, erythematous lesion	Partial surgical excision and topical terbinafine cream
Kan <i>et al.</i> (2013)	71	F	Wegener's granulomatosis	1 year	Left forearm	Multiple erythematous subcutaneous nodules with pus discharge	Oral voriconazole → oral itraconazole surgical excision
Sato <i>et al.</i> (2013)	80	F	Takayasu's arteritis	2 months	Right cheek	Hyperkeratotic, red-brown papule	Thermotherapy, potassium iodide, surgical excision, oral itraconazole
Fukai <i>et al.</i> (2013)	58	F	Sjogren's syndrome	4 months	Left hand	Multiple subcutaneous nodules and abscesses	Oral itraconazole → local hyperthermia
Rimawi <i>et al.</i> (2013)	50	F	Systemic lupus erythematosus	3 months	Both legs	Reddish-pink, "rubbery-like" subcutaneous nodules	Oral voriconazole
Venkateshwar <i>et al.</i> (2014)	38	M	None		Right elbow	Non-tender, soft, mobile nodule	Surgical excision
This report	53	M	Renal Transplantation	3 months	Both arms	Multiple erythematous cutaneous nodules with central vesicles	Oral posaconazole

Author Contributions

EM, AL, SR, HR: Conceptualization. AL, SR, DS, KB, SC, DH, NW, HF, JL: Manuscript Writing. DS, NW, HF, JL: Mycology. AL, SR, DS, MB, NA, EM, HR: Manuscript Editing. SC: Pathology.

Acknowledgment

We would like to acknowledge both North Shore-LIJ Health System and the University of Texas Health Science Center at San Antonio for their collaboration both with successfully treating this patient, as well as writing this case report.

Ethics

Patient consent was obtained for this case report. As a result, we do not anticipate any ethical issues to arise after publication of this manuscript.

References

- Murray, P., K. Rosenthal and M. Pfaller, 2012. Opportunistic Mycoses: Phaeohyphomycosis. Murray: Medical Microbiology, 7th Edn., Elsevier Health Sciences, London, pp: 694-95.
- Schieffelin, J.S., J.B. Garcia-Diaz, G.E. Loss, E.N. Beckman and R.A. Keller *et al.*, 2014. Phaeohyphomycosis fungal infections in solid organ transplant recipients: Clinical presentation, pathology and treatment. *Transplant Infectious Disease*, 16: 270-278. DOI: 10.1111/tid.12197
- Pai, V.V., K.N. Naveen, K. Hanumanthayya and U.S. Dinesh, 2013. Subcutaneous Pheohyphomycosis presenting as a innocuous pustule. *Indian J. Dermatol.*, 58: 159-159. DOI: 10.4103/0019-5154.108083
- Romanelli, A.M., D.A. Sutton, E.H. Thompson, M.G. Rinaldi and B.L. Wickes, 2010. Sequence-based identification of filamentous basidiomycetous fungi from clinical specimens: A cautionary note. *J. Clinical Microbiol.*, 48: 741-752. DOI: 10.1128/JCM.01948-09
- White, T.J., T.D. Bruns, S.B. Lee and J.W. Taylor, 1990. Amplification and Direct Sequencing of Fungal Ribosomal RNA Genes for Phylogenetics. In: *PCR Protocols: A Guide to Methods and Applications*, Innis, M.A., D.H. Gelfand, J.J. Sninsky, T.J. White, (Edn.), Academic Press, Inc., New York; pp: 315-322.
- Heinrichs, G., G.S. De Hoog and G. Haase, 2012. Barcode identifiers as a practical tool for reliable species assignment of medically important black yeast species. *J. Clinical Microbiol.*, 50: 3023-3030. DOI: 10.1128/JCM.00574-12
- CLSI, 2008. Reference Method for Broth Dilution Antifungal Susceptibility Testing of Filamentous Fungi. Approved standard. 2nd Edn., Clinical and Laboratory Standards Institute, Wayne, Pennsylvania.
- De Hoog, G.S., V. Vicente, R.B. Caligiorme, S. Kantarcioglu and K. Tintelnot *et al.*, 2003. Species diversity and polymorphism in the *exophiala spinifera* clade containing opportunistic black yeast-like fungi. *J. Clinical Microbiol.*, 41: 4767-4778. DOI: 10.1128/JCM.41.10.4767-4778.2003
- Zeng, J.S., D.A. Sutton, A.W. Fothergill, M.G. Rinaldi and M.J. Harrak *et al.*, 2007. Spectrum of clinically relevant *Exophiala* species in the United States. *J. Clinical Microbiol.*, 45: 3713-20. DOI: 10.1128/JCM.02012-06
- UA, 2001. *Exophiala Jeanselmei*. The University of Adelaide.
- Venkateshwar, S., M.M. Ambroise, G.J. Asir, N. Mudhigeti and A. Ramdas *et al.*, 2014. A rare case report of subcutaneous phaeohyphomycotic cyst caused by *exophiala oligosperma* in an immunocompetent host with literature review. *Mycopathologia*, 178: 117-21. DOI: 10.1007/s11046-014-9762-4
- Rimawi, B., R.H. Rimawi, M. Mirdamadi, L.L. Steed and R. Marchell *et al.*, 2013. A case of *exophiala oligosperma* successfully treated with voriconazole. *Med. Mycol. Case Reports*, 2: 144-147. DOI: 10.1016/j.mmcr.2013.08.003
- Gonzalez-Lopez, M., R. Salesa, M.C. González-Vela, H. Fernández-Llaca and J.F. Val-Bernal *et al.*, 2007. Subcutaneous phaeohyphomycosis caused by *exophiala oligosperma* in a renal transplant recipient. *British J. Dermatol.*, 156: 762-4. DOI: 10.1111/j.1365-2133.2006.07732.x
- Bossler, A.D., S.S. Richter, A.J. Chavez, S.A. Vogelgesang and D.A. Sutton *et al.*, 2003. *Exophiala oligosperma* causing olecranon Bursitis. *J. Clinical Microbiol.*, 41: 4779-82. DOI: 10.1128/JCM.41.10.4779-4782.2003
- Tokuhiya, Y., Y. Hagiya, M. Hiruma and K. Nishimura, 2011. Phaeohyphomycosis of the face caused by *exophiala oligosperma*. *Mycoses*, 54: 240-243. DOI: 10.1111/j.1439-0507.2009.01845.x
- Kan, T., S. Takahagi, A. Kamegashira, H. Ooiwa and T. Yaguchi *et al.*, 2013. Disseminated subcutaneous phaeohyphomycosis caused by *exophiala oligosperma* in a patient with wegener's granulomatosis. *Acta dermato-venereologica*, 93: 356-357. DOI: 10.2340/00015555-1451
- Sato, T. and T. Yaguchi, 2013. A case of phaeohyphomycosis of the face caused by *exophiala oligosperma* in an immunocompromised host. *J. German Society Dermatol.*, 11: 1087-89. DOI: 10.1111/ddg.12158
- Fukai, T., M. Hiruma, Y. Ogawa, S. Ikeda and H. Ikeda *et al.*, 2013. A case of phaeohyphomycosis caused by *exophiala oligosperma* successfully treated with local hyperthermia. *Med. Mycol. J.*, 54: 297-301. DOI: 10.3314/mmj.54.297