

2014

Papillary adenocarcinoma in situ of the skin: report of four cases

S. Chen

Hofstra Northwell School of Medicine

M. Asgari

Northwell Health

Follow this and additional works at: <https://academicworks.medicine.hofstra.edu/publications>



Part of the [Dermatology Commons](#), and the [Pathology Commons](#)

Recommended Citation

Chen S, Asgari M. Papillary adenocarcinoma in situ of the skin: report of four cases. . 2014 Jan 01; 4(2):Article 375 [p.]. Available from: <https://academicworks.medicine.hofstra.edu/publications/375>. Free full text article.

This Article is brought to you for free and open access by Donald and Barbara Zucker School of Medicine Academic Works. It has been accepted for inclusion in Journal Articles by an authorized administrator of Donald and Barbara Zucker School of Medicine Academic Works. For more information, please contact academicworks@hofstra.edu.

Papillary adenocarcinoma in situ of the skin: report of four cases

Sheng Chen¹, Masoud Asgari²

¹ Department of Pathology and Laboratory Medicine and Department of Dermatology, Hofstra North Shore-LIJ School of Medicine, NY, USA

² Department of Pathology and Laboratory Medicine, Staten Island University Hospital, NY, USA

Keywords: papillary eccrine adenoma; adenocarcinoma in situ; aggressive digital papillary adenocarcinoma; eccrine gland; apocrine gland

Citation: Chen S, Asgari M. Papillary adenocarcinoma in situ of the skin: report of four cases. *Dermatol Pract Concept*. 2014;4(2):4. <http://dx.doi.org/10.5826/dpc.0402a04>

Received: September 26, 2013; **Accepted:** January 7, 2013; **Published:** April 30, 2014

Copyright: ©2014 Chen et al. This is an open-access article distributed under the terms of the Creative Commons Attribution License, which permits unrestricted use, distribution, and reproduction in any medium, provided the original author and source are credited.

Funding: None.

Competing interests: The authors have no conflicts of interest to disclose.

All authors have contributed significantly to this publication.

Corresponding author: Sheng Chen, M.D., Ph.D., Department of Pathology and Laboratory Medicine, Hofstra North Shore-LIJ School of Medicine, 6 Ohio Drive, Suite 202, Lake Success, NY 11042, USA. Tel. 516.304.7284; Fax. 516.304.7270. Email. schen@nshs.edu

ABSTRACT Although rare isolated cases of adenocarcinoma in situ of skin have been reported in the literature, adenocarcinoma in situ of skin as a concept and as a diagnostic category has not been established in the field of dermatopathology. In this work, four cases of papillary adenocarcinoma in situ of the skin are presented. In addition, the notion that lesions previously reported in the medical literature under the term of “papillary eccrine adenoma” are actually adenocarcinoma in situ is discussed.

Introduction

In general, epithelial neoplasm can be classified into three categories, namely, benign neoplasm, carcinoma in situ (non-invasive carcinoma) and invasive carcinoma. When the term carcinoma used unmodified, it generally refers to invasive carcinoma. However, since the introduction of the concept of carcinoma in situ by Broder in 1932 [1], there have been only occasional case reports of adenocarcinoma in situ of skin in the literature [2-6]. Adenocarcinoma in situ of skin as a concept and as a diagnostic category has not been established in the field of dermatopathology [7-9]. In this essay, four cases of papillary adenocarcinoma in situ (PACIS) of skin are reported. Furthermore, the notion that lesions previously reported in the medical literature under the term of papillary eccrine adenoma are actually PACIS is discussed.

Materials and methods

Case history

Case 1

The patient was a 82-year-old female with a 1.2 cm painful mass in her right second toe. The lesion was excised and diagnosed by a dermatopathologist as sweat duct carcinoma, involving the specimen margins. Subsequently, amputation of the right second toe was performed. Upon review of the amputation specimen along with the prior excision specimen, another dermatopathologist in a different institution interpreted the lesion as papillary eccrine adenoma.

Case 2

The patient was a 47-year-old female with a 1.5 cm skin nodule on her right leg. The lesion was excised and was reported to be adenocarcinoma with negative margins.

TABLE 1. Clinical summary of the four cases

Case	Age	Sex	Lesion location	Lesion size
1	82	Female	Right 2nd toe	1.2 cm
2	47	Female	Right leg	1.5 cm
3	43	Male	Right index finger	1.4 cm
4	68	Female	Right leg	1.8 cm

Case 3

The patient was a 43-year-old male, who presented with a 1.4 cm lesion on his right index finger. The lesion was excised and reported as papillary eccrine carcinoma in situ. Subsequently the patient requested a second opinion from two dermatopathologists from two separate institutions, who both interpreted the lesion as aggressive digital papillary adenocarcinoma.

Case 4

The patient was a 68-year-old female with 1.8 cm nodule in her right leg. The nodule was excised and interpreted as eccrine carcinoma in situ extending to surgical margin. Re-excision was performed and showed focal residual tumor with negative surgical margin. One month earlier, the patient had right breast mastectomy with sentinel lymph node biopsy, which showed the presence of a 3.0 cm low-grade invasive ductal carcinoma with mucinous features in the breast. Four sentinel lymph nodes were negative for tumor. Two years later, the patient had radical right hemicolectomy for a 10.5 cm moderately to poorly differentiated adenocarcinoma of the cecum with 5/17 positive lymph nodes and liver metastasis.

The clinical summaries of the four cases are listed in Table 1.

Results

Histopathologic and immunocytochemical features: By light microscopy, the tumors in all our cases consisted of circumscribed but not encapsulated intradermal proliferations of variously-sized tubules and ducts embedded in a sclerotic stroma (Figures 1 and 2). Many of them were lined by a double layer of cells. The outer layer composed of flattened myoepithelial cells. The inner cells were cuboidal to columnar and formed in most lumens papillary projections. Squamous metaplasia was also noted in one case. Cytologically, the cells showed mild to moderate nuclear atypia. Mitotic figures and single cell necrosis were noted. An intact myoepithelial layer was evident on H&E-stained sections of all four cases and this was further confirmed by immunohistochemistry for P63, which was performed on two cases (Cases 2 and 3), and revealed strong positive reaction in outer layer (Figure 3A). Ki-67 staining was performed on one case (Case 3) and was positive in at least 30% of neoplastic cells (Figure 3B). Various diagnoses ranging from papillary eccrine adenoma, carcinoma in situ, and carcinoma were rendered by different pathologists or dermatopathologists (Table 2).

Discussion

Since the introduction of the concept of carcinoma in situ in 1932 [1], although rare cases of adenocarcinoma in situ of the skin have been reported [2-6], adenocarcinoma in situ of the skin as a concept and as a diagnostic category has not been

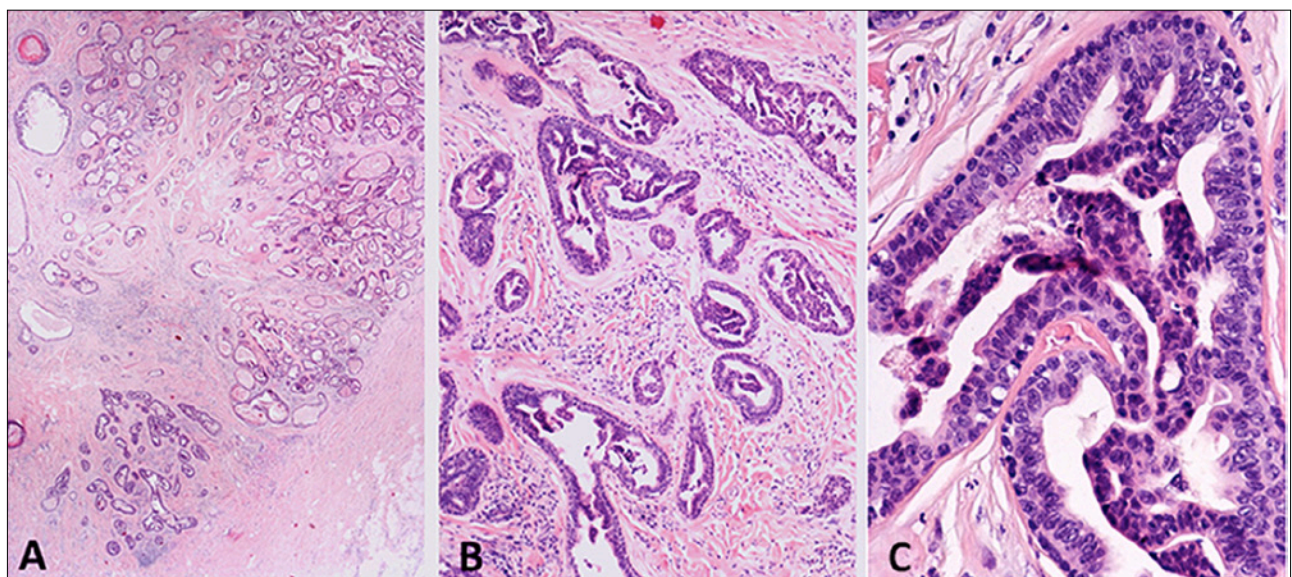


Figure 1. Case 2, papillary adenocarcinoma in situ. (A) Low power view showing a circumscribed lesion located in a fibrotic dermis (H&E, x20); (B) Medium power view showing dilated ducts with prominent papillary projections (H&E, x100); (C) High power view showing clearly the presence of intact myoepithelial cell layer (H&E, x400). [Copyright: ©2014 Chen et al.]

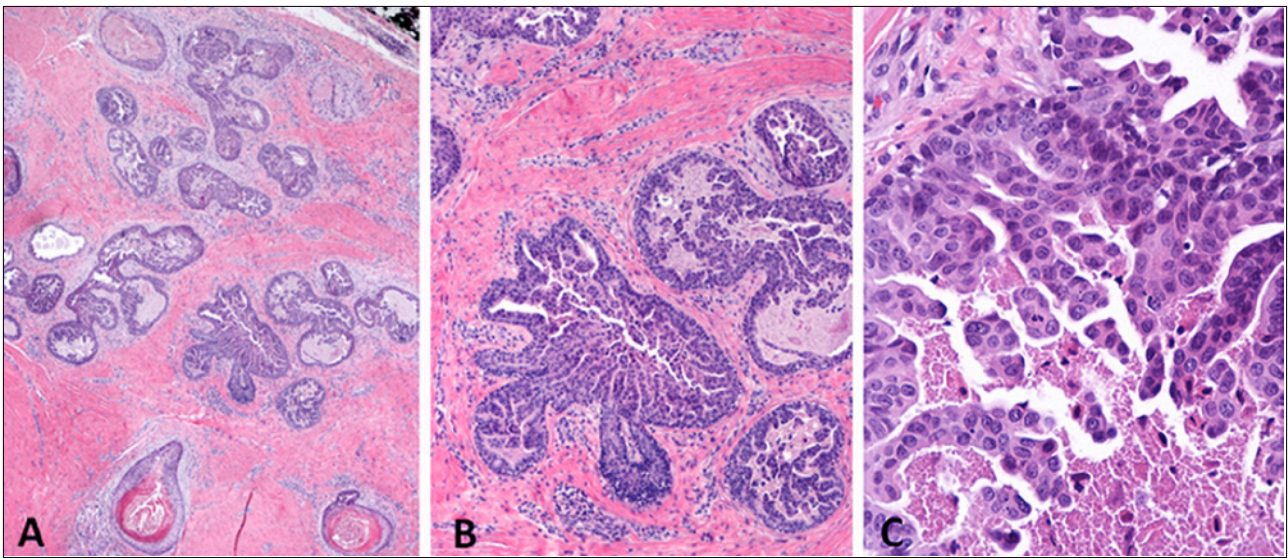


Figure 2. Case 3, papillary adenocarcinoma in situ. (A) Low power view showing a lesion in a fibrotic dermis (H&E, x40); (B) Medium power view showing prominent papillary structure formation (H&E, x 200); (C) High power view showing the presence of necrosis and peripheral myoepithelial cell layer (H&E, x400). [Copyright: ©2014 Chen et al.]

established [7-9]. Conceptually cases of adenocarcinoma in situ of skin must exist. The four cases presented here, in our opinion, are such examples. These lesions show cytological

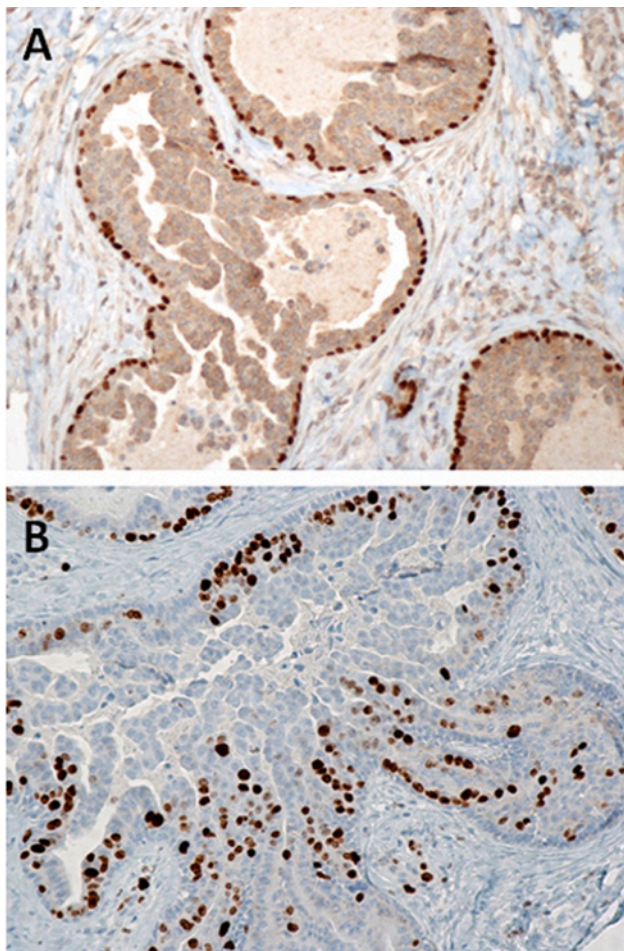


Figure 3. Case 3, papillary adenocarcinoma in situ. Immunocytochemical stain for P63 (A, x400) and Ki67 (B, x400). P63 stain highlights the intact layer of myoepithelial cells. At least 30% of neoplastic cells are positive for Ki67. [Copyright: ©2014 Chen et al.]

malignancy (nuclear atypia, single cell necrosis and mitotic figures) with intact myoepithelial cell layer (no evidence of invasion), fulfilling the criteria for carcinoma in situ set forth by Broder in 1932 [1]. If one employs the diagnostic criteria of breast pathology, these lesions are morphologically identical to the micropapillary type of ductal carcinoma in situ in the breast [10]. Although these cases were variably interpreted as invasive adenocarcinoma, they are obviously not invasive adenocarcinoma because of the presence of an intact myoepithelial cell layer. The main reason they were interpreted as invasive adenocarcinoma is that cutaneous adenocarcinoma in situ has not been established as a diagnostic category or entity. When pathologists encounter these kinds of lesions, they would classify them either as adenoma or invasive adenocarcinoma.

In 1973, Panet-Raymond and Johnson described a very similar lesion under the term of adenocarcinoma of the eccrine sweat gland [11]. They reported a case of a 49-year-old man who had a slow growing tumor on his left forearm since childhood. The tumor rapidly began to grow and for this reason it was excised. The histopathologic features were deemed by the authors to be adenocarcinoma of the sweat gland. However, based on what the authors described and illustrated microscopically in their article, the lesion is identical to the cases presented here. They called it carcinoma “on the basis of non-encapsulation, areas of intracystic papillary projections, and the presence of hyperchromatic nuclei, a moderate number of mitoses and some atypical cells in these latter areas.”

We believe that lesions reported under the term papillary eccrine adenoma are not adenoma but PACIS. In 1977, Rulon and Helwig described an identical lesion but named it for the first time “papillary eccrine adenoma” [12]. They reported on 14 cases of distinctive cutaneous glandular

TABLE 2. Diagnoses offered by different pathology/dermatopathology consultants

Case	1st opinion	2nd opinion	3rd opinion
1	Sweat duct carcinoma (by dermatopathologist)	Papillary eccrine adenoma (by dermatopathologist)	Not applicable
2	Adenocarcinoma (by pathologist)	Not applicable	Not applicable
3	Papillary eccrine carcinoma in situ (by dermatopathologist)	Aggressive digital papillary adenocarcinoma (by dermatopathologist)	Aggressive digital papillary adenocarcinoma (by dermatopathologist)
4	Eccrine carcinoma in situ (by dermatopathologist)	Not applicable	Not applicable

neoplasm, which they stated, “were difficult to interpret and had been believed to occupy the gray zone separating benign and malignant neoplasms of the sweat glands. Since none was found to have metastasized, this lesion is provisionally considered benign. The diagnostic term of papillary eccrine adenoma is suggested.” The lesions varied in size from 0.5 to 2.0 cm and could be found in any part of the skin including fingers and toes. Histologically the lesions they described are very similar, if not identical, to the four cases described here in the present study. Regarding treatment and nature of the lesions, Rulon and Helwig stated “surgical excision with assurance of complete removal by histologic examination of the surgical margins is considered the treatment of choice. The lesion is considered benign on the basis of available follow-up information.” As one can see, Rulon and Helwig considered the lesions benign, namely, papillary eccrine adenoma, based on no recurrence or metastases following complete surgical excision or digital amputation. However, this does not argue against the notion that the lesions were actually adenocarcinoma in situ, since carcinoma in situ would behave exactly the same way, namely, no recurrence or metastases following complete surgical excision.

Subsequent studies using the term papillary eccrine adenoma have been published by different authors, but the majority of them are single case reports or a small series of cases [13-30]. Very few authors questioned the true nature of the lesion under discussion and most simply followed Rulon and Helwig and considered their own cases as adenomas.

In 1987, Urmacher and Lieberman reported four cases using the term of papillary eccrine adenoma [31]. They did mention that three patients were seen prior to 1977 and diagnosed with sweat gland carcinoma. Because the histology in all four cases was similar to what Rulon and Helwig described as papillary eccrine adenoma in 1977, they reassessed the diagnosis and described them with the term papillary eccrine adenoma. Aloï and Pich admitted difficulty in differentiating between papillary eccrine adenoma and low-grade sweat gland carcinoma [32].

In all the above examples, we think the confusion was due to unawareness of adenocarcinoma in situ as a concept and as one diagnostic category in the skin.

In 2003, Denianke and Ackerman published an article and claimed that the so-called papillary eccrine adenoma is really apocrine papillary carcinoma [33]. Although we agree with Denianke and Ackerman that the so-called papillary eccrine adenoma is not adenoma, namely, a benign glandular neoplasm, we believe for the reasons stated above that the lesion under discussion is best categorized as PACIS, not carcinoma, which when used unmodified generally means invasive carcinoma.

Of note, our Case 3 was interpreted as aggressive digital papillary adenocarcinoma by two dermatopathologists from two independent institutions. This is not surprising, since to our knowledge at least two similar cases, which were reported as aggressive digital papillary adenocarcinoma in the literature, are actually adenocarcinoma in situ in our opinion. One case appeared in an article published in 2006 by Crowson et al [34]. The authors illustrated a case (figures 15 and 16 in the article) under the term digital papillary adenocarcinoma and commented that histopathologically the lesion was “cognate to that of ductal carcinoma in situ of the breast.” From the photomicrographs illustrated there, it appears that an intact peripheral myoepithelial cell layer was present, so we believe the case is actually adenocarcinoma in situ rather than digital papillary adenocarcinoma. The other case was presented in an article in 2010 by Hsu et al [35]. The authors described an 8 mm nodule on the finger of a 28-year-old woman diagnosed as aggressive digital papillary adenocarcinoma. According to the authors, the lesion was excised with a positive margin, and there was no evidence of disease progression at the six-year follow-up. The photomicrographs of H&E and P63 stain provided by the authors for their case (figures 2 and 3 in the article) showed clearly the presence of an intact myoepithelial cell layer. This led us (M.A. and S.C.) to conclude that the lesion actually represented so-called papillary eccrine adenoma (PACIS in

our current opinion, see above) misinterpreted as aggressive digital papillary adenocarcinoma [36].

Of interest, in a recent book published in 2012 titled *Cutaneous Adnexal Tumors* by Kazakov et al., in the pages regarding digital papillary adenocarcinoma the existence of adenocarcinoma in situ is mentioned briefly in these words: “In several cases, the authors have noticed that a constant feature is the presence of a recognizable myoepithelial cell layer around the glands and sometimes at the peripheral of the cystic-papillary areas. Invasion into the stroma is sometimes seen and no myoepithelial cells are present in the invasive foci. On the contrary, the authors have encountered a case in which the whole lesion was endowed with a peripheral myoepithelial cell layer consistent with the concept of carcinoma in situ” [37]. In our opinion, this is probably the first time adenocarcinoma in situ was ever mentioned in the acral location.

Is PACIS eccrine or apocrine origin? Rulon and Helwig thought it of eccrine origin [12], while Denianke and Ackerman of apocrine origin [33]. Other authors pointed out a bimodal differentiation, to wit, originating from both apocrine and eccrine (apoeccrine) origin [38]. We believe that PACIS can derive from eccrine as well as apocrine glands. Currently there are no reliable histological or immunocytochemical features that can distinguish it for sure. For practical purposes, there is really no need to distinguish them. It does not matter clinically whether it is of eccrine or apocrine origin. It should be treated the same way, namely, simple complete but conservative excision. Thus, we would suggest using the term PACIS without using either of the modifiers eccrine or apocrine.

References

1. Broders AC. Carcinoma in situ contrasted with benign penetrating epithelium. *JAMA*. 1932;99(20):1670-4.
2. Castro CY, Deavers M. Ductal carcinoma in-situ arising in mammary-like glands of the vulva. *Int J Pathol*. 2001;20:277-83.
3. Castelli E, Wollina U, Anzarone A, et al. Extramammary Paget disease of the axilla associated with comedo-like apocrine carcinoma in situ. *Am J Dermatopathol*. 2002;24:351-7.
4. Obaidat NA, Awamleh AA, Ghazarian DM. Adenocarcinoma in situ arising in a tubulopapillary apocrine hidradenoma of the peri-anal region. *Eur J Dermatol*. 2006;16:576-8.
5. Shah SS, Adelson M, Mazur MT. Adenocarcinoma in situ arising in vulvar papillary hidradenoma: report of 2 cases. *Int J Gynecol Pathol*. 2008;27:453-6.
6. Weinreb I, Bergfeld WF, Patel RM, Ghazarian DM. Apocrine carcinoma in situ of sweat duct origin. *Am J Surg Pathol*. 2009;33:155-7.
7. LeBoit PE, Burg G, Weedon D, et al. *Pathology and Genetics of Skin Tumours (IARC WHO Classification of Tumours)*. Lyon: IARC Press, 2006.
8. Weedon D. *Skin Pathology*. 8th ed. New York: Elsevier, 2010.
9. Elder D, Elenitsas R, Johnson Jr BL, et al. *Lever's Histopathology of the Skin*. 9th ed. Philadelphia: Lippincott Williams & Wilkins, 2005.
10. Rosen PP. *Rosen's Breast Pathology*. 3rd ed. Philadelphia: Lippincott Williams & Wilkins, 2009.
11. Panet-Raymond G, Johnson WC. Adenocarcinoma of the eccrine sweat gland. *Arch Dermatol*. 1973;107:94-6.
12. Rulon DB, Helwig EB. Papillary eccrine adenoma. *Arch Dermatol*. 1977;113:596-8.
13. Elpern DJ, Farmer ER. Papillary eccrine adenoma. *Arch Dermatol*. 1978;114:1241.
14. Sina B, Dilaimy M, Kallayee D. Papillary eccrine adenoma. *Arch Dermatol*. 1980;116:719-20.
15. White SW, Rodman OG. Papillary eccrine adenoma. *Natl Med Assoc*. 1982;74:573-6.
16. Cooper PH, Frierson HF. Papillary eccrine adenoma. *Arch Pathol Lab Med*. 1984;108:55-7.
17. Falck VG, Jordaan HF. Papillary eccrine adenoma. A tubulopapillary hidradenoma with eccrine differentiation. *Am J Dermatopathol*. 1986;8:64-72.
18. Kanitakis J, Hermier C, Thivolet J. Papillary eccrine adenoma. *Am J Dermatopathol*. 1988;10:180-2.
19. Sexton M, Maize JC. Papillary eccrine adenoma. A light microscopic and immunohistochemical study. *J Am Acad Dermatol*. 1988;18:1114-20.
20. Tellechea O, Truchetet F, Grosshans E. Papillary eccrine adenoma [Portuguese]. *Med Cutan Ibero Lat Am*. 1989;17:85-91.
21. Jerasutus S, Suvanprakorn P, Wongchinchai M. Papillary eccrine adenoma: an electron microscopic study. *J Am Acad Dermatol*. 1989;20:1111-4.
22. Hashimoto K, Kato I, Taniguchi Y, et al. Papillary eccrine adenoma. Immunohistochemical and ultrastructural analyses. *J Dermatol Sci*. 1990;1:65-71.
23. Requena L, Peña M, Sánchez M, Sánchez Yus E. Papillary eccrine adenoma—a light-microscopic and immunohistochemical study. *Clin Exp Dermatol*. 1990;15:425-8.
24. Megahed M, Hölzle E. Papillary eccrine adenoma. A case report with immunohistochemical examination. *Am J Dermatopathol*. 1993;15:150-5.
25. Biernat W, Kordek R, Woźniak L. Papillary eccrine adenoma—a case of cutaneous sweat gland tumor with secretory and ductular differentiation. *Pol J Pathol*. 1994;45:319-22.
26. Mizuoka H, Senzaki H, Shikata N, Uemura Y, Tsubura A. Papillary eccrine adenoma: immunohistochemical study and literature review. *J Cutan Pathol*. 1998;25:59-64.
27. Guccion JG, Patterson RH, Nayar R, Saini NB. Papillary eccrine adenoma: an ultrastructural and immunohistochemical study. *Ultrastruct Pathol*. 1998;22:263-9.
28. Kurtz DH, Finnell JA, Mehler AS. Papillary eccrine adenoma of the heel: a case report. *J Foot Ankle Surg*. 2000;39:249-52.
29. Blasini W, Hu S, Gugic D, Vincek V. Papillary eccrine adenoma in association with cutaneous horn. *Am J Clin Dermatol*. 2007;8:179-82.
30. Laxmisha C, Thappa DM, Jayanthi S. Papillary eccrine adenoma. *Indian J Dermatol Venereol Leprol*. 2004;70:370-2.
31. Urmacher C, Lieberman PH. Papillary eccrine adenoma. Light-microscopic, histochemical, and immunohistochemical studies. *Am J Dermatopathol*. 1987;9:243-9.
32. Aloï F, Pich A. Papillary eccrine adenoma. A histopathological and immunohistochemical study. *Dermatologica*. 1991;182:47-51.

33. Denianke K, Ackerman AB, The issue of eccrine versus apocrine differentiation of cutaneous neoplasms affiliated with tubules, *Dermatopathology: Practical & Conceptual*. 2003;9(4).
34. Crowson AN, Magro CM, Mihm MC. Malignant adnexal neoplasms. *Mod Pathol*. 2006; Suppl 2:S93-126.
35. Hsu HC, Ho CY, Chen CH, et al. Aggressive digital papillary adenocarcinoma: a review. *Clin Exp Dermatol*. 2010;35:113-9.
36. Asgari M, Chen S. Papillary eccrine adenoma should not be mistaken for aggressive digital papillary adenocarcinoma. *Clin Exp Dermatol*. 2014;39:223-4.
37. Kazakov DV, Michal M, Kacerovska D, et al. *Cutaneous Adnexal Tumors*. Philadelphia: Lippincott Williams & Wilkins, 2012: 95-99.
38. Fox SB, Cotton DW. Tubular apocrine adenoma and papillary eccrine adenoma. Entities or unity? *Am J Dermatopathol*. 1992;14:149-54.