

2015

Single-Portal Arthroscopy of the Central Compartment of the Hip

S. Mannava

E. A. Howse
Northwell Health

T. J. Kelsey

R. H. Barnes

A. Antunes

See next page for additional authors

Follow this and additional works at: <https://academicworks.medicine.hofstra.edu/publications>



Part of the [Emergency Medicine Commons](#)

Recommended Citation

Mannava S, Howse E, Kelsey T, Barnes R, Antunes A, Stubbs A. Single-Portal Arthroscopy of the Central Compartment of the Hip. . 2015 Jan 01; 4(3):Article 435 [p.]. Available from: <https://academicworks.medicine.hofstra.edu/publications/435>. Free full text article.

This Article is brought to you for free and open access by Donald and Barbara Zucker School of Medicine Academic Works. It has been accepted for inclusion in Journal Articles by an authorized administrator of Donald and Barbara Zucker School of Medicine Academic Works. For more information, please contact academicworks@hofstra.edu.

Authors

S. Mannava, E. A. Howse, T. J. Kelsey, R. H. Barnes, A. Antunes, and A. J. Stubbs

Single-Portal Arthroscopy of the Central Compartment of the Hip



Sandeep Mannava, M.D., Ph.D., Elizabeth A. Howse, M.D., Thomas J. Kelsey, B.S.,
Ryan H. Barnes, B.S., Andre Antunes, and Allston J. Stubbs, M.D., M.B.A.

Abstract: Since hip arthroscopy has become a standard of orthopaedic practice, the indications have continued to expand as it has proved to be a helpful diagnostic, as well as therapeutic, tool. Access to the hip joint, however, remains challenging for the orthopaedic surgeon who does not routinely perform hip arthroscopy. We present a single-portal arthroscopic technique, showing the feasibility of single-portal arthroscopic access to the hip joint, as well as describing basic indications and instrumentation for single-portal hip arthroscopy. Single-portal hip arthroscopy is ideal for the patient who needs to undergo diagnostic hip arthroscopy or for treatment in patients with simple hip pathology (e.g., removal of loose bodies or debridement).

Arthroscopic hip procedures are appealing to both patients and surgeons because they offer minimally invasive access to the deep hip joint, which may result in faster recovery and rehabilitation.¹ As arthroscopic techniques have been refined, hip arthroscopy indications have expanded to include the ability to address labral tears, synovial chondromatosis, osteochondritis dissecans, septic arthritis, femoroacetabular impingement, ischiofemoral impingement, removal of loose bodies, ligamentum teres injuries, snapping hip syndrome, and other hip pathologies.²⁻⁶ Hip arthroscopy is regarded as being uniquely technically

challenging compared with arthroscopy of other joints, likely related to the deep and encapsulated nature of the hip joint.^{6,7} There is a known “learning curve” phenomenon related to performing hip arthroscopy,⁸ and some of the complications reported in the literature are iatrogenic injuries.^{6,9}

With advancements in optical engineering, such as high-definition digital imaging and fluid pumps, arthroscopic visualization has greatly improved. Yet, the general technique of intra-articular triangulation and the 2- to 3-portal technique have largely remained constant throughout the evolution of arthroscopic surgery.¹⁰⁻¹² Recently, single-portal arthroscopic (SPA) surgical techniques have been described for knee¹⁰ and shoulder surgery.¹³ This report reviews a surgical technique that allows for single-portal hip arthroscopic surgery; this technique may further advance the minimally invasive nature of hip arthroscopy and, in theory, minimize the risk of iatrogenic injury with multiple-portal intervention.

Surgical Technique

The SPA hip technique is performed using a parallel-portal system (Stryker Endoscopy, San Jose, CA), which is a system of instrumentation that facilitates fluid flow, visualization, and surgical instrumentation passage through a single incision; this allows the surgeon to work in parallel, in contrast to traditional triangulation techniques (Figs 1 and 2). The surgical hip arthroscopic technique through a single portal is demonstrated in Video 1 and Figure 2. A detailed description of the SPA

From the Department of Orthopaedic Surgery, Division of Sports Medicine, Wake Forest University School of Medicine (S.M., T.J.K., A.J.S.), Winston-Salem, North Carolina; Department of Emergency Medicine, Long Island Jewish Medical Center (E.A.H.), New Hyde Park, New York; Eastern Virginia Medical School (R.H.B.), Norfolk, Virginia; and Wake Forest University (A.A.), Winston-Salem, North Carolina, U.S.A.

The authors report the following potential conflict of interest or source of funding: S.M. receives support from Wake Forest Innovations Spark Award for development of rotator cuff repair device; and Orthopaedic Research and Education Foundation Resident Clinician Scientist Award. S.M. has a Utility Patent Application filed November 9, 2010 (No. 12/942,311) in US Patent and Trademark Office. A.J.S. receives support from Smith & Nephew Endoscopy, Bauerfeind, and Johnson & Johnson.

Received December 18, 2014; accepted February 18, 2015.

Address correspondence to Allston J. Stubbs, M.D., M.B.A., Division of Sports Medicine, Wake Forest University School of Medicine, Medical Center Boulevard, Winston-Salem, NC 27157, U.S.A. E-mail: astubbs@wakehealth.edu

© 2015 by the Arthroscopy Association of North America

2212-6287/141064/\$36.00

<http://dx.doi.org/10.1016/j.eats.2015.02.011>

instrumentation has been previously published by Cooper and Fouts.¹⁰ For hip arthroscopy purposes, the SPA parallel-portal cannulas are available in 50-mm and 25-mm sizes (Fig 1); in addition, there is a 0-mm coupler. The parallel arthroscope is 20 cm long, with a diameter of 2.9 mm and a viewing angle of 30°. The basis of the SPA instrumentation is the parallel-portal cannula, which has a locking lever and a working channel that couples the arthroscope to the instrumentation, allowing the surgeon to work through a single incision with the instruments in parallel during surgical movements (Figs 1 and 2). Some of the instruments have a 30° bend in the midshaft that allows for adequate movement in the system.

The patient is positioned in the modified supine position with adequate, fluoroscopically verified traction placed across the hip joint by use of a fracture table (OrthoVision; Steris, Mentor, OH). The hip is then prepared and draped in standard fashion. Key bony landmarks are identified, including the anterior superior iliac spine and the greater trochanter (Fig 3). The anterolateral portal as described by Byrd and Chern¹⁴ is our preferred camera and working portal for SPA access to the central compartment of the hip joint. When needed for additional visualization, a 17-gauge spinal needle is placed in the modified anterolateral portal to act as a fluid outflow tract (Fig 3).¹⁵

By use of the Seldinger technique, the anterolateral portal, 10 mm anterior and 10 mm superior to the margin of the greater trochanter, is established. The skin is incised, and a 17-gauge spinal needle is directed

into the hip joint, 15° cephalad and posterior to the horizon. Fluoroscopic guidance may be helpful in portal establishment. Once inserted into the joint, the stylet of the spinal needle is withdrawn and 60 mL of fluid is injected into the joint. Proper localization inside the joint will result in backflow into the syringe when pressure is relieved on the plunger during injection. The syringe is then removed from the needle, and a nitinol wire is inserted through the needle into the joint. The spinal needle is then removed from the wire. The portal is established with serial dilation, starting with a 4.5-mm cannula on an obturator along the nitinol wire, followed by 5.0-mm and 5.5-mm hip cannulas. The 5.5-mm cannula is then exchanged over a switching stitch with an arthroscopic cannula that has a stopcock inflow.

The arthroscope cannula is inserted into the parallel-portal device, and the coupled SPA system is inserted into the anterolateral portal.¹⁴ With the parallel-portal cannula in place, the 30°, 2.9-mm-diameter arthroscopic camera can be inserted and diagnostic hip arthroscopy is then performed. If additional flow is needed to aid in fluid exchange and visualization, a spinal needle can be placed under direct visualization through the modified anterolateral portal location.¹⁵ The arthroscope cannula is then placed through the 0-mm SPA parallel-portal coupler, and the coupler is positioned next to the inflow cannula. Next, in parallel fashion, an SPA probe, radiofrequency ablation device, grasper, or shaver can be introduced for performing hip arthroscopy. Several examples of hip pathology and their treatment using SPA instrumentation are demonstrated in Video 1 and are listed in Table 1. Technical tricks, clinical pearls, and potential pitfalls of the SPA hip technique are listed in Table 2.

Using the parallel-portal system, the surgeon moves both camera and instrument in concert. Unlike 2- to 3-portal hip arthroscopy, the coordination of movement is essential for simultaneous visibility and surgical intervention. The capsular footprint area of the single-portal system comprising the 2.9-mm arthroscope and parallel instrumentation is approximately 6 to 8 mm.

Discussion

Hip arthroscopy and minimally invasive methods for the treatment of hip pathology continue to gain popularity.^{11,16} In part, there is increasing recognition of various prearthritic hip conditions based on physical examination findings and advanced imaging modalities. Recent advancements in hip arthroscopy have led to these conditions being more readily addressed surgically.^{5,16-18} Performing hip arthroscopy can be technically demanding, likely because of anatomic considerations, including the deep and encapsulated nature of the joint.^{5,12,19} The limited space of the hip joint—despite distraction with traction—contributes, in

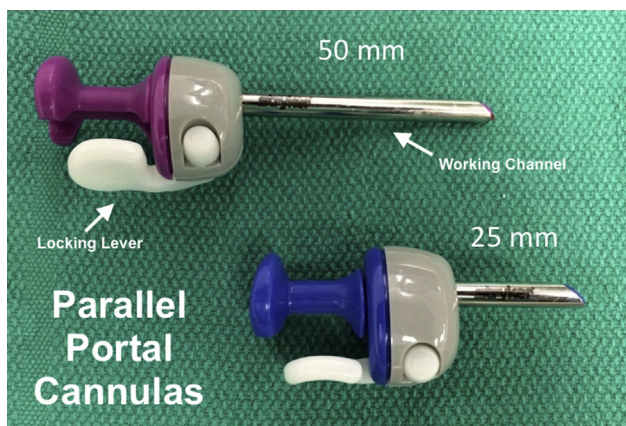


Fig 1. Single-portal arthroscopic (SPA) cannula system. The key features of the SPA cannula system, which allows for coupling of the arthroscope and surgical instruments, are depicted, including the locking lever and working channel; these features allow for parallel and coupled motion during surgery. Both 50-mm and 25-mm SPA cannula systems are shown. The coupling device allows for the camera to be locked into the cannula while providing a guided path for instrumentation, such as a probe or shaver, to be placed parallel to the arthroscope to perform the operation.

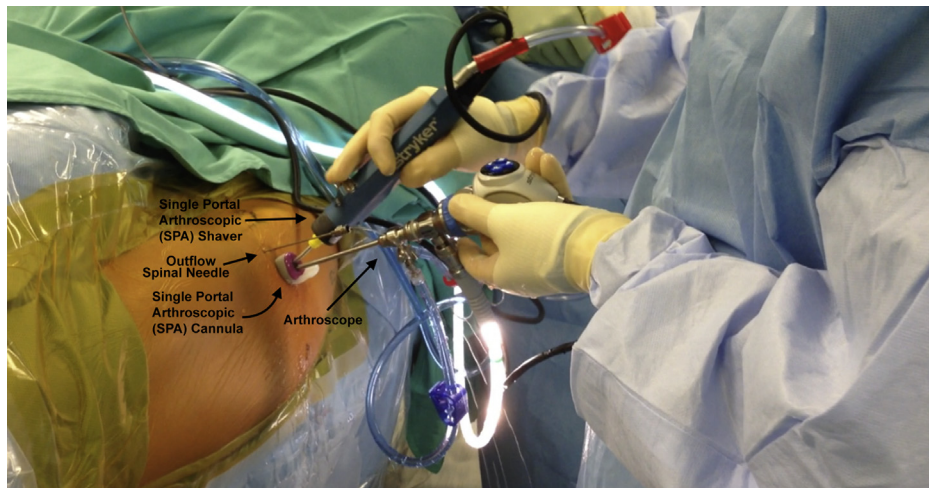


Fig 2. External view of the single-portal arthroscopic (SPA) system in a right hip, showing the cannula coupling the arthroscope and arthroscopic shaver. Single-portal hip arthroscopy is being performed through the standard anterolateral portal with the patient in the supine position. The modified anterior portal is the location of the 17-gauge spinal needle outflow tract to aid in visualization. This clinical photograph shows the arthroscope engaged in the SPA cannula, with the offset SPA shaver also in the cannula system, in a parallel manner. By use of the SPA cannula system, hip arthroscopy can be performed with the hands in a parallel orientation and the surgeon does not have to rely on triangulation for visualization. Our experience with the SPA hip technique has shown that the use of a separate spinal needle to provide outflow and fluid exchange improves visualization.

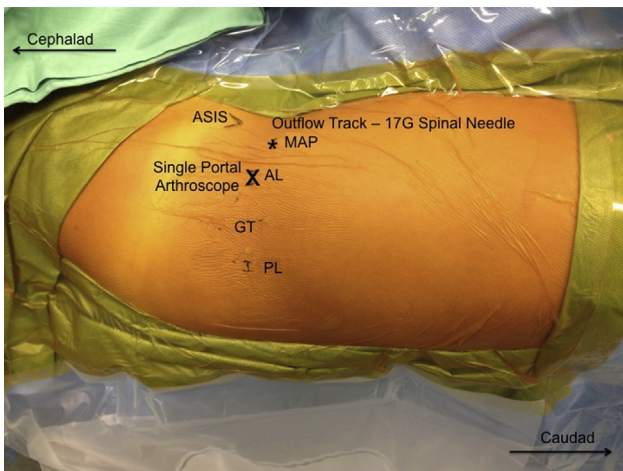


Fig 3. External anatomy showing portal placement during arthroscopic right hip surgery. The anatomic locations of the hip arthroscopy portals are shown, including the anterolateral portal (AL; marked with an X)—our preferred location for the single-portal arthroscope—and the modified anterior portal (MAP; marked with an asterisk), with potential placement of a 17-gauge spinal needle outflow tract. The patient is positioned in the supine position. The cephalad and caudad positions are labeled with arrows to help with orientation. For access to the central compartment of the hip, the standard anterolateral portal position is used, but our experience has shown that an outflow tract using a spinal needle placed through the modified anterior portal location is helpful for surgical visualization during single-portal arthroscopy. (ASIS, anterior inferior iliac spine; GT, greater trochanter; PL, posterolateral portal.)

part, to some of the complications associated with hip arthroscopy. Iatrogenic injury can be caused while establishing the arthroscopic portals and while navigating the joint through intra-articular triangulation because of the limited space of the hip joint.^{6,7} Becoming comfortable with hip arthroscopic techniques does take time and experience, and the amount of time, as well as the number of procedures, required to become comfortable performing these procedures is still debatable, but some recent data have shown that a distinct learning curve is associated with these procedures.⁸

Even though hip arthroscopy has become more popularized with specific instrumentation developed for the purposes of performing these operations, the general arthroscopic technology remains somewhat rudimentary. The basic equipment and surgical techniques of arthroscopy remain largely unchanged and based on principles established decades earlier. Arthroscopy is based on a minimum of 2 working portals, one for viewing and the other for instrumentation. Fluid management is coordinated through these 2 portals or more portals; this basic tenet of arthroscopic surgical technique facilitates both visualization and intervention based on intra-articular triangulation.¹⁰ This article describes an adaptation of single-portal knee arthroscopy instrumentation¹⁰ for the purposes of performing basic hip arthroscopy. The SPA instrumentation is based on a publication by O'Connor,²⁰ who reported passing instrumentation through the

Table 1. Indications for Single-Portal Arthroscopy of Hip

Procedure	CPT Code
Diagnostic arthroscopy	29860
Biopsy	29860
Loose body removal (<3 mm)	29861
Chondroplasty	29862
Labral debridement	29862
Hip arthroscopy with synovectomy	29863
Ligamentum teres debridement	29999

CPT, Current Procedural Terminology.

arthroscopic portal in 1977; this technology was called an “operating arthroscope.”¹⁰

The current article highlights a surgical technique for establishing the feasibility of single-portal hip arthroscopy by adapting single-portal knee arthroscopy equipment.¹⁰ In our experience, it is possible to perform limited hip arthroscopic procedures with existing SPA technology; these procedures include diagnostic arthroscopy, biopsy, loose body removal, chondroplasty, labral debridement, synovectomy, and ligamentum teres debridement (Table 1). A detailed review of the currently available SPA instrumentation has been previously published by Cooper and Fouts.¹⁰

Some theoretical advantages of the proposed technique for single-portal arthroscopy of the hip are the less invasive nature of the operation and the notion that the technique allows for an easier time navigating the deep joint with less risk of iatrogenic injury because intra-articular triangulation is not required (Table 2). There are some limitations to this SPA technique; mainly, the basic instrumentation currently available limits the complexity of procedures. Specifically,

Table 2. Surgical Pearls and Pitfalls

Pearls
Smaller camera diameter
Established access to a significant portion of the joint without making another portal
Less iatrogenic trauma risk to the iliopsoas space and iliofemoral ligament as would be necessitated through an anterior portal to accomplish a similar task
Less technically challenging procedure because of the establishment of only 1 portal and no need for intra-articular triangulation
Pitfalls
The technique necessitates parallel coordinated hand movements, which differs from traditional arthroscopic techniques.
Currently, the technology is based on a 30° arthroscope, and the surgeon may need a 70° arthroscope to establish additional perspectives.
Excision of loose bodies >3 mm is limited by the size of the portal tract.
The technique cannot be technically performed in patients who are too large or are obese because of limited hip arthroscopy-specific instrumentation.

current single-portal hip arthroscopy is not optimized for labral repair and techniques to address femoroacetabular impingement. While arthroscopic surgeons are facile with intra-articular triangulation techniques, working in parallel through a single portal for arthroscopic viewing and surgery is ergonomically different and has an associated learning curve. Finally, a more minimally invasive technique may allow for quicker recovery because of reduced soft-tissue injury and less risk of associated iatrogenic access injury (Table 2).

At our institution, we have performed 6 SPA hip procedures without complication (unpublished data, A.J.S.) (Figs 2 and 4). At present, the SPA technology is not specifically designed for hip arthroscopy or major arthroscopic hip reconstructive techniques. As the technology continues to evolve and the surgical technique is refined, there is a potential for continued development of this SPA hip surgical technique for more complex procedures. Long-term studies following clinical outcomes of SPA hip surgery are needed, and identification of specific patient populations who will benefit from single-portal arthroscopy is still not fully understood. We advocate for careful preoperative assessment and review of imaging before considering the use of the SPA technique to address the hip pathologies described in Table 1.

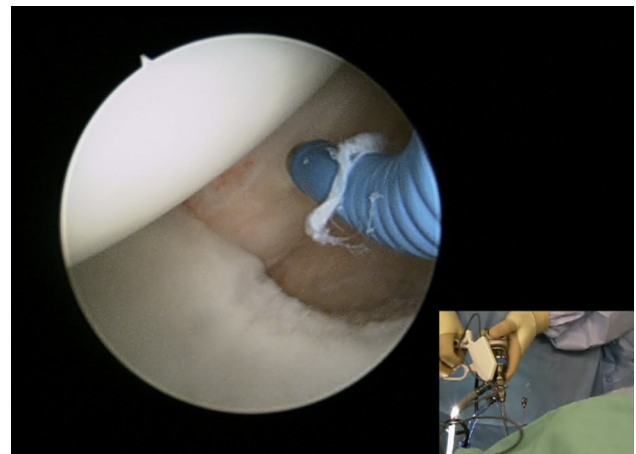


Fig 4. Intra-articular view and external view of single-portal arthroscopic (SPA) surgery in a right hip. The arthroscopic image shows an intra-articular radiofrequency probe and ablation device during SPA surgery in the central compartment with the patient positioned supine. The inset depicts the associated external view of single-portal arthroscopy using the radiofrequency ablation probe and arthroscope with an SPA cannula coupling the camera and the operative instrument. The SPA cannula is placed through the anterolateral portal, and a separate spinal needle is placed through the modified anterior portal to provide fluid outflow to aid in arthroscopic visualization during SPA surgery.

References

1. Botser IB, Smith TW Jr, Nasser R, et al. Open surgical dislocation versus arthroscopy for femoroacetabular impingement: A comparison of clinical outcomes. *Arthroscopy* 2011;27:270-278.
2. Howse EA, Wooster BM, Mannava S, et al. Arthroscopic treatment of slipped capital femoral epiphysis screw impingement and concomitant hip pathology. *Arthrosc Tech* 2014;3:e515-e517.
3. Stabile KJ, Neumann JA, Mannava S, et al. Arthroscopic treatment of bucket-handle labral tear and acetabular fracture. *Arthrosc Tech* 2014;3:e283-e287.
4. Stubbs AJ, Andersen JS, Mannava S, et al. Arthroscopic hip labral repair: The Iberian suture technique. *Arthrosc Tech* 2014;3:e351-e354.
5. Shetty VD, Villar RN. Hip arthroscopy: Current concepts and review of literature. *Br J Sports Med* 2007;41:64-68. discussion 68.
6. Kowalczyk M, Bhandari M, Farrokhyar F, et al. Complications following hip arthroscopy: A systematic review and meta-analysis. *Knee Surg Sports Traumatol Arthrosc* 2013;21:1669-1675.
7. Sampson TG. Complications of hip arthroscopy. *Clin Sports Med* 2001;20:831-835.
8. Hoppe DJ, de Sa D, Simunovic N, et al. The learning curve for hip arthroscopy: A systematic review. *Arthroscopy* 2014;30:389-397.
9. Gupta A, Redmond JM, Hammarstedt JE, et al. Safety measures in hip arthroscopy and their efficacy in minimizing complications: A systematic review of the evidence. *Arthroscopy* 2014;30:1342-1348.
10. Cooper DE, Fouts B. Single-portal arthroscopy: Report of a new technique. *Arthrosc Tech* 2013;2:e265-e269.
11. Montgomery SR, Ngo SS, Hobson T, et al. Trends and demographics in hip arthroscopy in the United States. *Arthroscopy* 2013;29:661-665.
12. Pascual-Garrido C, McConkey MO, Young DA, et al. Can hip arthroscopy be performed with conventional knee-length instrumentation? *Arthroscopy* 2014;30:1588-1594.
13. Buess E, Schneider C. Simplified single-portal V-shaped SLAP repair. *Arthroscopy* 2006;22:680.e1-680.e4.
14. Byrd JW, Chern KY. Traction versus distension for distraction of the joint during hip arthroscopy. *Arthroscopy* 1997;13:346-349.
15. Robertson WJ, Kelly BT. The safe zone for hip arthroscopy: A cadaveric assessment of central, peripheral, and lateral compartment portal placement. *Arthroscopy* 2008;24:1019-1026.
16. Bozic KJ, Chan V, Valone FH III, et al. Trends in hip arthroscopy utilization in the United States. *J Arthroplasty* 2013;28:140-143 (suppl).
17. Colvin AC, Harrast J, Harner C. Trends in hip arthroscopy. *J Bone Joint Surg Am* 2012;94:e23.
18. Stevens MS, Legay DA, Glazebrook MA, et al. The evidence for hip arthroscopy: Grading the current indications. *Arthroscopy* 2010;26:1370-1383.
19. Burman MS. Arthroscopy or the direct visualization of joints: An experimental cadaver study. 1931. *Clin Orthop Relat Res* 2001;(390):5-9.
20. O'Connor R. *Arthroscopy*. Philadelphia, PA: JB Lippincott, 1977.