

2014

Abnormal cingulum bundle development in autism: A probabilistic tractography study

T. Ikuta

K. M. Shafritz

J. Bregman

B. D. Peters

Northwell Health

P. Gruner

See next page for additional authors

Follow this and additional works at: <https://academicworks.medicine.hofstra.edu/publications>

 Part of the [Psychiatry Commons](#)

Recommended Citation

Ikuta T, Shafritz K, Bregman J, Peters BD, Gruner P, Malhotra AK, Szeszko PR. Abnormal cingulum bundle development in autism: A probabilistic tractography study. . 2014 Jan 01; 221(1):Article 1036 [p.]. Available from: <https://academicworks.medicine.hofstra.edu/publications/1036>. Free full text article.

This Article is brought to you for free and open access by Donald and Barbara Zucker School of Medicine Academic Works. It has been accepted for inclusion in Journal Articles by an authorized administrator of Donald and Barbara Zucker School of Medicine Academic Works. For more information, please contact academicworks@hofstra.edu.

Authors

T. Ikuta, K. M. Shafritz, J. Bregman, B. D. Peters, P. Gruner, A. K. Malhotra, and P. R. Szeszko



Published in final edited form as:

Psychiatry Res. 2014 January 30; 221(1): 63–68. doi:10.1016/j.psychres.2013.08.002.

Abnormal Cingulum Bundle Development in Autism: A Probabilistic Tractography Study

Toshikazu Ikuta^{1,2}, Keith M. Shafritz^{1,3}, Joel Bregman^{1,4}, Bart Peters^{1,2}, Patricia Gruner⁵, Anil K. Malhotra^{1,2,6}, and Philip R. Szeszko^{1,2,6}

¹Center for Psychiatric Neuroscience, Feinstein Institute for Medical Research, Manhasset, NY, 11030, USA

²Division of Psychiatry Research, Zucker Hillside Hospital, North Shore-LIJ Health System, Glen Oaks, NY, 11004, USA

³Department of Psychology, Hofstra University, Hempstead, NY 11549, USA

⁴The Center for Autism, Philadelphia PA 19131, USA

⁵Department of Psychiatry, School of Medicine, Yale University New Haven, CT 06511, USA

⁶Hofstra North Shore – LIJ School of Medicine, Departments of Psychiatry and Molecular Medicine, Hempstead, NY, USA

Abstract

There is now considerable evidence that white matter abnormalities play a role in the neurobiology of autism. Little research has been directed, however, at understanding (a) typical white matter development in autism and how this relates to neurocognitive impairments observed in the disorder. In this study we used probabilistic tractography to identify the cingulum bundle in 21 adolescents and young adults with autism spectrum disorder (ASD), and 21 age- and sex-matched healthy volunteers. We investigated group differences in the relationships between age and fractional anisotropy, a putative measure of white matter integrity, within the cingulum bundle. Moreover, in a preliminary investigation, we examined the relationship between cingulum fractional anisotropy and executive functioning using the Behavior Rating Inventory of Executive Function (BRIEF). The ASD participants demonstrated significantly lower fractional anisotropy within the cingulum bundle compared to the typically developing volunteers. There was a significant group-by-age interaction such that the ASD group did not show the typical age-associated increases in fractional anisotropy observed among healthy individuals. Moreover, lower fractional anisotropy within the cingulum bundle was associated with worse BRIEF behavioral regulation index scores in the ASD group. The current findings implicate a dysregulation in cingulum bundle white matter development occurring in late adolescence and early adulthood in autism spectrum disorder, and suggest that greater disturbances in this trajectory are associated with executive dysfunction in ASD.

© 2013 Elsevier Ireland Ltd. All rights reserved.

Address correspondence to: Toshikazu Ikuta, Ph.D., Department of Communication Sciences and Disorders, School of Applied Sciences, University of Mississippi, 352 Rebel Drive, University, MS 38766, USA. Tel.: +1-662-915-7652; fax: +1-662-915-5717. tikuta@olemiss.edu.

Publisher's Disclaimer: This is a PDF file of an unedited manuscript that has been accepted for publication. As a service to our customers we are providing this early version of the manuscript. The manuscript will undergo copyediting, typesetting, and review of the resulting proof before it is published in its final citable form. Please note that during the production process errors may be discovered which could affect the content, and all legal disclaimers that apply to the journal pertain.

Keywords

Autism Spectrum Disorder; Diffusion Tensor Imaging; White Matter; Development

Introduction

Autism is a childhood neurodevelopmental disorder characterized by significant impairments in social interaction, reciprocity, and communication, in addition to restricted and stereotyped interests, activities and behaviors (Volkmar and Klin, 1999). It is likely that executive dysfunction contributes to the pathogenesis and severity of these core impairments (Hill and Hill, 2004; Shafritz et al., 2008). Executive dysfunction is a very common autism comorbidity/endophenotype, particularly deficits in cognitive flexibility, set-shifting, planning, working memory, and response inhibition (Landa and Goldberg, 2005; Lopez et al., 2005; Ozonoff and McEvoy, 1994). Appropriate interpersonal interactions and behavior depend on the ability to maintain relevant information in short term memory while planning social actions and responses, to adequately inform conversational partners of shifts in topic, and to inhibit the impulse to behave in a socially compromising fashion (Landa and Goldberg, 2005; Turner, 1997).

Recent data support the hypothesis that white matter abnormalities in the cingulum bundle play a role in the neurobiology of ASD (Thakkar et al., 2008), although the functional significance of these white matter abnormalities remains largely unknown. Abnormalities of the cingulate cortex in ASD, on the other hand, have been associated with impairments in executive functioning (Pellicano, 2012), attention and/or performance monitoring (Barttfeld et al., 2012), emotion recognition (Hall et al., 2003), socialization (Monk et al., 2009; Noriuchi et al., 2010), and self awareness (Lombardo et al., 2009). In a recent review of 48 neuroimaging studies, Travers et al. (2012) reported that in comparison with neurotypical controls, individuals with ASD exhibited white matter abnormalities in several regions, but most notably and consistently in the cingulum bundle, corpus callosum, and temporal lobe. The majority of these studies were conducted using voxelwise or region-of-interest approaches and thus, little work has been directed at using tractography across the entire cingulum bundle.

Unlike these other approaches, probabilistic tractography enables the investigation of white matter integrity of an entire bundle through an automated process using a single statistical analysis, rather than multiple analyses (voxelwise approach) or manual tracing (region-of-interest approach). Therefore, tractography allows us to estimate tract-epidemic white matter integrities by objectively assessing the tract structure. A limited number of tractography studies investigating the cingulum bundle in ASD has produced seemingly conflicting findings with reports of higher (Weinstein et al., 2011) and lower (Jou et al., 2011) fractional anisotropy (FA) in the ASD groups. However, direct comparison between these two studies is difficult, because they investigated very different childhood populations. While Weinstein and colleagues (2011) found increased FA in the cingulum in young children with ASD (3.2 ± 1.1 years old; range 1.5–5.8 years) compared with typically-developing controls, Jou and colleagues (2011a) found reduced FA in ASD adolescents (13.5 ± 4.0 years old; range 8–19 years) compared with typically-developing controls. It is conceivable that in ASD, there is hyper-maturation of the cingulum bundle in early-childhood followed by fewer age-related changes (or slower maturation) in adolescence and young adulthood. Therefore, a primary goal of the current study is to further examine potential developmental influences on white matter integrity by specifically studying adolescents and young adults with ASD.

The relationship of white matter abnormalities in ASD with core cognitive deficits such as executive dysfunction remains largely unknown, although developmental considerations may be an important factor. Executive functions (EF) continue to develop through adolescence and early adulthood (Blakemore and Choudhury, 2006), with commensurate functional changes in neural regions associated with cognitive control processes (Luna et al., 2010) and in white matter integrity (Lebel et al., 2012). Further, in typical development, FA in white matter tracts continues to increase through late childhood and early adolescence (Lebel et al., 2012). It is unclear whether the typical improvement in EF observed throughout childhood and adolescence is a direct result of increases in white matter integrity, although it has been suggested that increases in long-range projections throughout EF brain systems are valuable (Luna et al., 2010).

While there is considerable evidence that autism is characterized by a deficiency in white matter development, the period of abnormal growth has not been consistent across studies. In particular, differential age-related white matter changes in ASD have been demonstrated across a broad age range, i.e., infants, children, and adults (Ben Bashat et al., 2007; Cascio et al., 2012; Kleinhans et al., 2012; Mak-Fan et al., 2012; Mengotti et al., 2011; Schumann et al., 2010; Wolff et al., 2012). More specifically, greater FA at 6 months was reportedly followed by slower development, resulting in lower FA at 24 months (Wolff et al., 2012). In addition, less robust age-associated increases in FA (white-matter integrity) have been reported between the ages of 2 and 6 (Cascio et al., 2012) and 13 and 35 years (Kleinhans et al., 2012), as well as during preadolescence (Mak-Fan et al., 2012). In contrast, white matter integrity in typical development, including cingulum FA, has been shown to increase until early adulthood followed by slow decrease (Lebel et al., 2012). Taken together, these results suggest that hyper-maturation of white matter occurs in ASD earlier than 6 months of age, followed by a slowing in white matter development compared with typically developing youth. Important unanswered questions in the field include the functional significance of the enhancement in white matter integrity that occurs during normal adolescence and young adulthood, and whether this pattern also occurs in the ASD population (Barnea-Goraly et al., 2005; Peters et al., 2012).

Given prior evidence for white matter abnormalities in ASD, the primary goal of the current study was to examine group differences and age-related effects in the cingulum bundle during adolescence and early adulthood in ASD versus age- and sex-matched neurotypical participants using probabilistic tractography. Because of the prior association of cingulate cortex function with EF symptom severity in ASD (Thakkar et al., 2008; Shafritz et al., 2008), we predicted that structural integrity particularly within the cingulum bundle would be important for EF symptomatology. Specifically, we hypothesized that (1) the ASD group would be characterized by FA deficits within the cingulum bundle compared to the neurotypical group; (2) the ASD group would demonstrate aberrant age-associated white matter changes within the cingulum bundle compared to the neurotypical group and (3) FA would be associated with executive dysfunction among individuals with ASD.

Methods

Subjects

The sample comprised 21 individuals with Autism Spectrum Disorder (mean age 18.1 years, $SD=2.7$, range 13–23 years, 18 males and 3 females), recruited from the Fay J. Linder Center for Autism and Developmental Disabilities within the North Shore-LIJ Health System. All participants in the ASD group met DSM-IV criteria for either autistic Disorder ($n=15$) or Asperger's Disorder ($n=6$), established through diagnostic interviews by a child psychiatrist (JB) which included administration of the Autism Diagnostic Observation Schedule-Generic (ADOS-G) (Lord et al., 2000) and the Autism Diagnostic Interview-

Revised (ADI-R) (Lord et al., 1994). Although co-morbid symptom profiles were also present (common among those with ASD), a general psychiatric interview did not document co-morbid disorders. Eight (8) participants had a history of psychotropic medication use. Three (3) had a history of psychostimulant use, but were free of medication at the time of study. Ten participants were currently receiving the following medications (numbers in parentheses): citalopram (2); escitalopram (1); alprozolam (1); venlafaxine (1); sertraline (1); aripiprazole (2); clomipramine (1); lithium (1) and guanfacine (1).

In addition, 21 age- and gender-matched typically developing adolescents (mean age 18.2 years SD=2.9, range 12–23 years, 18 males and 3 females) also participated in this study and were screened using detailed interviews to assure absence of psychiatric, neurological, or developmental disorders. Exclusion criteria for all participants were the presence of co-morbid mood, anxiety, psychotic, seizure disorders, or attention deficit hyperactivity disorder, use of anticonvulsant medication, and IQ < 75 as determined from either the Wechsler Abbreviated Scale of Intelligence (WASI) or estimated from the Wide Range Achievement Test. This study was approved by the North Shore - LIJ Institutional Review Board and written informed consent was obtained from all participants and from parents for minors. All minors provided written assent to participate in the study.

Neuropsychological Assessment

Eleven participants (age = 18 years) in the ASD group completed the Behavior Rating Inventory of Executive Function – Adult Version (BRIEF; Gioia et al., 2000) Self-Report. This version of the BRIEF consists of 75 individual statements for which the participant indicates whether he or she “never, sometimes, or often” engages in a particular behavior. Validity of self-report versions of the BRIEF in capturing executive dysfunction in ASD has been established, with ASD individuals reporting difficulties with several aspects of EF, including behavioral and cognitive shifts, working memory and task completion (Gioia et al., 2000). Several subscales and composite index scores are established through the BRIEF, including Emotional Control, Shifting (cognitive flexibility), and Inhibition (inhibitory control) as well as the overall Behavioral Regulation Index (BRI) consisting of inhibition, shifting, emotional control, and monitoring.

BRIEF T-scores (M=50, SD=10 for a normative population) were used for the correlational analysis between cingulum FA and EF ability. In the standardization of the BRIEF, T-scores were derived from raw scores by separating out the standardization sample into categories by age and gender (Gioia et al., 2010). Therefore, although age differences in raw scores may be apparent, the influence of age on T-scores would be minimized. T-score distributions were established for each subscale and index score, with the exact percentile for each raw score varying slightly. Although each curve approximates the normal distribution, each curve has a slightly different shape with a small positive skew, as is the case for many problem-oriented clinical scales (Gioia et al., 2010). IQ was not specifically measured in the standardization sample, but IQ has not been significantly associated with EF abilities (Welsh et al., 1991).

We did not give the BRIEF-SR to participants younger than 18 due to the possibility that younger participants would not have sufficient insight into their own EF abilities. Instead, parents or other informants completed the parent (or informant) version of the BRIEF. Because the parent, informant, and self-report versions of the BRIEF have independently-derived T-scores and differently-shaped score distributions, we could not combine scores from all sources into a single analysis. Further, the number of parent and informant forms compiled in this study was too small to perform a reliable correlation analysis for those participants. Therefore, we were left with eleven participants for the correlational analysis.

WASI full scale IQs were obtained for all participants in the ASD group and 12 neurotypical participants. Full scale IQ for 9 neurotypical participants was estimated using the Wide Range Achievement Test.

Image Acquisition and Analysis

All subjects received a Diffusion Tensor Imaging (DTI) exam at the North Shore University Medical Center, Manhasset, NY, on a GE Signa HDx 3.0T system (General Electric, Milwaukee, Wisconsin). All scans were reviewed by a radiologist for gross abnormalities that would preclude participation in this research study. The sequence included volumes with diffusion gradients applied along 31 non-parallel directions ($b = 1000 \text{ s/mm}^2$) and 5 volumes without diffusion weighting ($TR = 14 \text{ s}$, $TE = 75.3\text{--}82.3\text{ms}$, matrix = 128×128 , FOV = 240 mm). Each volume consisted of 51 contiguous 2.5-mm axial slices acquired parallel to the anterior-posterior (AC-PC) commissural line using a ramp sampled, double spin-echo, single shot echo-planar imaging (EPI) method. Data acquisition used parallel imaging with an acceleration factor of 2.

Image processing was conducted using the Functional Magnetic Resonance Imaging of the Brain Library 4.1.6 (FSL; Oxford, United Kingdom). Eddy-current distortions and head-motion displacements were corrected through affine registration of the 31 diffusion volumes to the first b_0 volume using FSL's FLIRT tool (Jenkinson and Smith, 2001). The b-vector table for each participant was then adjusted according to the rotation parameters of this linear correction. Non-brain tissue was removed using FSL's Brain Extraction Tool. Fractional Anisotropy (FA), as well as axial, radial and mean diffusivities, was computed for each voxel of the brain by fitting a diffusion tensor model to the raw diffusion data using weighted least squares from the DTIFIT tool in FSL's Diffusion Toolbox.

Probabilistic Tractography

The local (i.e., within-voxel) probability density functions of the principal diffusion direction were estimated using Markov Chain Monte Carlo sampling in FSL's Bedpostx tool (Behrens et al., 2007). A spatial probability density function across voxels was then estimated based on these local probability density functions using FSL's Probtrackx tool (Behrens et al., 2007), in which 5000 samples were taken for each input voxel with a 0.2 curvature threshold, 0.5mm step length, and 2000 steps per sample. For each tract, seed regions, way-points, termination and exclusion masks were defined on the MNI152 1mm template, and automatically registered to each subject's diffusion space using FLIRT with the affine parameters obtained from co-registration between the first b_0 volume and the MNI152 1mm T1 brain (Jenkinson and Smith, 2001). To segment the cingulum tracts, seed regions, way-points, target regions, termination and exclusion masks were drawn on the MNI152 T1 brain provided in FSL, using FSL's FMRIB58_FA template as a DTI specific reference. The seed mask for the anterior cingulum was manually drawn on 3 coronal slices at the level of the anterior edge of the corpus callosum, as defined in the MNI152_T1 template. A second seedmask was manually drawn on 3 coronal slices, just posterior to the splenium of the corpus callosum. Fibers that ran anterior along the cingulate gyrus, inferior to the level of the hippocampus or to the contralateral hemisphere were excluded. The cingulum of each subject was thresholded at a normalized probability value of 0.05 and visually inspected to confirm successful tracing in each individual by multiple experienced technicians (Figure 1).

To establish the specificity of the association between white matter integrity in cingulum bundle and clinical symptomatology of ASD, we selected the Anterior Thalamic Radiation (ATR) as a control tract. A seedmask of the thalamus was derived from the HarvardOxford subcortical atlas (Desikan et al., 2006), as provided in FSL, and then manually edited

according to the MNI152 T1 template to exclude the medial and lateral geniculate nuclei. Prefrontal WM was used as a way-point, derived by segmenting the WM from the prefrontal cortical regions in the HarvardOxford atlas (Desikan et al. 2006). Fibers were terminated when they reached the prefrontal WM. In addition, only fibers going through the anterior limb of the internal capsule (ALIC) were retained. This second way-point was defined on 3 coronal slices in the anterior section of the ALIC. Fibers going through occipital, temporal, parietal, sensory-motor (including the supplementary motor area) GM, as defined with the HarvardOxford cortical atlas (Desikan et al. 2006), were excluded. This exclusion mask was manually expanded to exclude fibers going into the brainstem or the contralateral hemisphere. The bilateral ATR of each subject was then thresholded at a normalized probability value of 0.005.

Head Displacement

To assess head motion that could potentially affect fractional anisotropy and other DTI derived measurements, the head displacement for each subject was estimated. As a displacement distance between two DTI volumes, the root mean square deviation was calculated from intra-subject registration (eddy-current and motion correction) parameters, at an $r = 40\text{mm}$ spherical surface using FSL's rmsdiff tool (<http://www.fmrib.ox.ac.uk/fsl/flirt/overview.html>). For each subject, the sum of displacement distances between each consecutive pair of 31 DTI volumes (i.e., 30 displacement distances) was computed as the total head displacement for the subject. No subject was excluded based on the displacement distances.

Statistical Analysis

To assess the effect of laterality, right and left cingulum FA values, as well as axial, radial and mean diffusivities, were tested in 2×2 (group x hemisphere) analysis of covariance (ANCOVA) with head displacement, age and IQ as covariates. To investigate the potential relationship between age and cingulum bundle FA, we tested for a group x age interaction using a 2×2 ANCOVA with head displacement and IQ as covariates. In addition, Pearson's product moment correlations were computed between age and cingulum FA for each group separately, adjusted for IQ and head displacement. To evaluate the association between cingulum FA and EF, Pearson's product moment correlations were computed between cingulum FA values and each of the measures from the BRIEF separately for each group.

Results

Demographic and clinical characteristics for the sample are illustrated in Table 1. There was no significant difference in distributions of age and sex ($p > 0.05$), although IQ was significantly higher in the control group. In addition, the groups did not differ significantly in head displacement ($t = 0.82$, $df = 40$ $p = 0.42$). As expected, the ASD group demonstrated significantly worse performance on the BRIEF BRI and each of its 3 subscales compared to the neurotypical group (Table 1).

ANCOVA revealed a main effect of group ($F_{1,77} = 7.11$, $p = 0.009$) and hemisphere ($F_{1,77} = 13.39$, $p < 0.001$), but no significant group x hemisphere interaction ($F_{1,77} = 1.54$, $p = 0.22$) for FA. Overall, the ASD group had lower FA in the bilateral cingulum bundle ($t = 2.23$, $df = 40$, $p = 0.032$) than the neurotypical group and FA was significantly higher in the left compared to the right hemisphere ($t = 3.19$, $df = 82$, $p = 0.002$). The group-by-age interaction was statistically significant ($F_{1,36} = 4.55$, $p = 0.040$) indicating that the ASD group did not show the typical age-associated increase in cingulum FA that was present in the neurotypical group (Figure 2). Pearson product moment correlations indicated that age was positively correlated with cingulum FA among the neurotypical group ($r = 0.61$, $df =$

17, $p = 0.0016$), but not in the autism group ($r = 0.18$, $df = 17$, $p = 0.45$). Axial, radial and mean diffusivities showed neither significant main effects nor interactions; the exception being that mean diffusivity demonstrated a significant effect of age across groups ($F_{1,77} = 4.28$, $p = 0.046$). To examine whether medication status of the ASD participants influenced FA, we compared mean cingulum FA between ASD participants with a history of medication use and those with no medication use. No effect of medication use on FA was observed ($t = 1.48$, $df = 19$, $p = 0.16$).

There was a significant negative correlation between cingulum FA and total BRIEF BRI score in the ASD group ($r = -0.70$, $df = 9$, $p = 0.016$; Figure 3A), but not in the neurotypical group ($p > 0.05$). In a post-hoc analysis, cingulum FA was negatively correlated with the shifting subscale in the autism group ($r = -0.61$, $df = 9$, $p = 0.044$; Figure 3B), but not in the control group ($p > 0.05$).

For ATR FA, there was neither an effect of group ($p = 0.58$) nor a group-by-age interaction ($p = 0.22$). Further, there was no significant correlation between ATR FA and BRIEF BRI score ($p = 0.23$).

Discussion

The current results show a deficiency in cingulum bundle white matter development in ASD during late adolescence and early adulthood. The current findings thus extend prior work by implicating abnormalities in typical age-related changes within cingulum bundle across this age period in ASD, and are consistent with the hypothesis that a disturbance in cingulum maturation may play a role in the executive impairment associated with the disorder. An important strength of the current study is that the groups were individually matched for age and sex and that the results remained statistically significant even after controlling for the effects of IQ. Moreover, the current study is unique in at least two additional ways. First, we expand upon prior literature (Weinstein et al., 2011; Jou et al, 2011a) by examining white matter integrity in adolescents and young adults with ASD, thereby attempting to resolve discrepancies in these prior findings that may be due to developmental factors. Second, we show that white matter integrity particularly in the cingulum bundle is negatively associated with the severity of self-reported EF deficits in ASD.

Cingulate abnormalities have been implicated in the pathogenesis of autism across multiple neuroimaging measures, including structural (Jiao et al., 2010) and functional (Bolling et al., 2011) magnetic resonance imaging. Moreover, using activation likelihood estimation meta-analysis, Cauda et al. (2011) reported that more gray matter was observed bilaterally in the right anterior cingulate cortex and posterior cingulate cortex (among other regions) in individuals with ASD. White matter abnormalities, as assessed via diffusion tensor imaging, have also been strongly implicated in the neurobiology of autism (Travers et al., 2012) and observed using conservative analytic approaches such as tract based spatial statistics (Cheng et al., 2010). Prior results suggest that white matter integrity may be higher in ASD compared with typical development in early childhood, but may be lower in ASD in early adolescence. The current study suggests that age-associated differences in cingulum white matter integrity continue into late adolescence and young adulthood, specifically the trend of lower white matter integrity in ASD compared with typical development.

The ASD group did not demonstrate typical age-associated increases of the cingulum bundle (Lebel and Beaulieu, 2011), which was observed robustly in the neurotypical group. The current findings help resolve disparities in prior literature, and broadly align with the results from longitudinal work demonstrating significant abnormalities in white matter development in individuals with ASD. For example, Hua et al. (2011) created longitudinal brain tissue

growth maps in 13 autistic and seven typically developing boys. Although the typically developing boys demonstrated white matter growth during this longitudinal period, this pattern was considerably slower among the boys with autism who were between the ages of 12 and 15 years. Moreover, in one of the largest studies conducted to date, Courchesne et al. (2011) reported changes in brain size among autistic and typical subjects ranging in age from 12 months to 50 years based on analyses of 586 longitudinal and cross-sectional MRI scans. Courchesne et al. (2011) interpreted their findings to suggest significant brain overgrowth during the infancy and toddler years which is followed by an accelerated rate of decline and possible neurodegeneration from 12 to 50 years old. The relation between age and FA in the current results (Figure 2) is consistent with the hypothesis that individuals with ASD may initially demonstrate greater FA within the cingulum bundle, followed by a period of slower development through late adolescence and early adulthood. The current findings do not directly confirm degeneration of white matter in this particular age range, as might be suggested by Courchesne and colleagues (2011). However, our results show a significant deficiency in ASD of typical age-related enhancement of white matter, potentially indicating neurodegeneration. Further studies are necessary to specifically address the question of whether ASD is associated with slower development of white matter in adolescence or is marked by a true pattern of neurodegeneration.

Findings in the current study are further consistent with prior cross-sectional studies demonstrating age-by-group interactions among individuals with ASD compared with neurotypical groups, although the results of these studies have not always been consistent. Mak-Fan and Morris (2012) reported age-by-group interactions in frontal, long distant, interhemispheric and posterior tracts, for several diffusivity measures (although not FA) in boys that ranged in age from 6 to 14 years. Mengotti and D'Agostini (2011) found that age correlated negatively with lobar and callosal ADC measurements in individuals with autism, but not in children with normal development in the age range of 4 to 14. More recently, Kleinhans and Pauley (2012) reported significant group-by-age interactions for FA, radial diffusivity, and mean diffusivity in the majority of white matter tracts examined. In contrast to the current results, however, Kleinhans and Pauley (2012) reported that controls demonstrated age-associated reductions in FA, while the ASD group demonstrated increases over a broad age span. We suggest that the FA reduction observed by Kleinhans and Pauley (2012) is due to the inclusion of the wider age range (13 to 40 years old) and their reliance on linear analytical techniques. It has been shown by a larger study that FA development is marked by a non-linear curve whose peak occurs in early adulthood (Lebel et al., 2012). According to those findings, the participants in our study (12 to 23 years old) would be younger than the age for peak FA. Therefore, we believe our observation of a positive association between age and cingulum bundle FA in the control group represents the age-associated change in white matter during typical development found in this larger study. However, it remains unclear the overall characteristics of age-related white matter change in ASD throughout development. Therefore, it would be ideal for future studies to incorporate a wider age range and larger sample size to investigate longitudinal developmental changes in white matter integrity in ASD.

Few studies have investigated structure-function relations involving white matter abnormalities in ASD. Although neuropsychological data were available for only a limited number of subjects, the current finding that the disruption in typical white matter development within the cingulum bundle in the ASD group may be associated with executive dysfunction provides an important new avenue for further investigation. It may be noteworthy that this association was most pronounced in the shifting score, but not in the emotional control or inhibition scales. The shifting score assesses the ability to change tasks rapidly and requires the ability to identify and solve problems in novel ways. More specifically, these individuals with excellent shifting can transition between tasks,

demonstrate the ability to tolerate changes and switch cognitive set without losing track of the overall task goal. The current results are highly consistent with those of Shafritz and colleagues (2008), who found that functional activation in anterior cingulate during a response shifting task was negatively correlated with scores on the Restricted, Repetitive and Stereotyped Patterns of Behavior Domain of the ADI-R. The results also converge with those of Gioia (2002) who reported that individuals with ASD could be distinguished from other groups with similar phenomenology, including those with traumatic brain injury and ADHD, by deficits in flexibility. In contrast, we did not observe associations with the inhibition scale, which requires the ability to inhibit prepotent tendencies to respond to stimuli and act in an impulsive manner. Furthermore, no association with the emotional control scale was observed, which taps the ability to modulate emotion control and/or expression and tolerate changes in mood. Therefore, deficits in cingulate connectivity and function may be specifically related to behavioral and set shifting ability in individuals with ASD, and not necessarily to other aspects of EF. Taken together, these findings provide insights for a selective and specific biological marker for set shifting deficits often observed in ASD.

There were a number of limitations to this study that should be acknowledged. Given the cross-sectional nature of our study we could not infer whether slower white matter development would be observed in the ASD individuals in a longitudinal design. In addition, we acknowledge that self-report neuropsychological data were not available for all individuals in the ASD group, resulting in a small sample size for these analyses. Although we had adequate power to observe EF/white matter relationships for certain subscores of the BRIEF that align well with prior literature, we may have missed important correlations that were not significant due to the limited sample size. The preliminary association observed between white matter structure and self-report measures of EF will need confirmation in future studies with larger samples. Lastly, the relationship between these white matter abnormalities and cortical gray matter and functional deficits was not investigated in the current study, but should be integrated together as a goal of future research.

In sum, the current results implicate a deficit in the neurodevelopmental trajectory of the cingulum bundle in individuals with ASD during adolescence and early adulthood. This abnormality may contribute to the executive dysfunction observed in the disorder.

Acknowledgments

We thank Linda Spritzer, Jamie Wagner, Melissa Buchman, and Rachel Ginsberg for help with subject recruitment, cognitive test administration, and data analysis; Dr. Peter Kingsley, John Cholewa and John Ferrannini for technical assistance with MRI data collection. This work was supported by NIH grant M01RR018535 and grants from Hofstra University. All authors report no competing financial interests.

References

- Barnea-Goraly N, Menon V, Eckert M, Tamm L, Bammer R, Karchemskiy A, Dant CC, Reiss AL. White Matter Development During Childhood and Adolescence: A Cross-sectional Diffusion Tensor Imaging Study. *Cerebral Cortex*. 2005; 15:1848–1854. [PubMed: 15758200]
- Barttfeld P, Wicker B, Cukier S, Navarta S, Lew S, Leiguarda R, Sigman M. State-dependent changes of connectivity patterns and functional brain network topology in autism spectrum disorder. *Neuropsychologia*. 2012; 50:3653–3662. [PubMed: 23044278]
- Behrens TEJ, Berg HJ, Jbabdi S, Rushworth MFS, Woolrich MW. Probabilistic diffusion tractography with multiple fibre orientations: What can we gain? *NeuroImage*. 2007; 34:144–155. [PubMed: 17070705]

- Ben Bashat D, Kronfeld-Duenias V, Zachor DA, Ekstein PM, Hendler T, Tarrasch R, Even A, Levy Y, Ben Sira L. Accelerated maturation of white matter in young children with autism: A high b value DWI study. *NeuroImage*. 2007; 37:40–47. [PubMed: 17566764]
- Blakemore SJ, Choudhury S. Development of the adolescent brain: implications for executive function and social cognition. *Journal of Child Psychology and Psychiatry*. 2006; 47:296–312. [PubMed: 16492261]
- Bolling DZ, Pitskel NB, Deen B, Crowley MJ, McPartland JC, Kaiser MD, Wyk BC, Wu J, Mayes LC, Pelphrey KA. Enhanced neural responses to rule violation in children with autism: a comparison to social exclusion. *Dev Cogn Neurosci*. 2011; 1:280–294. [PubMed: 21743819]
- Cascio C, Gribbin M, Gouttard S, Smith RG, Jomier M, Field S, Graves M, Hazlett HC, Muller K, Gerig G, Piven J. Fractional anisotropy distributions in 2- to 6-year-old children with autism. *Journal of Intellectual Disability Research*. 2012
- Cauda F, Geda E, Sacco K, D'Agata F, Duca S, Geminiani G, Keller R. Grey matter abnormality in autism spectrum disorder: an activation likelihood estimation meta-analysis study. *Journal of Neurology, Neurosurgery and Psychiatry*. 2011; 82:1304–1313.
- Cheng Y, Chou KH, Chen IY, Fan YT, Decety J, Lin CP. Atypical development of white matter microstructure in adolescents with autism spectrum disorders. *NeuroImage*. 2010; 50:873–882. [PubMed: 20074650]
- Courchesne E, Campbell K, Solso S. Brain growth across the life span in autism: Age-specific changes in anatomical pathology. *Brain Research*. 2011; 1380:138–145. [PubMed: 20920490]
- Desikan RS, Ségonne F, Fischl B, Quinn BT, Dickerson BC, Blacker D, Buckner RL, Dale AM, Maguire RP, Hyman BT, Albert MS, Killiany RJ. An automated labeling system for subdividing the human cerebral cortex on MRI scans into gyral based regions of interest. *NeuroImage*. 2006; 31:968–980. [PubMed: 16530430]
- Gioia, G.; Isquith, P.; Guy, S.; Kenworthy, L. Behavior Rating Inventory of Executive Function. Psychological Assessment Resources; Odessa, FL: 2000.
- Gioia GA, Isquith PK, Kenworthy L, Barton RM, Gioia GA, Isquith PK, Kenworthy L, Barton RM. Profiles of everyday executive function in acquired and developmental disorders. *Child Neuropsychology*. 2002; 8:121–137. [PubMed: 12638065]
- Hall GB, Szechtman H, Nahmias C. Enhanced salience and emotion recognition in Autism: a PET study. *American Journal of Psychiatry*. 2003; 160:1439–1441. [PubMed: 12900306]
- Hill EL, Hill EL. Executive dysfunction in autism. *Trends in Cognitive Sciences*. 2004; 8:26–32. [PubMed: 14697400]
- Hua X, Thompson PM, Leow AD, Madsen SK, Caplan R, Alger JR, O'Neill J, Joshi K, Smalley SL, Toga AW, Levitt JG. Brain growth rate abnormalities visualized in adolescents with autism. *Human Brain Mapping*. 2011; 34:425–436. [PubMed: 22021093]
- Jenkinson M, Smith S. A global optimisation method for robust affine registration of brain images. *Medical Image Analysis*. 2001; 5:143–156. [PubMed: 11516708]
- Jiao Y, Chen R, Ke X, Chu K, Lu Z, Herskovits EH. Predictive models of autism spectrum disorder based on brain regional cortical thickness. *NeuroImage*. 2010; 50:589–599. [PubMed: 20026220]
- Jou RJ, Matljevic N, Kaiser MD, Sugrue DR, Volkmar FR, Pelphrey KA. Structural Neural Phenotype of Autism: Preliminary Evidence from a Diffusion Tensor Imaging Study Using Tract-Based Spatial Statistics. *American Journal of Neuroradiology*. 2011; 32:1607–1613. [PubMed: 21799040]
- Kleinhans NM, Pauley G, Richards T, Neuhaus E, Martin N, Corrigan NM, Shaw DW, Estes A, Dager SR. Age-related abnormalities in white matter microstructure in autism spectrum disorders. *Brain Research*. 2012; 1479:1–16. [PubMed: 22902768]
- Landa R, Goldberg M. Language, Social, and Executive Functions in High Functioning Autism: A Continuum of Performance. *Journal of Autism and Developmental Disorders*. 2005; 35:557–573. [PubMed: 16211332]
- Lebel C, Beaulieu C. Longitudinal Development of Human Brain Wiring Continues from Childhood into Adulthood. *The Journal of Neuroscience*. 2011; 31:10937–10947. [PubMed: 21795544]
- Lebel C, Gee M, Camicioli R, Wieler M, Martin W, Beaulieu C. Diffusion tensor imaging of white matter tract evolution over the lifespan. *NeuroImage*. 2012; 60:340–352. [PubMed: 22178809]

- Lombardo MV, Chakrabarti B, Bullmore ET, Sadek SA, Pasco G, Wheelwright SJ, Suckling J, Consortium MA, Baron-Cohen S. Atypical neural self-representation in autism. *Brain*. 2009; 133:611–624. [PubMed: 20008375]
- Lopez BR, Lincoln AJ, Ozonoff S, Lai Z. Examining the Relationship between Executive Functions and Restricted, Repetitive Symptoms of Autistic Disorder. *Journal of Autism and Developmental Disorders*. 2005; 35:445–460. [PubMed: 16134030]
- Lord C, Risi S, Lambrecht L, Cook EH Jr, Leventhal BL, DiLavore PC, Pickles A, Rutter M. The autism diagnostic observation schedule-generic: a standard measure of social and communication deficits associated with the spectrum of autism. *J Autism Dev Disord*. 2000; 30:205–223. [PubMed: 11055457]
- Lord C, Rutter M, Le Couteur A. Autism Diagnostic Interview-Revised: a revised version of a diagnostic interview for caregivers of individuals with possible pervasive developmental disorders. *J Autism Dev Disord*. 1994; 24:659–685. [PubMed: 7814313]
- Luna B, Padmanabhan A, O’Hearn K. What has fMRI told us about the Development of Cognitive Control through Adolescence? *Brain and Cognition*. 2010; 72:101–113. [PubMed: 19765880]
- Mak-Fan, KM.; Morris, D.; Vidal, J.; Anagnostou, E.; Roberts, W.; Taylor, MJ. White matter and development in children with an autism spectrum disorder. *Autism*; 2012.
- Mengotti P, D’Agostini S, Terlevic R, De Colle C, Biasizzo E, Londero D, Ferro A, Rambaldelli G, Balestrieri M, Zanini S, Fabbro F, Molteni M, Brambilla P. Altered white matter integrity and development in children with autism: A combined voxel-based morphometry and diffusion imaging study. *Brain Research Bulletin*. 2011; 84:189–195. [PubMed: 21146593]
- Monk CS, Peltier SJ, Wiggins JL, Weng SJ, Carrasco M, Risi S, Lord C, Monk CS, Peltier SJ, Wiggins JL, Weng SJ, Carrasco M, Risi S, Lord C. Abnormalities of intrinsic functional connectivity in autism spectrum disorders. *Neuroimage*. 2009; 47:764–772. [PubMed: 19409498]
- Noriuchi M, Kikuchi Y, Yoshiura T, Kira R, Shigeto H, Hara T, Tobimatsu S, Kamio Y. Altered white matter fractional anisotropy and social impairment in children with autism spectrum disorder. *Brain Research*. 2010; 1362:141–149. [PubMed: 20858472]
- Ozonoff S, McEvoy RE. A longitudinal study of executive function and theory of mind development in autism. *Development and Psychopathology*. 1994; 6:415–431.
- Pellicano E. The development of executive function in autism. *Autism Research and Treatment*. 2012; 2012:146132. [PubMed: 22934168]
- Peters BD, Szeszkó PR, Radua J, Ikuta T, Gruner P, DeRosse P, Zhang JP, Giorgio A, Qiu D, Tapert SF, Brauer J, Asato MR, Khong PL, James AC, Gallego JA, Malhotra AK. White Matter Development in Adolescence: Diffusion Tensor Imaging and Meta-Analytic Results. *Schizophrenia Bulletin*. 2012; 38:1308–1317. [PubMed: 22499780]
- Schumann CM, Bloss CS, Barnes CC, Wideman GM, Carper RA, Akshoomoff N, Pierce K, Hagler D, Schork N, Lord C, Courchesne E. Longitudinal Magnetic Resonance Imaging Study of Cortical Development through Early Childhood in Autism. *The Journal of Neuroscience*. 2010; 30:4419–4427. [PubMed: 20335478]
- Shafritz KM, Dichter GS, Baranek GT, Belger A. The Neural Circuitry Mediating Shifts in Behavioral Response and Cognitive Set in Autism. *Biological Psychiatry*. 2008; 63:974–980. [PubMed: 17916328]
- Thakkar KN, Polli FE, Joseph RM, Tuch DS, Hadjikhani N, Barton JJS, Manoach DS. Response monitoring, repetitive behaviour and anterior cingulate abnormalities in autism spectrum disorders (ASD). *Brain*. 2008; 131:2464–2478. [PubMed: 18550622]
- Travers BG, Adluru N, Ennis C, Tromp DPM, Destiche D, Doran S, Bigler ED, Lange N, Lainhart JE, Alexander AL. Diffusion Tensor Imaging in Autism Spectrum Disorder: A Review. *Autism Research*. 2012:289–313. [PubMed: 22786754]
- Turner, M. Towards an executive dysfunction account of repetitive behaviour in autism. In: Russell, J., editor. *Autism as an executive disorder*. Oxford University Press; New York, NY: 1997. p. 57-100.
- Volkmar, F.; Klin, A. Kaplan and Sadock’s Comprehensive Textbook of Psychiatry. 7. Sadock, BJ.; Sadock, VA., editors. Lippincott Williams & Wilkins; Baltimore: 1999. p. 2659-2678.

- Weinstein M, Ben-Sira L, Levy Y, Zachor DA, Itzhak EB, Artzi M, Tarrasch R, Eksteine PM, Hendler T, Bashat DB. Abnormal white matter integrity in young children with autism. *Human Brain Mapping*. 2011; 32:534–543. [PubMed: 21391246]
- Welsh MC, Pennington BF, Groisser DB. A normative-developmental study of executive function: A window on prefrontal function in children. *Developmental Neuropsychology*. 1991; 7:131–149.
- Wolff JJ, Gu H, Gerig G, Elison JT, Styner M, Gouttard S, Botteron KN, Dager SR, Dawson G, Estes AM, Evans AC, Hazlett HC, Kostopoulos P, McKinsty RC, Paterson SJ, Schultz RT, Zwaigenbaum L, Piven J. Differences in White Matter Fiber Tract Development Present From 6 to 24 Months in Infants With Autism. *American Journal of Psychiatry*. 2012; 169:589–600. [PubMed: 22362397]

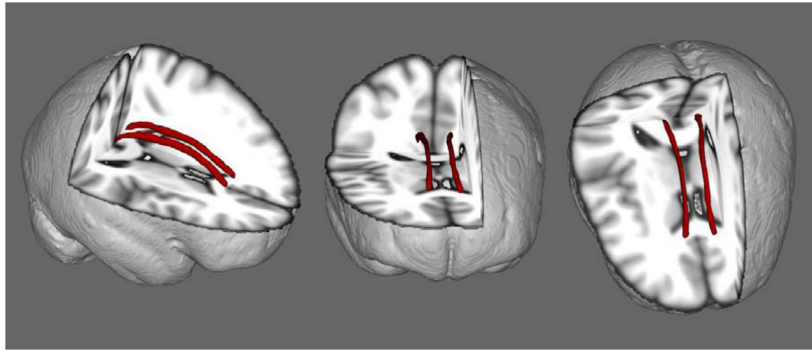


Figure 1.
3D Views of the Cingulum bundle as visualized with probabilistic tractography, averaged from all subjects and overlaid on the MNI152 T1 brain for display purposes.

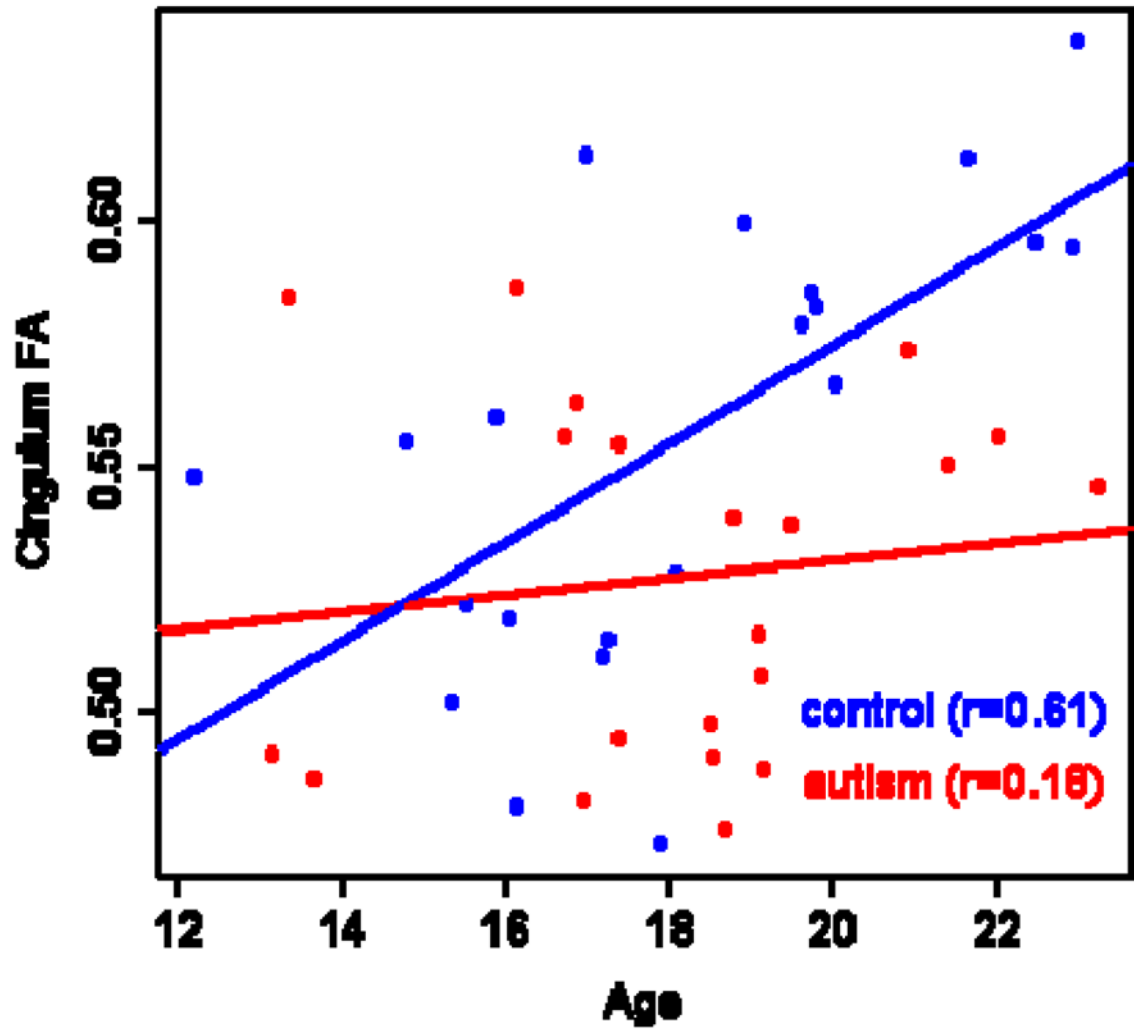


Figure 2. Cingulum bundle fractional anisotropy and age in autism and neurotypically developing groups

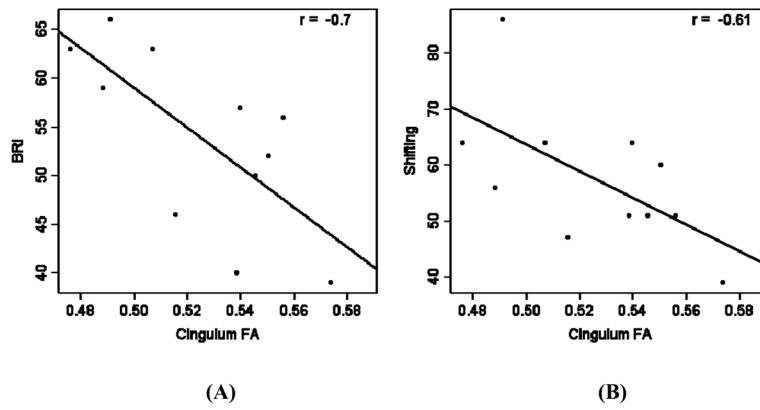


Figure 3. Cingulum bundle fractional anisotropy and performance on the BRI (Behavioral Regulation Index: A) and Shifting (B) indices of the BRIEF (Behavior Rating Inventory of Executive Function) T-scores

Table 1

Sample Characteristics

	ASD Group Mean (SD)	Control Group Mean (SD)	Statistic	df	p value
<i>N</i>	21	21			
Sex (M:F)	18:3	18:3			
Age	18.1 (2.7)	18.2 (2.9)	$T=0.053$	40	0.96
IQ ¹	96.62 (19.23)	110.29 (11.18)	$T=2.80$	40	0.008
BRIEF BRI²	53.73 (9.21)	7.14 (2.74)	$T=18.03$	23	<0.001
Emotional Control	52.91 (9.03)	13.00 (3.49)	$T=15.23$	23	<0.001
Inhibition	49.27 (8.04)	16.71 (3.05)	$T=11.97$	23	<0.001
Shifting	57.55 (12.36)	13.57 (4.15)	$T=12.51$	23	<0.001

¹FSIQ was estimated using the Wide Range Achievement Test in 9 neurotypical participants.

²Data obtained in 11 ASD and 14 neurotypical participants.