

2014

Complete binasal hemianopia

B. T. Bryan

H. D. Pomeranz

Hofstra Northwell School of Medicine

K. H. Smith

Follow this and additional works at: <https://academicworks.medicine.hofstra.edu/publications>



Part of the [Ophthalmology Commons](#)

Recommended Citation

Bryan B, Pomeranz HD, Smith K. Complete binasal hemianopia. . 2014 Jan 01; 27(4):Article 1698 [p.]. Available from: <https://academicworks.medicine.hofstra.edu/publications/1698>. Free full text article.

This Article is brought to you for free and open access by Donald and Barbara Zucker School of Medicine Academic Works. It has been accepted for inclusion in Journal Articles by an authorized administrator of Donald and Barbara Zucker School of Medicine Academic Works. For more information, please contact academicworks@hofstra.edu.

Complete binasal hemianopia

Beau T. Bryan, MD, Howard D. Pomeranz, MD, PhD, and Kyle H. Smith, MD

Binasal hemianopia is a rarely encountered visual field defect. We examined two asymptomatic female patients, aged 17 and 83, with complete binasal hemianopia. Both patients had unremarkable eye exams except for the visual field deficits and minimally reduced visual acuity and color vision. Both patients had normal neuroimaging. These are the first reported cases of complete binasal visual field defects without an identifiable ocular or neurologic cause.

Neuro-ophthalmologists rarely encounter patients with binasal (heteronymous) hemianopia. Several reports of incomplete binasal visual field defects have appeared (1–5). We found no reports, however, of complete binasal hemianopia. Here we present two cases of asymptomatic complete binasal hemianopia associated with minimally reduced visual acuity and color vision, but with otherwise unremarkable eye exams and neuroimaging.

CASE 1

A 17-year-old white female presented to the neuro-ophthalmology clinic for abnormal visual fields first detected by an outside optometrist at a regular vision check. She had no specific visual complaints and had noticed no recent changes in her vision. The provider performed a screening visual field exam, which demonstrated dense binasal hemianopia respecting the vertical meridian. She was referred to an ophthalmologist who repeated the visual field exam on multiple occasions. By the time she arrived for consultation in the neuro-ophthalmology clinic, she had undergone visual field testing 17 times. Every visual field test revealed the same pattern. Throughout this entire course she denied any visual problems. Her past medical and family history were only significant for obesity. Her best corrected visual acuity was 20/20 in the right eye and 20/25 in the left eye with a mild myopic astigmatism. Intraocular pressure was normal at 19 mm Hg OU. Hardy-Rand-Rittler color plate testing was subnormal, with 7 of 10 correct in the right eye and 7.5 of 10 correct in the left eye. Her pupils were normal without a relative afferent pupillary defect. Confrontation testing revealed a complete binasal hemianopia respecting the vertical midline. Repeat Humphrey 24-2 perimetry (Humphrey Field Analyzer, Carl Zeiss Meditec, Dublin, CA) again revealed

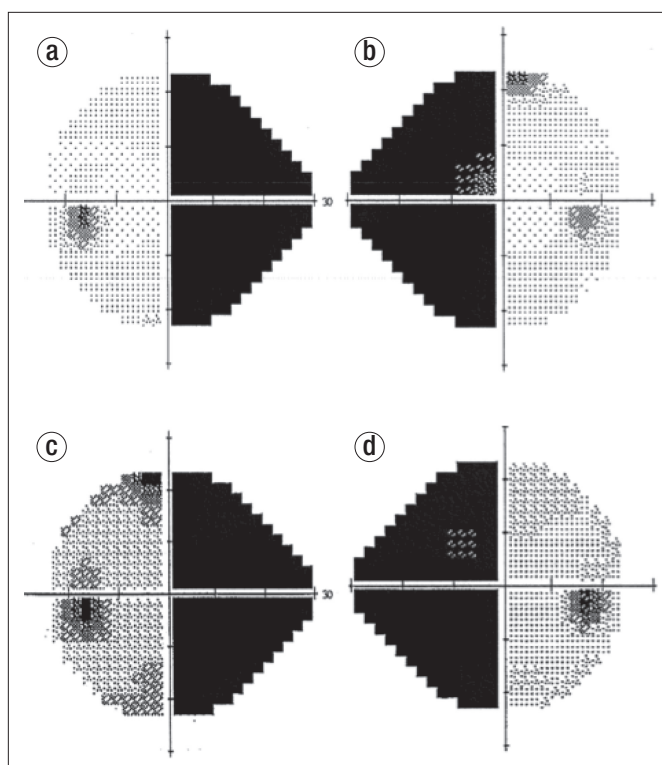


Figure 1. Humphrey 24-2 visual field in (a) case 1, left eye; (b) case 1, right eye; (c) case 2, left eye; (d) case 2, right eye.

a dense, complete binasal hemianopia that perfectly respected the vertical meridian (*Figure 1a, 1b*). Her anterior segment and funduscopy exams were completely normal except for a mild blurring of the superior margin of the left optic nerve without any other signs of active swelling. Spontaneous venous pulsations were readily visible. Red free photography revealed an intact nerve fiber layer verified by optical coherence tomography of the optic nerve head and retinal nerve fiber layer (OCT,

From the Department of Ophthalmology, Scott & White Eye Institute, Baylor Scott & White, Temple, Texas (Bryan, Smith); and the Department of Ophthalmology, Hofstra North Shore–Long Island Jewish School of Medicine, North Shore Long Island Jewish Health System, Great Neck, New York (Pomeranz).

Corresponding author: Beau T. Bryan, MD, Scott & White Eye Institute, 2401 South 31st Street, Temple, TX 76508 (e-mail: beau.bryan@gmail.com).

ONH, and RNFL Analysis, Carl Zeiss Meditec, Dublin, CA). Subsequent magnetic resonance (MR) imaging of the brain, with and without contrast, performed with attention directed toward the chiasm was normal.

CASE 2

An 83-year-old white woman presented to the neuro-ophthalmology clinic after an outside ophthalmologist noted binasal visual field deficits on confrontation testing. Humphrey 30-2 visual field testing documented a complete binasal hemianopia. The patient had a history of hypertension, but was otherwise healthy with a noncontributory family history. She had no visual complaints and specifically denied difficulty with her peripheral vision. Examination by the neuro-ophthalmologist revealed a best corrected visual acuity of 20/25 in each eye. Her pupillary exam was normal. Her intraocular pressures measured 18 and 15 mm Hg. Color vision testing was markedly abnormal. Her anterior segment exam was normal except for mild cataracts. Fundus examination revealed no optic atrophy or other optic disc abnormality and was otherwise unremarkable except for scattered peripheral drusen in both eyes. Repeat Humphrey 24-2 perimetry confirmed the same binasal defect (*Figure 1c, 1d*). Optical coherence tomography of the optic nerve head and retinal nerve fiber layer verified a normal nerve fiber layer in both eyes. Subsequent MR imaging and MR angiography studies of the head were entirely normal for her age.

DISCUSSION

In 1912 Harvey Cushing and C. B. Walker (1) reported “binasal hemianopsia” in a patient with a brain tumor. Ashwin and Quinlan (2) reported a single case due to keratoconus. Other reports of ocular and intracranial etiologies for binasal field defects include bilateral internal carotid artery aneurysms, hydrocephalus, intracranial mass lesions, and elevated intracranial pressure (2, 3). Pringle and colleagues (4) reported binasal hemianopia in a patient with neurosyphilis (*tabes dorsalis*). Salinas-Garcia and Smith reported 8 patients with incomplete binasal hemianopia in 1978. All eight patients had incomplete binasal visual field defects measured with Goldmann perimetry. All of their patients had identifiable causes, with most due to ocular or optic nerve etiologies including ischemic optic neuropathy, optic nerve head drusen, glaucoma, bilateral optic nerve pits, and retinitis pigmentosa sine pigmento (5).

Herein we present two patients, one in youth and one in older age, with complete binasal hemianopia without an identifiable ocular or intracranial etiology. Our patients were both visually asymptomatic. They were completely unaware of their visual field defects until the deficits were identified during routine eye exams. To our knowledge, these are the first reported cases of complete binasal hemianopia. Our examinations differ from prior reports in that automated perimetry was used rather than manual perimetry, as in prior series. We also recognize that our characterization of these visual field defects as “complete” is somewhat artificial. The defects appear to be complete on automated perimetry and with confrontation testing. Although both patients could have had some vision in their nasal hemi-

fields, these testing methods identified no visual responses in those areas, whereas the temporal fields were completely intact.

We considered the possibility of a functional (nonorganic) etiology for the field defects in our patients. However, neither patient complained of visual problems. These deficits were identified on routine eye exams. Neither patient appeared to have any secondary gain from the visual field defects. The younger patient (case 1) was actually quite annoyed that she had to endure so many eye exams and visual field tests. All she wanted was a new pair of glasses. She was greatly relieved when we recommended no further testing.

We do not believe these patients had retinal pathology that could explain their field defects. Other than scattered drusen in the peripheral retina of one patient, our cases had completely normal fundusoscopic examinations. We cannot conceive of a retinal problem that would cause such a profound bilateral nasal field defect with perfect respect of the vertical meridian and a completely normal fundusoscopic exam. Likewise, an optic neuropathy of any form is an unlikely explanation given the absence of visible optic atrophy and the intact nerve fiber layer in these patients. Both patients had subnormal visual acuity, although the older patient (case 2) had cataracts that easily explained her minimally reduced acuity. However, both patients also had subnormal color vision. This may have been an artifact of testing. Patients with homonymous hemianopia will often have subnormal color vision with standard testing methodologies. Our patients may have performed poorly simply as a result of the visual field deficit, not because of any true color vision abnormality. Neither patient had definitive evidence of optic neuropathy.

We propose a congenital etiology for these binasal visual field defects. Although we cannot prove that the field defects in our patients had been present from birth, the complete absence of symptoms strongly suggests a very longstanding problem. Patients with congenital homonymous hemianopia are often asymptomatic (6). Likewise, patients with other congenital field defects, such as the monocular altitudinal defects seen in patients with “topless disc syndrome,” are typically asymptomatic (7). Neuroimaging studies on our two patients revealed no identifiable abnormalities of the optic nerves, chiasm, postchiasmatic visual pathways, or occipital cortex. The binasal field defects could be due to a defect in the normal sorting and segregation of retinal ganglion axon populations that decussate and those that remain ipsilateral upon entering the optic chiasm from the optic nerves. Such sorting defects have been described in albinism, in which ipsilaterally destined temporal retinal fibers erroneously decussate and project contralaterally at the optic chiasm. But, this does not result in binasal hemianopia in human albinos. In achiasmatic syndrome, nasal retinal fibers fail to decussate adequately at the chiasm, projecting instead ipsilaterally towards the lateral geniculate nuclei together with temporal retinal fibers (8). Pomeranz and Lessell described a family in which there was a hereditary, probably autosomal recessive, chiasmatic optic neuropathy in which all of the siblings had bitemporal visual field defects (9). Our patients may represent examples of a congenital temporal retinal axon missorting syndrome. However,

the absence of optic atrophy suggests that the pathology likely resides along the postgeniculate visual pathways. The congenital defect seems to have resulted in a lack of cortical representation of the retinal ganglion cells from the temporal half of each retina. Whatever the neuroanatomic correlate may be, it results in isolated binasal visual field defects without identifiable structural abnormality of the optic chiasm, optic nerve, or postchiasmal visual pathways.

1. Cushing H, Walker CB. Distortions of the visual fields in cases of brain tumor (third paper): binasal hemianopsia. *Arch Ophthalmol* 1912;41:559–598.
2. Ashwin PT, Quinlan M. Interpreting binasal hemianopia: the importance of ocular examination. *Eur J Intern Med* 2006;17(2):144–145.
3. O’Connell JE, Du Boulay EP. Binasal hemianopia. *J Neurol Neurosurg Psychiatry* 1973;36(5):697–709.
4. Pringle E, Bingham J, Graham E. Progressive binasal hemianopia. *Lancet* 2004;363(9421):1606.
5. Salinas-Garcia RF, Smith JL. Binasal hemianopia. *Surg Neurol* 1978;10(3):187–194.
6. Shinder R, Wolansky L, Turbin RE. Congenital homonymous hemianopia and cortical migration abnormalities in a young adult. *J Pediatr Ophthalmol Strabismus* 2009;46(1):38–41.
7. Hashimoto M, Ohtsuka K, Nakagawa T, Hoyt WF. Topless optic disk syndrome without maternal diabetes mellitus. *Am J Ophthalmol* 1999;128(1):111–112.
8. Apkarian P. Chiasmal crossing defects in disorders of binocular vision. *Eye (Lond)* 1996;10(Pt 2):222–232.
9. Pomeranz HD, Lessell S. A hereditary chiasmal optic neuropathy. *Arch Ophthalmol* 1999;117(1):128–131.