

2015

# An Interesting Cause of Mechanical Small Bowel Obstruction

S. A. Sathyanarayana  
*Northwell Health*

G. B. Deutsch  
*Hofstra Northwell School of Medicine*

B. Friedman  
*Hofstra Northwell School of Medicine*

Follow this and additional works at: <https://academicworks.medicine.hofstra.edu/articles>

 Part of the [Surgery Commons](#)

---

## Recommended Citation

Sathyanarayana S, Deutsch G, Friedman B. An Interesting Cause of Mechanical Small Bowel Obstruction. . 2015 Jan 01; 77():Article 1920 [ p.]. Available from: <https://academicworks.medicine.hofstra.edu/articles/1920>. Free full text article.

This Article is brought to you for free and open access by Donald and Barbara Zucker School of Medicine Academic Works. It has been accepted for inclusion in Journal Articles by an authorized administrator of Donald and Barbara Zucker School of Medicine Academic Works.

## An Interesting Cause of Mechanical Small Bowel Obstruction

Sandeep Anantha Sathyanarayana · Gary B. Deutsch ·  
Barak Friedman

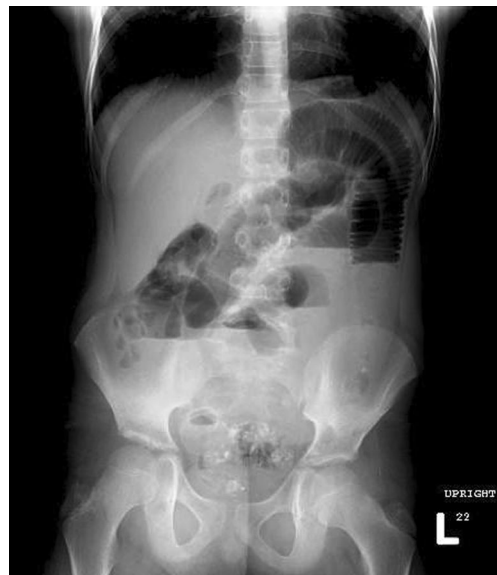Received: 9 January 2013 / Accepted: 28 January 2013 / Published online: 15 February 2013  
© Association of Surgeons of India 2013

**Abstract** Foreign body ingestion is a known cause of abdominal pain in pediatric population occurring between 6 months and 3 years of age (Wyllie Curr Opin Pediatr 18:563, 2006, Uyemura Am Fam Physician 72:287, 2005, Banerjee Indian J Pediatr 72:173, 2005). Most of the ingested foreign bodies pass spontaneously with 10–20 % requiring endoscopic retrieval, and <1 % of cases require a surgical intervention (Wyllie Curr Opin Pediatr 18:563, 2006, Uyemura Am Fam Physician 72:287, 2005, Shivakumar Indian J Pediatr 71:689, 2004). Presence of intestinal obstruction necessitates surgical intervention to extract the ingested foreign body. Initial abdominal plain radiograph should be obtained when foreign body ingestion is suspected, which differentiates a radiopaque from radiolucent foreign bodies. A computed tomography with 3D reconstruction (3D-CT) is recommended with radiolucent foreign bodies (Uyemura Am Fam Physician 72:287, 2005, Kazam Am J Emerg Med 23:897, 2005). After 24 h of expectant management, failure of spontaneous passage requires further intervention. Timely intervention to relieve the obstruction is pivotal to prevent undue complications. We present an interesting case of a boy who ingested a radiolucent foreign body diagnosed on 3D-CT, successfully treated with surgical extraction.

**Keywords** Foreign body · Pediatric bowel obstruction · Small bowel obstruction · Gastrointestinal foreign bodies · Radiolucent foreign body

### Case Report

A 9-year-old boy presents with non-projectile, bilious vomiting, and mid-abdominal pain. On examination, he was mildly dehydrated. His blood pressure was 130/70 mmHg, pulse of 100 beats/min, and temperature of 37 °C. Abdominal exam failed to reveal any peritoneal signs. Initial laboratory analysis showed leukocytosis to 12,000 cells/ $\mu$ l. An upright plain radiograph of the abdomen (Fig. 1)

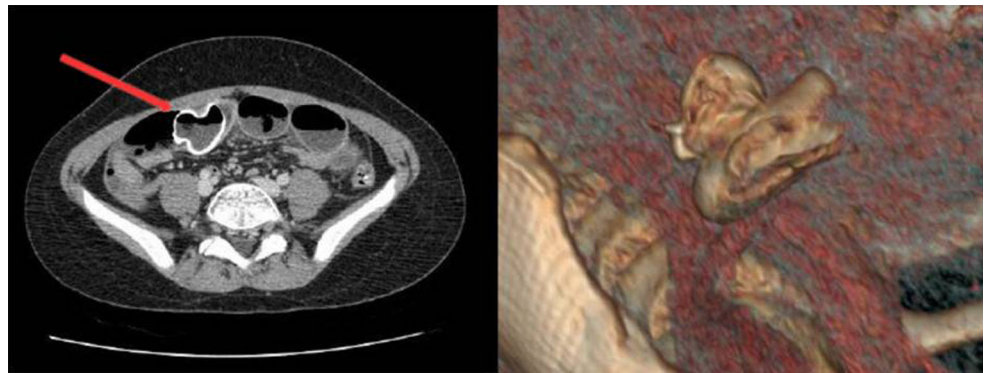


**Fig. 1** Upright plain radiograph demonstrating dilated loops of small bowel with differential air fluid levels

S. Anantha Sathyanarayana (✉) · G. B. Deutsch  
Department of Surgery, Hofstra-NSLIJ School of Medicine, 300  
Community Drive, Manhasset, NY 11030, USA  
e-mail: sanantha@nshs.edu

B. Friedman  
Department of Radiology, Hofstra-NSLIJ School of Medicine,  
Manhasset, NY, USA

**Fig. 2** Axial computed tomography with 3D reconstruction showing the rubber ducky. *Arrow* points to the transition point



demonstrated dilated small bowel loops with differential air fluid levels consistent with mechanical small bowel obstruction. An axial computed tomography image with 3D volume rendered reconstruction (Fig. 2) shows a “rubber ducky” as the transition point. Immediate laparotomy revealed the rubber ducky in the mid-small bowel. A longitudinal enterotomy was performed to milk the rubber ducky out and closed transversely. Post-operatively, he tolerated enteral nutrition and was discharged home.

## References

1. Wyllie R (2006) Foreign bodies in the gastrointestinal tract. *Curr Opin Pediatr* 18:563
2. Uyemura MC (2005) Foreign body ingestion in children. *Am Fam Physician* 72:287
3. Banerjee R, Rao GV, Sriram PV et al (2005) Button battery ingestion. *Indian J Pediatr* 72:173
4. Shivakumar AM, Naik AS, Prashanth KB et al (2004) Foreign body in upper digestive tract. *Indian J Pediatr* 71:689
5. Kazam JK, Coll D, Maltz C (2005) Computed tomography scan for the diagnosis of esophageal foreign body. *Am J Emerg Med* 23:897