

2015

FDG-PET-positive lower-extremity sebaceous-gland carcinoma in a patient with Muir-Torre syndrome

B. Kviatkovsky

E. Landau
Northwell Health

M. Siddique
Northwell Health

S. Hossri
Northwell Health

A. Ebaee
Northwell Health

See next page for additional authors

Follow this and additional works at: <https://academicworks.medicine.hofstra.edu/publications>

 Part of the [Radiology Commons](#)

Recommended Citation

Kviatkovsky B, Landau E, Siddique M, Hossri S, Ebaee A, Attalah J, Picon A, Brenner A. FDG-PET-positive lower-extremity sebaceous-gland carcinoma in a patient with Muir-Torre syndrome. . 2015 Jan 01; 10(2):Article 1927 [p.]. Available from: <https://academicworks.medicine.hofstra.edu/publications/1927>. Free full text article.

This Article is brought to you for free and open access by Donald and Barbara Zucker School of Medicine Academic Works. It has been accepted for inclusion in Journal Articles by an authorized administrator of Donald and Barbara Zucker School of Medicine Academic Works. For more information, please contact academicworks@hofstra.edu.

Authors

B. Kviatkovsky, E. Landau, M. Siddique, S. Hossri, A. Ebaee, J.P. Attalah, A. Picon, and A. Brenner

FDG-PET-positive lower-extremity sebaceous-gland carcinoma in a patient with Muir-Torre syndrome

Bina Kviatkovsky, MSc; Elliot Landau, MD; Muhammad Siddique, MBBS; Sami Hossri, MD; Anoosheh Ebaee, MD; Jean Paul Attalah, MD; Antonio Picon, MD; and Arnold Brenner, DO

Sebaceous-gland carcinoma can occur alone or as one of the defining features of the Muir-Torre syndrome. Cases occurring below the head and neck are extremely rare. Here we describe the case of a 70-year-old male with Muir-Torre syndrome who had a recurrent sebaceous-gland carcinoma in the left lower extremity that demonstrated ^{18}F -FDG avidity. An ^{18}F -FDG-avid lower-extremity sebaceous-gland carcinoma has not been previously reported.

Background

Sebaceous-gland carcinoma is a rare malignancy. It is listed as one of the defining features of the Muir-Torre syndrome (1). Sebaceous-gland carcinoma occurs in the periocular region in about three quarters of the patients. The majority of the extraocular cases arise in the head and neck region. Cases occurring below the head and neck are extremely rare and tend to have a higher chance of developing visceral malignancies, leading to poorer survival (1). The majority of the sebaceous-gland carcinoma cases associated with Muir-Torre syndrome actually occur outside the head and neck region, in most instances involving the torso and upper extremities (2). Although the FDG-avidity of sebaceous-gland carcinomas found in the head, neck, and breast region has been previously identified in case reports, this phenomenon is yet to be described in the lower extremity.

Case report

A 70-year-old Caucasian male with a known history of Muir-Torre syndrome presented with a recurrent lump in the medial aspect of his left calf. He had previously undergone a resection of sebaceous-gland carcinoma at this site. Manifestations of Muir-Torre syndrome in his case (besides the sebaceous-gland carcinoma) included mismatch repair-deficient cancer of the colon and urothelial cancer of the left renal pelvis, left ureter, and bladder for which he had undergone left-calf wide local excision, colon resection, transurethral resection of the bladder tumor, and left ureteronephrectomy. He reported cancer history in his uncle and father but could not recall the site or type. Medications included lorazepam, bupropion, seroquel, and trazodone for anxiety and depression. He was an ex-heavy smoker, but denied alcohol abuse or use of recreational drugs. Vital signs were stable.

The patient presented with a (third) recurrence of the sebaceous-gland carcinoma in the previously excised location. He was sent for an ^{18}F -FDG PET/CT scan to rule out new or recurrent visceral malignancies and to assess the regional nodal status and possibility of distant metastases. The noncontrast computerized tomographic (CT) scan demonstrated a 2.9 x 1.8 x 3.7-cm soft-tissue mass along the medial aspect of the left calf within the superficial subcutaneous soft tissues (Fig. 1). The ^{18}F -FDG PET scan revealed intense pathologic uptake (SUVmax 9.1) coregistering with this mass, consistent with biologic tumor activity. There were no other sites of abnormal ^{18}F -FDG uptake (Figs. 2 and 3). The patient underwent a radical excision of the lesion with sentinel lymph node lymphoscintigraphy and biopsy, followed by reconstructive surgery with placement of a skin graft. Histopathology

Citation: Kviatkovsky B, Landau E, Siddique M, Hossri S, Ebaee A, Attalah JP, Picon A, Brenner A. FDG-PET-positive lower-extremity sebaceous-gland carcinoma in a patient with Muir-Torre syndrome. *Radiology Case Reports*. (Online) 2015;10(2):1115

Copyright: © 2015 The Authors. This is an open-access article distributed under the terms of the Creative Commons Attribution-NonCommercial-NoDerivs 2.5 License, which permits reproduction and distribution, provided the original work is properly cited. Commercial use and derivative works are not permitted.

Ms. Kviatkovsky is at the Touro College of Osteopathic Medicine, New York, NY. Drs. Landau, Siddique, Hossri, Ebaee, Attalah, Picon, and Brenner are all at the Staten Island University Hospital, Staten Island, NY. Contact Dr. Landau at elliottlandau2@gmail.com.

Competing Interests: The author has declared that no competing interests exist.

DOI: 10.2484/rcr.v10i2.1115

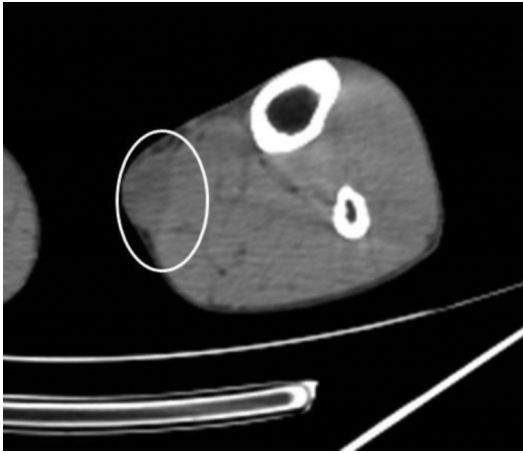


Fig. 1: Lower-extremity noncontrast, low-dose axial CT image of lower extremities demonstrates 2.9 x 1.8 x 3.7-cm soft-tissue mass along medial aspect of left calf within the superficial subcutaneous soft tissues. The longest diameter in the coronal plane is 3.6 cm, in the sagittal plane 3.6 cm, and in the transaxial 3.2 cm.

confirmed a sebaceous-gland carcinoma measuring 6.8 x 5.5 x 2.0 cm that was 0.25 mm from the deep (closest) surgical margin. All margins and sentinel lymph nodes proved negative for carcinoma. The tumor mass was diagnosed as low-grade sebaceous-gland carcinoma (T2N0). The tumor was a nonencapsulated, infiltrative neoplasm composed of atypical epithelial cells with sebaceous differentiation, the latter with vacuolated cytoplasm and prominent nuclei, and

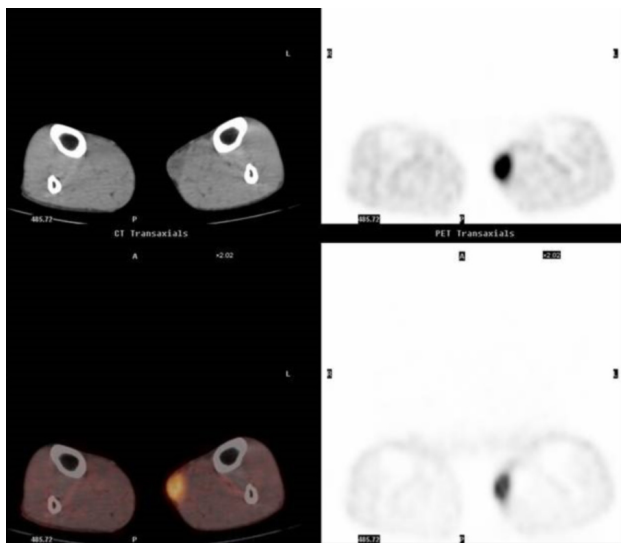


Fig. 2: Coregistration of transaxial CT images with ¹⁸FDG PET images. Intense pathological FDG uptake (SUV 9.1) is present on initial ¹⁸FDG PET examination coregistering with superficial soft-tissue mass, consistent with biologic tumor activity.

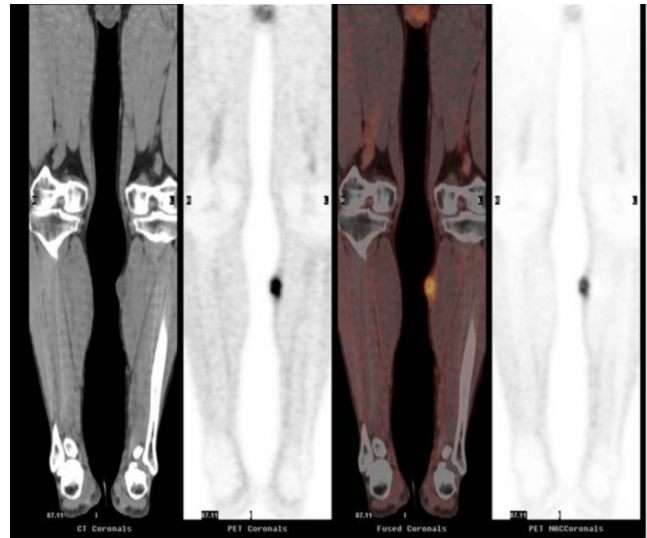


Fig. 3: Coregistration of coronal CT Images with ¹⁸FDG PET image. Intense pathological FDG uptake (SUV 9.1) is present on initial ¹⁸FDG PET examination coregistering with superficial soft-tissue mass, consistent with biologic tumor activity.

displayed significant necrosis and mitoses. However, perineural or vascular invasion was not seen (Fig. 4).

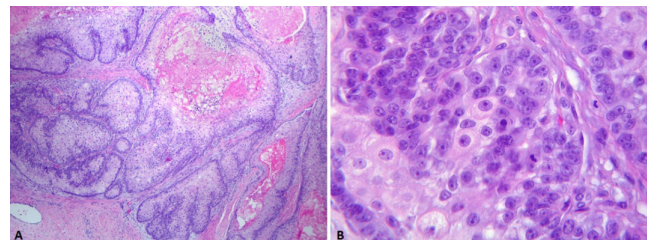


Fig. 4: Pathological specimen. A. Well-differentiated sebaceous carcinoma composed of lobules and sheets of tumor cells with central necrosis (40 X). B. Individual cells have distinct cell membranes, clear to vacuolated cytoplasm, vesicular nuclei with prominent nucleoli and mitotic figures (400X).

About a month after resection, a postoperative irradiation course was directed to the resection site and a small margin, with a total dose of 50 Gy in 25 treatments using a prescription isodose line of 90% with a 0.5 cm bolus.

A total-body ¹⁸F-FDG PET- CT scan three months postirradiation did not reveal any residual disease (Fig. 5), and the patient remains disease-free to date.

Discussion

Sebaceous-gland carcinoma is an uncommon and aggressive malignancy (1). The malignant cell of origin is derived from the adnexal epithelium (1). The etiology of

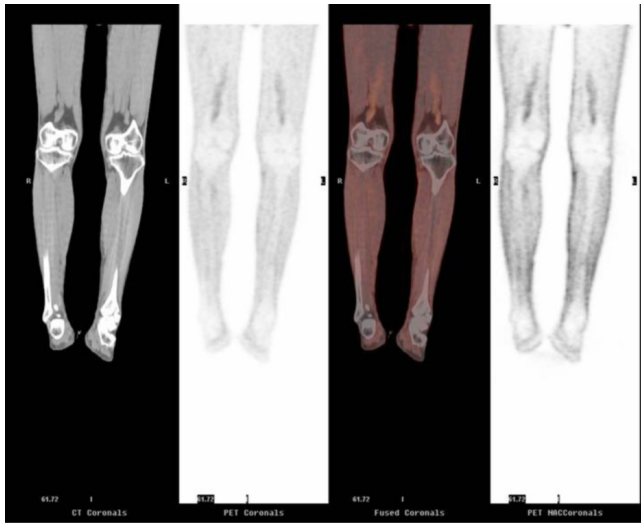


Fig. 5. Subsequent coregistered ¹⁸FDG PET CT coronal image post excision and radiotherapy shows no residual areas of abnormal ¹⁸FDG uptake consistent with good treatment response.

sebaceous-gland carcinoma is not entirely understood. Rare cases are associated with familial genetic disorders. The median age at diagnosis is 72, and it is somewhat more prevalent in Caucasian men (3). Several risk factors for the development of sebaceous-gland carcinoma have been proposed in various studies, including radiotherapy in children with retinoblastoma, infection with high-risk human papilloma virus, and the overexpression of p53 (4). Rare cases of sebaceous-gland carcinoma are associated with Muir-Torre syndrome. The diagnostic criterion for Muir-Torre syndrome requires the presence of at least one visceral malignancy along with a sebaceous neoplasm (3), without having an environmental risk factor for sebaceous neoplasm. Of all sebaceous neoplasms, cutaneous sebaceous adenoma is the one most common encountered in Muir-Torre syndrome (5). Sebaceous-gland carcinoma is found only in 23% of cases of Muir-Torre syndrome (14). The development of sebaceous neoplasms in Muir-Torre syndrome is related to a defective DNA mismatch-repair (MMR) system that leads to unchecked genetic aberrations, including loss of tumor suppressor genes (6). Inactivation of both alleles of an MMR gene as a result of highly penetrant autosomal dominant mutations, most commonly in MLH1 and/or MSH2 genes, leads to defective mismatch repair, resulting in microsatellite instability (MSI). This MSI can result in frameshift mutations within the microsatellites containing tumor-suppressor genes (6). These mutations may interfere with gene-splicing sites, eventually leading to loss of tumor-suppressor proteins (2).

The MMR status may have a correlation with the site of development of sebaceous-gland carcinoma. Although the majority of cases affect the head and neck region, Singh et al (2), found that 92% of the sebaceous tumors occurring in MMR-deficient patients, like our patient, occur outside the

head and neck region, mainly in the trunk or upper extremities. However, what is unusual and thus interesting in our case of sebaceous-gland carcinoma associated with Muir-Torre syndrome is the involvement of the lower limb. A literature search found only 24 cases of sebaceous-gland carcinoma involving the lower extremity, leading to the conclusion that a primary sebaceous-gland carcinoma in this region is a novel discovery (1). One case of sebaceous-gland carcinoma was reported in the left popliteal fossa (7), while another manuscript reported sebaceous-gland carcinoma presenting as multiple ulcerated nodules and papules on the leg of a 32-year-old male (8). Even more interesting is the fact that none of these 24 cases were described to be associated with Muir-Torre syndrome.

Another intriguing aspect of this case is the FDG positivity of the lower-extremity sebaceous-gland carcinoma. ¹⁸FDG PET/CT has become a significant tool in cancer imaging for diagnosis, staging, and evaluation of treatment response. In the case of sebaceous-gland carcinoma, the rate of nodal and distant metastatic disease approaches about 25% (9), and thus ¹⁸FDG PET/CT may have a potential role in precisely defining the disease stage. However, as sebaceous-gland carcinoma is rare, there is very limited literature published on the utility of ¹⁸FDG PET/CT in sebaceous-gland carcinoma, and it is composed only of case reports that describe a handful of cases. Baek et al. described 5 cases of periocular sebaceous-gland carcinoma in which ¹⁸FDG PET/CT scan correctly identified 4 of 4 cases of regional lymph-node involvement, whereas 3 of these 4 were undetected with CT alone (10). Krishna et al. described two cases of ocular sebaceous-gland carcinoma that were successfully staged with ¹⁸FDG PET/CT (11). In one case, pathological FDG uptake was noted in submandibular, supraclavicular, mediastinal, and retroperitoneal lymph nodes (11).

There are even fewer reports describing use of ¹⁸FDG PET/CT in extraocular sebaceous-gland carcinoma. Bongu et al. described a case of a biopsy-proven recurrent 9-cm sebaceous-gland carcinoma on the back of a 47-year-old male that was intensely FDG-avid, with no other sites of abnormal ¹⁸FDG uptake (12). Until now, only one published report describes a case of an FDG-avid upper-extremity sebaceous-gland carcinoma. In this case of a 70-year-old female with an enlarging upper-arm sebaceous-gland carcinoma, bone scintigraphy demonstrated increased uptake in a large mass in the proximal humerus with central photopenia. The ¹⁸FDG PET/CT scan additionally found distal disease, undetected by other imaging studies. This included left-lung metastases as well as left sacroiliac articulation (13).

As up to a third of patients may experience recurrence post surgery despite excision with clear tumor margins of 5 to 6 mm (14), radiotherapy is often employed, even though no comparison of postoperative irradiation with surgery alone has been done (3). We also treated our patient with a course of postoperative radiotherapy, and he remains without recurrence to date.

FDG-PET-positive lower-extremity sebaceous-gland carcinoma in a patient with Muir-Torre syndrome

To conclude, a novel presentation of recurring sebaceous-gland carcinoma of the lower extremity (shown to be FDG-avid) was seen in a male patient with Muir-Torre syndrome. Multiple surgeries and radiotherapy were required to successfully treat the sebaceous-gland carcinoma as confirmed (post treatment) with ¹⁸F-FDG PET/CT scan, which demonstrated resolution to a non-¹⁸F-FDG-avid status. To our knowledge, sebaceous-gland carcinomas have rarely been reported in the extremities (especially the lower extremity). Moreover, we present the first case of an ¹⁸F-FDG-avid sebaceous-gland carcinoma of the lower extremity.

References

1. Gavriilidis, P., et al., Extraocular sebaceous carcinoma mimicking benign sebaceous cyst. *BMJ Case Rep*, 2013. 2013. [PubMed]
2. Singh, R.S., et al., Site and tumor type predicts DNA mismatch repair status in cutaneous sebaceous neoplasia. *Am J Surg Pathol*, 2008. 32(6): p. 936-42. [PubMed]
3. Dasgupta, T., L.D. Wilson, and J.B. Yu, A retrospective review of 1349 cases of sebaceous carcinoma. *Cancer*, 2009. 115(1): p. 158-65. [PubMed]
4. Cieza-Diaz, D.E., et al., Extraocular sebaceous carcinoma: a report of 2 cases. *Actas Dermosifiliogr*, 2012. 103(10): p. 919-22. [PubMed]
5. Lachiewicz A, Wilkinson T, Groben P, Ollila DV, Thomas NE. Muir-Torre syndrome. *Am J Clin Dermatol*. 2007;8:315-9. [PubMed]
6. Kleinerman, R., J. Marino, and E. Loucas, Muir-Torre Syndrome / Turcot Syndrome overlap? A patient with sebaceous carcinoma, colon cancer, and a malignant astrocytoma. *Dermatol Online J*, 2012. 18(5): 3. [PubMed]
7. Imakado, S., K. Hamada, and K. Miura, Low-grade sebaceous carcinoma presenting on the leg. *Am J Dermatopathol*, 2008. 30(6): p. 608-11. [PubMed]
8. Bhat, I.P., et al., Multifocal extra-ocular sebaceous carcinoma. *Indian J Dermatol Venereol Leprol*, 2011. 77(3): p. 403. [PubMed]
9. Nelson BR, Hamlet KR, Gillard M, Railan D, Johnson TM. Sebaceous carcinoma. *J Am Acad Dermatol* 1995;33:1-15; 16-18. [PubMed]
10. Baek CH, Chung MK, Jeong HS, Son YI, Choi J, Kim YD, et al. The clinical usefulness of (18)F-FDG PET/CT for the evaluation of lymph node metastasis in periorbital malignancies. *Korean J Radiol* 2009;10(1):1-7. [PubMed]
11. Krishna SM, Finger PT, Chin K, Lacob CE. 18-FDG PET/CT staging of ocular sebaceous cell carcinoma. *Graefes Arch Clin Exp Ophthalmol*. 2007; 245:759-60. [PubMed]
12. Bongu A, Lee ES, Peters SR, Chokshi RJ. Locally Aggressive and Multicentric Recurrent Extraocular Sebaceous Carcinoma: Case Report and Literature Review. *Eplasty*. 2013; 13: 368-374. [PubMed]
13. Herceg D, Kusacić-Kuna S, Dotlić S, Petrović R, Bračić I, Horvatić Herceg G, Plestina S. F-18 FDG PET evaluation of a rapidly growing extraocular sebaceous carcinoma. *Clin Nucl Med*. 2009; 34:798-801. [PubMed]
14. Spencer JM, Nossa R, Tse DT, Sequeira M. Sebaceous carcinoma of the eyelid treated with Mohs micrographic surgery. *J Am Acad Dermatol*. 2001;44:1004-9. [PubMed]