

2015

## Respiratory failure with hilar mass: Role of endobronchial ultrasound-guided transbronchial needle aspiration in the medical intensive care unit

A. Chichra  
*Northwell Health*

K. W. Lama  
*Northwell Health*

S. J. Koenig  
*Zucker School of Medicine at Hofstra/Northwell*

Follow this and additional works at: <https://academicworks.medicine.hofstra.edu/publications>



Part of the [Critical Care Commons](#), and the [Pulmonology Commons](#)

---

### Recommended Citation

Chichra A, Lama K, Koenig SJ. Respiratory failure with hilar mass: Role of endobronchial ultrasound-guided transbronchial needle aspiration in the medical intensive care unit. . 2015 Jan 01; 32(2):Article 2038 [ p.]. Available from: <https://academicworks.medicine.hofstra.edu/publications/2038>. Free full text article.

This Article is brought to you for free and open access by Donald and Barbara Zucker School of Medicine Academic Works. It has been accepted for inclusion in Journal Articles by an authorized administrator of Donald and Barbara Zucker School of Medicine Academic Works. For more information, please contact [academicworks@hofstra.edu](mailto:academicworks@hofstra.edu).



Lung India. 2015 Mar-Apr; 32(2): 178–181.

PMCID: PMC4372877

doi: [10.4103/0970-2113.152647](https://doi.org/10.4103/0970-2113.152647)

## Respiratory failure with hilar mass: Role of endobronchial ultrasound-guided transbronchial needle aspiration in the medical intensive care unit

[Astha Chichra](#), [Kimmoi Wong Lama](#), and [Seth J. Koenig](#)

*Department of Internal Medicine, Division of Pulmonary and Critical Care Medicine, Hofstra North Shore - Long Island Jewish Health System, New York, United States*

**Address for correspondence:** Dr. Astha Chichra, Pulmonary, Critical Care and Sleep Medicine, 410 Lakeville Road, Suite 107, New Hyde Park, New York - 11042, United States. E-mail: [drasthachichra@gmail.com](mailto:drasthachichra@gmail.com)

Copyright : © Lung India

This is an open-access article distributed under the terms of the Creative Commons Attribution-Noncommercial-Share Alike 3.0 Unported, which permits unrestricted use, distribution, and reproduction in any medium, provided the original work is properly cited.

### Abstract

We report the case of a 58-year-old man on chronic steroid therapy, who developed a rapidly progressive right upper lobe infiltrate/mass that extended into the right hilum. Respiratory failure necessitated endotracheal intubation. Broad spectrum antibiotics were initiated without clinical improvement and because of his immunosuppressive therapy opportunistic pathogens were considered. Endobronchial ultrasound-guided transbronchial needle aspiration (EBUS-TBNA) was performed in the Medical Intensive Care Unit (MICU) with rapid onsite evaluation. Specimens obtained from the right hilar mass revealed organisms suspicious for cryptococcal infection, subsequently confirmed via a culture. No complications occurred during the EBUS procedure despite the patient requiring vasopressor support and 100% inspired oxygen. Little data exists regarding the use of EBUS in patients admitted to the MICU with respiratory failure of unknown etiology and mediastinal/hilar lymphadenopathy. This case illustrates the potential safe use of EBUS-TBNA in patients presenting with respiratory failure, with a mediastinal or hilar mass and suspected infectious etiology.

**KEY WORDS:** Cryptococcosis, endobronchial ultrasound, hilar mass, mediastinal lymphadenopathy, respiratory failure, trans bronchial needle aspiration

### INTRODUCTION

Cryptococcosis is a potentially fatal fungal disease. It is caused by inhalation of cryptococcal spores. Cryptococcus causes mainly three types of infections: Cutaneous or wound cryptococcosis, pulmonary cryptococcosis, and meningoencephalitis.[1,2] The spectrum of pulmonary manifestations may range from asymptomatic pulmonary infection in immunocompetent patients to diffuse pulmonary disease, leading to respiratory failure in the immunocompromised host.[3] In one study, 92% of the patients with pulmonary cryptococcosis had an underlying illness predisposing them to the development of this disease.[4] Cryptococcosis is an acquired immunodeficiency syndrome (AIDS) defining infection seen in patients with human immunodeficiency virus (HIV) infection. However, as illustrated in this case, *Cryptococcus* is also on the rise in non-HIV infected patients owing to the increased use of high-dose corticosteroids and other immunosuppressive agents for malignancy or post organ transplant. In this report, we discuss the potential role of endobronchial ultrasound-guided transbronchial needle aspiration (EBUS-TBNA) in

respiratory failure cases due to an unknown etiology and enlarged hilar/mediastinal lymph nodes or masses.

## CASE REPORT

---

A 58-year-old man was admitted to our Hospitalist Services for medical management of acute small bowel obstruction, which improved. Subsequently, the patient developed diffuse body aches, generalized weakness, and was noted to have a cough with blood-tinged sputum. The Pulmonary Service was consulted for evaluation of this new onset of hemoptysis. His past medical history was significant for underlying diabetes mellitus managed on oral hypoglycemics, end-stage renal disease on hemodialysis, systemic hypertension, Hepatitis C with associated vasculitis, for which he was on chronic oral steroid therapy. He denied any oral or intravenous substance abuse, tobacco smoking or alcohol use.

Our initial physical assessment revealed normal vital signs without any obvious respiratory distress. His pulse oximetry showed 98% saturation on room air. His eyes were anicteric and neck was supple with no jugular venous distention. Chest auscultation was unremarkable for any extra cardiac or respiratory sounds. The abdominal examination was significant for mild distention with normal bowel sounds. The neurological exam was abnormal and revealed decreased muscle strength throughout, with intact sensations and normal deep tendon reflexes.

A review of laboratory investigations revealed mild leukocytosis without leftward shift or bandemia. The serum chemistry showed an elevated serum creatinine level and a normal serum bicarbonate level as well as mildly elevated liver enzymes (AST- 110 IU/L, ALT- 42 IU/L and ALP-IU/L, a low albumin level, and normal bilirubin level). A room air arterial blood gas was obtained, which revealed no metabolic or respiratory abnormality. A chest radiograph showed a patchy infiltrate in the right lower lung. A computed tomogram (CT) of the chest, without contrast study, was obtained, which showed a 3.3 centimeter (cm) ×3.3 cm right hilar mass scattered bilateral pleural nodules, and bilateral pleural effusions [Figure 1]. A short interval repeat CT chest with contrast was done to evaluate this mass. This repeat study showed a significant increase in the hilar mass, 5.5 cm in maximum dimension and increasing bilateral pleural nodules. A 1.4 cm right lower paratracheal and 1.6 cm subcarinal lymph nodes were also noted [Figures 2 and 3].

On account of this rapid expansion of the hilar mass, an underlying infectious etiology was suspected and accordingly the patient was started on broad-spectrum antibiotics. A decision was made to perform EBUS-guided TBNA of the right hilar mass. However, the patient deteriorated rapidly and became progressively delirious over the next 24 hours requiring transfer to the Medical Intensive Care Unit (MICU) for acute respiratory failure, necessitating endotracheal intubation. While in the MICU, he underwent bedside EBUS-TBNA through an 8.0 mm endotracheal tube. The right hilar lymph node (station 10R) was sampled; transbronchial biopsies and bronchoalveolar lavage were performed at the right upper lobe. Rapid onsite cytology showed evidence of fungal elements. The patient was started on an intravenous antifungal agent. As part of the delirium workup, a spinal tap was also performed. The opening pressure was noted to be elevated at 28 cm of water. A cytopathology report from the right hilar lymph node showed a large burden of fungal organisms with thick capsules and tear drop budding consistent with the *Cryptococcus* genus [Figures 4 and 5]. Bronchoalveolar lavage (BAL) showed evidence that *Cryptococcus* and cerebrospinal fluid (CSF) cultures grew *Cryptococcus neoformans*. Serum cryptococcal antigen was elevated at a titer of 1:512.

The patient continued to rapidly deteriorate with multiorgan failure requiring vasopressor support, mechanical ventilation, and renal replacement therapy; and he expired after two weeks.

## DISCUSSION

---

There are wide variations in the radiological findings of pulmonary cryptococcosis. These variations are largely influenced by the underlying immune status of the patient.[5] Masses, large alveolar consolidation, lymphadenopathy, pleural effusions, and areas of cavitation are infrequently reported.[6] Pulmonary nodules are the most common CT findings in immunocompetent patients with pulmonary cryptococcosis. Cryptococcal lymphadenopathy with interstitial infiltrates is the most common reported finding in immunocompromised patients.[7,8] In cryptococcal lymphadenitis, usually, mediastinal lymph nodes are affected and are generally <1.5 cm.[9] Diagnosis of pulmonary cryptococcosis is based on the isolation of cryptococcal filaments or detection of cryptococcal antigen in a pulmonary specimen obtained by TBNA or BAL during bronchoscopy. There are a handful of case reports on EBUS-TBNA-diagnosed cases of tuberculosis, nocardiosis, histoplasmosis, and blastomycosis.[10] However, there is paucity of literature on the diagnosis of pulmonary cryptococcosis using EBUS-TBNA.

Traditionally, EBUS-TBNA has been used for staging and diagnosing lung cancer by mediastinal lymph node aspiration, with some recent reports of its utility in diagnosing benign conditions, for example, sarcoidosis and infections.[11,12] In this case, we opted for EBUS-guided TBNA over conventional TBNA due to a higher yield-in randomized trials. Herth *et al.*[13] compared the results of an EBUS-guided TBNA compared with the conventional TBNA and found that the yield of an EBUS-guided TBNA was significantly higher than that of the conventional TBNA (85 vs. 66%). Using EBUS-TBNA with a designated 22-gauge needle, both histological and cytological specimens could be obtained, along with specimens for a microbiological culture.[14,15] A histological specimen aids in excluding other causes of mediastinal lymphadenopathy, such as, sarcoidosis, as well as minimizes the risk of false-positive microbiological results from contamination by airway colonization. EBUS-TBNA is a safe procedure with relatively lower adverse risks. Local mediastinal infections and systemic dissemination have been reported, however, it is very rare.[16,17,18]

The addition of rapid on-site evaluation (ROSE) of the transbronchial aspirates by a cytopathologist present during the procedure helps in improving the yield of the specimens. It provides the advantage of reducing the incidence of inadequate specimens needed for diagnostic purposes.[19,20] It also helps provide a provisional diagnosis at the bedside, as demonstrated by our case above.

There is also utility of a combined EBUS and Endoscopic Ultrasound (EUS)-guided fine needle aspiration approach for evaluating mediastinal lymphadenopathy, in particular benign mediastinal lymphadenopathy.[21] Herth *et al.*[22] have demonstrated that a combined esophageal and bronchoscopic endoscopic staging, using a single, linear ultrasound bronchoscope is feasible, safe, and has a higher yield than either approach alone. There may be a special role of this combined approach in cases like ours, with benign mediastinal lymphadenopathy, particularly if the target is a paraesophageal lymph node.[23]

Our case illustrates that EBUS-TBNA provides a safe diagnostic tool with the potential for rapid bedside diagnosis. This may affect therapeutic plans, especially in patients with suspected infection and respiratory failure, with mediastinal or hilar lymphadenopathy or masses.

## Footnotes

---

**Source of Support:** Nil

**Conflict of Interest:** None declared.

## REFERENCES

---

1. Hajjeh RA, Brandt ME, Pinner RW. Emergence of cryptococcal disease: Epidemiologic perspectives 100 years after its discovery. *Epidemiol Rev.* 1995;17:303–20. [PubMed: 8654513]
2. Fraser RG, Pare JA, Pare PD, Fraser RS, Genereux GP. 3rd ed. Philadelphia: Saunders; 1989. *Diagnosis of Diseases of the Chest*; pp. 975–85.

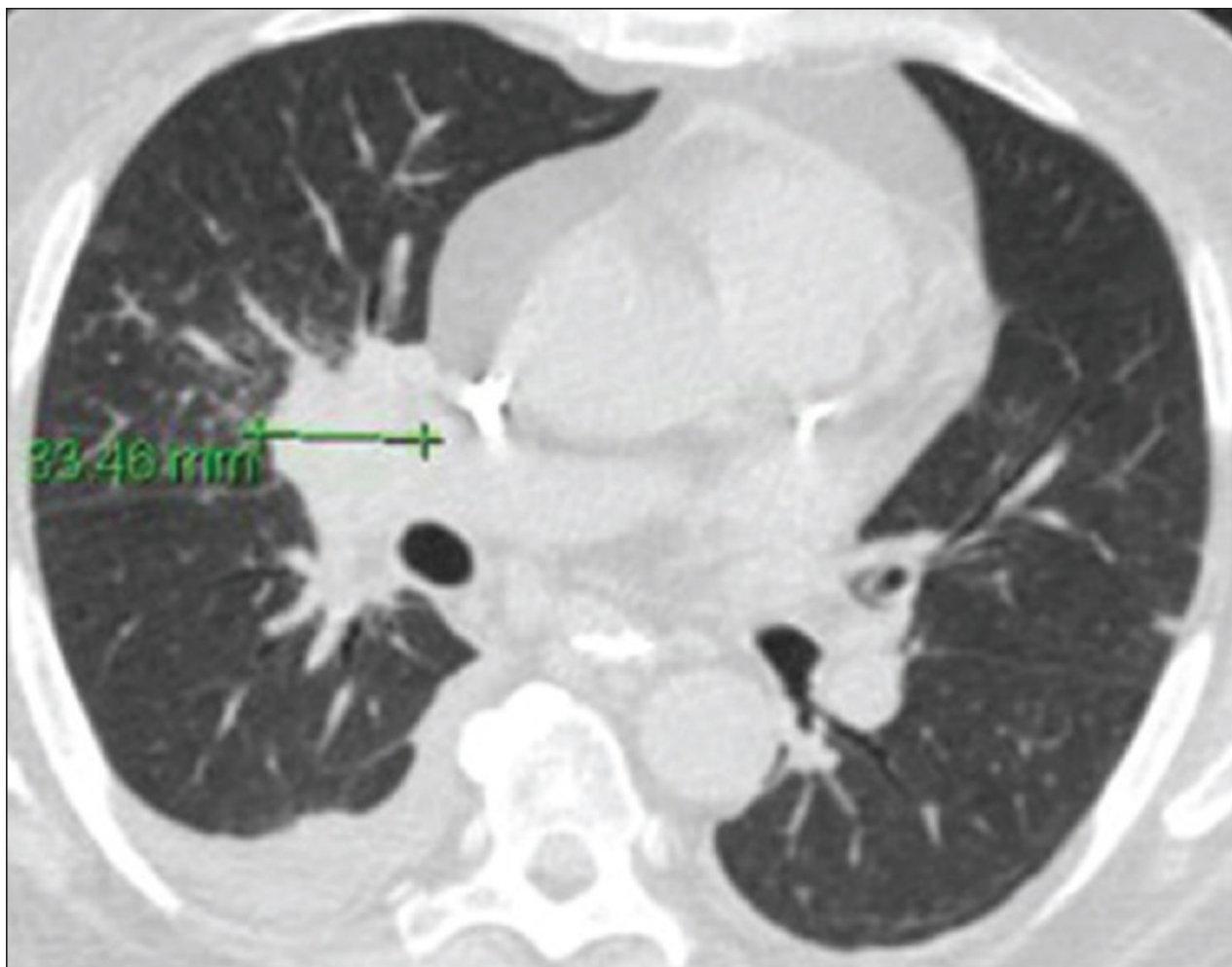
3. Chang WC, Tzao C, Hsu HH, Lee SC, Huang KL, Tung HJ, et al. Pulmonary cryptococcosis: Comparison of clinical and radiographic characteristics in immunocompetent and immunocompromised patients. *Chest*. 2006;129:333–40. [PubMed: 16478849]
4. McDonnell JM, Hutchins GM. Pulmonary cryptococcosis. *Hum Pathol*. 1985;16:121–8. [PubMed: 3972394]
5. Jarvis JN, Harrison TS. Pulmonary cryptococcosis. *Semin Respir Crit Care Med*. 2008;29:141–50. [PubMed: 18365996]
6. Lindell RM, Hartman TE, Nadrous HF, Ryu JH. Pulmonary cryptococcosis: CT Findings in immunocompetent patients. *Radiology*. 2005;236:326–31. [PubMed: 15987984]
7. Witt D, McKay D, Schwam L, Goldstein D, Gold J. Acquired immune deficiency syndrome presenting as bone marrow and mediastinal cryptococcosis. *Am J Med*. 1987;82:149–50. [PubMed: 3799674]
8. Miller WT, Jr, Edelman JM, Miller WT. Cryptococcal pulmonary infection in patients with AIDS: Radiographic appearance. *Radiology*. 1990;175:725–8. [PubMed: 2343121]
9. Lacomis JM, Costello P, Vilchez R, Kusne S. The radiology of pulmonary cryptococcosis in a tertiary medical center. *J Thorac Imaging*. 2001;16:139–48. [PubMed: 11428412]
10. Fujikura Y, Kouzaki Y, Ohta S, Hara Y, Mikita K, Maeda T, et al. A case of nocardia asteroides infection in a patient with HIV/AIDS diagnosed by endobronchial ultrasound-guided transbronchial needle aspiration (EBUS-TBNA) *Intern Med*. 2012;51:1413–7. [PubMed: 22687853]
11. Nakajima T, Yasufuku K, Kurosu K, Takiguchi Y, Fujiwara T, Chiyo M, et al. The role of EBUS-TBNA for the diagnosis of sarcoidosis--comparisons with other bronchoscopic diagnostic modalities. *Respir Med*. 2009;103:1796–800. [PubMed: 19674882]
12. Lin SM, Chung FT, Huang CD, Liu WT, Kuo CH, Wang CH, et al. Diagnostic value of endobronchial ultrasonography for pulmonary tuberculosis. *J Thorac Cardiovasc Surg*. 2009;138:179–84. [PubMed: 19577076]
13. Herth F, Becker HD, Ernst A. Conventional vs endobronchial ultrasound-guided transbronchial needle aspiration: A randomized trial. *Chest*. 2004;125:322–5. [PubMed: 14718460]
14. Cetinkaya E, Yildiz P, Altin S, Yilmaz V. Diagnostic value of transbronchial needle aspiration by Wang 22-gauge cytology needle in intrathoracic lymphadenopathy. *Chest*. 2004;125:527–31. [PubMed: 14769734]
15. Yarmus LB, Akulian J, Lechtzin N, Yasin F, Kamdar B, Ernst A, et al. American College of Chest Physicians Quality Improvement Registry, Education, and Evaluation (AQUIRE) Participants. Comparison of 21-gauge and 22-gauge aspiration needle in endobronchial ultrasound-guided transbronchial needle aspiration: Results of the American College of Chest Physicians Quality Improvement Registry, Education, and Evaluation Registry. *Chest*. 2013;143:1036–43. [PMCID: PMC4694078] [PubMed: 23632441]
16. Huang Ct, Chen CY, Ho CC, Yu CJ. A rare constellation of empyema, lung abscess, and mediastinal abscess as a complication of endobronchial ultrasound-guided transbronchial needle aspiration. *Eur J Cardiothorac Surg*. 2011;40:264–5. [PubMed: 21183356]
17. Kouskov OS, Almeida FA, Eapen GA, Uzbek M, Deffebach M. Mediastinal infection after ultrasound guided needle aspiration. *J Bronchology Interv Pulmonol*. 2010;17:338–41. [PubMed: 23168957]
18. Steinfort DP, Johnson DF, Irving LB. Incidence of bacteremia following endobronchial ultrasound-guided transbronchial needle aspiration. *Eur Respir J*. 2010;36:28–32. [PubMed: 19926733]

19. Diette GB, White P, Jr, Terry P, Jenckes M, Rosenthal D, Rubin HR. Utility of on-site cytopathology assessment for bronchoscopic evaluation of lung masses and adenopathy. *Chest*. 2000;117:1186–90. [PubMed: 10767258]
20. Diacon AH, Schuurmans MM, Theron J, Louw M, Wright CA, Brundyn K, et al. Utility of rapid on-site evaluation of transbronchial needle aspirates. *Respiration*. 2000;72:182–8. [PubMed: 15824529]
21. Sharma M. Combined imaging for benign mediastinal lymphadenopathy: Endoscopic ultrasonography first or endobronchial ultrasonography first? *Chest*. 2011;140:558–9. [PubMed: 21813539]
22. Herth FJ, Krasnik M, Kahn N, Eberhardt R, Ernst A. Combined endoscopic-endobronchial ultrasound-guided fine-needle aspiration of mediastinal lymph nodes through a single bronchoscope in 150 patients with suspected lung cancer. *Chest*. 2010;138:790–4. [PubMed: 20154073]
23. Medford AR, Agrawal S. Single bronchoscope combined endoscopic-endobronchial ultrasound-guided fine-needle aspiration for tuberculous mediastinal nodes. *Chest*. 2010;138:1274. [PubMed: 21051408]

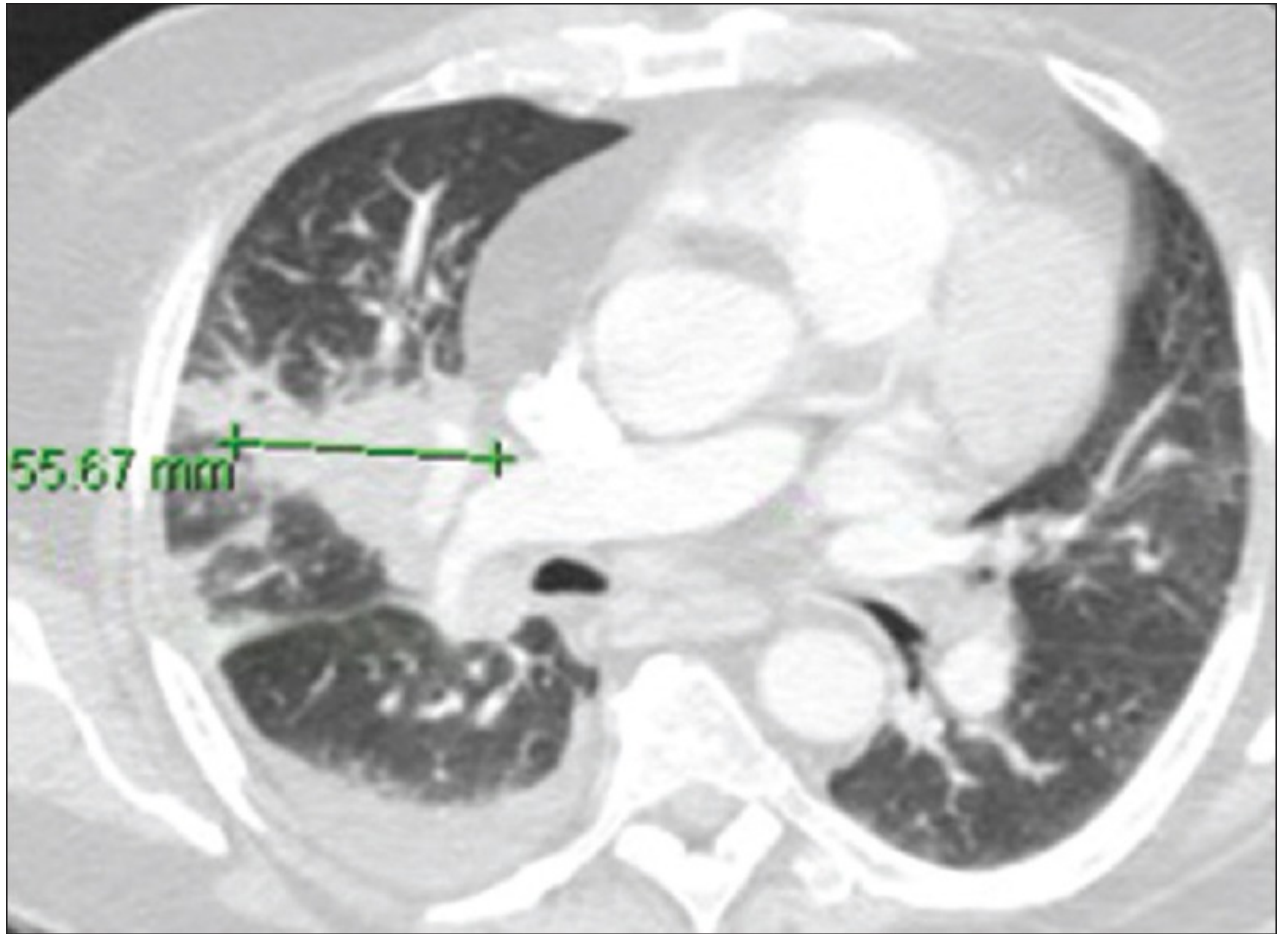
## Figures and Tables

---

**Figure 1**

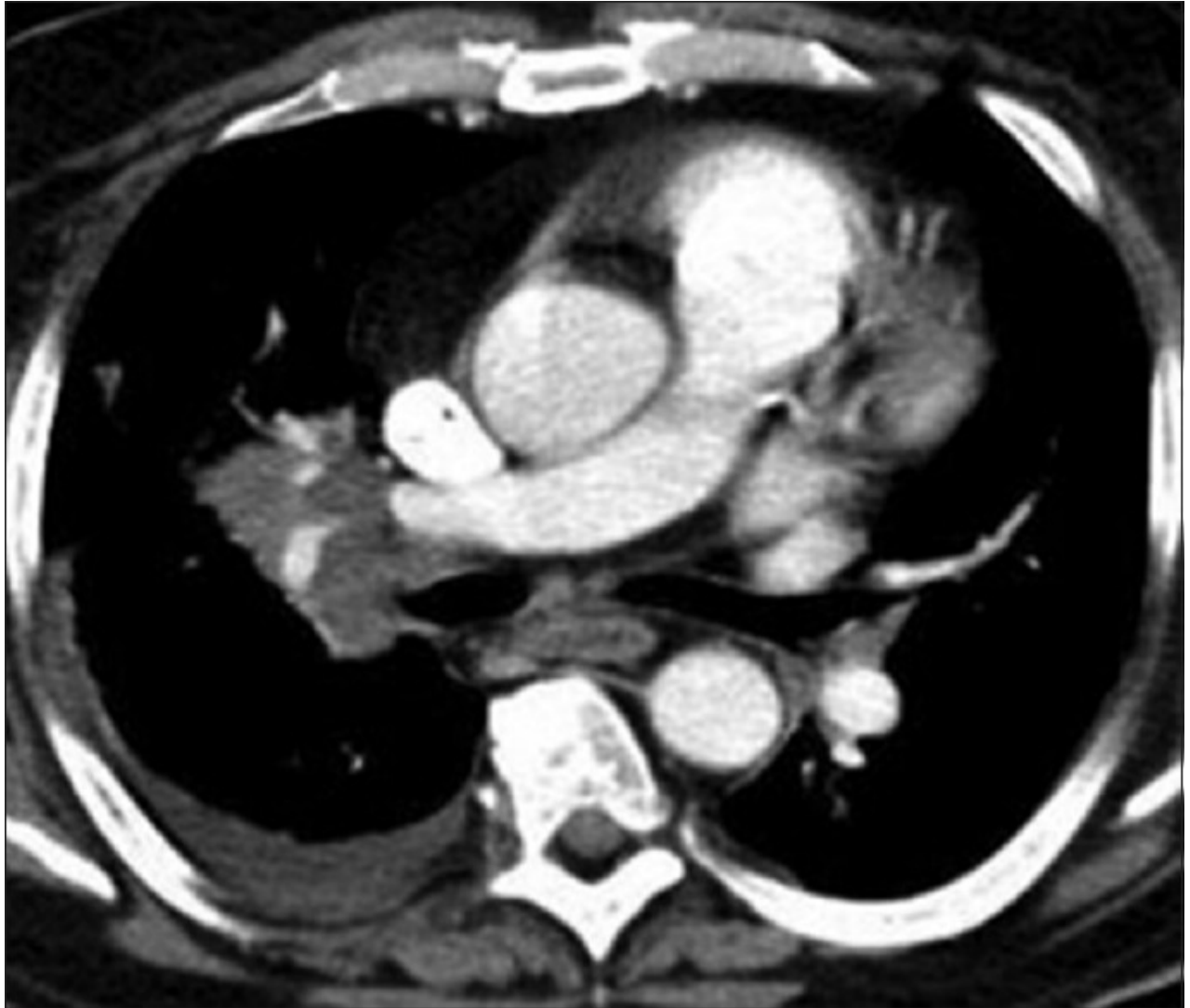

Initial computed tomogram chest showing a right hilar mass measuring 3.3 cm in its transverse diameter with a small right pleural effusion

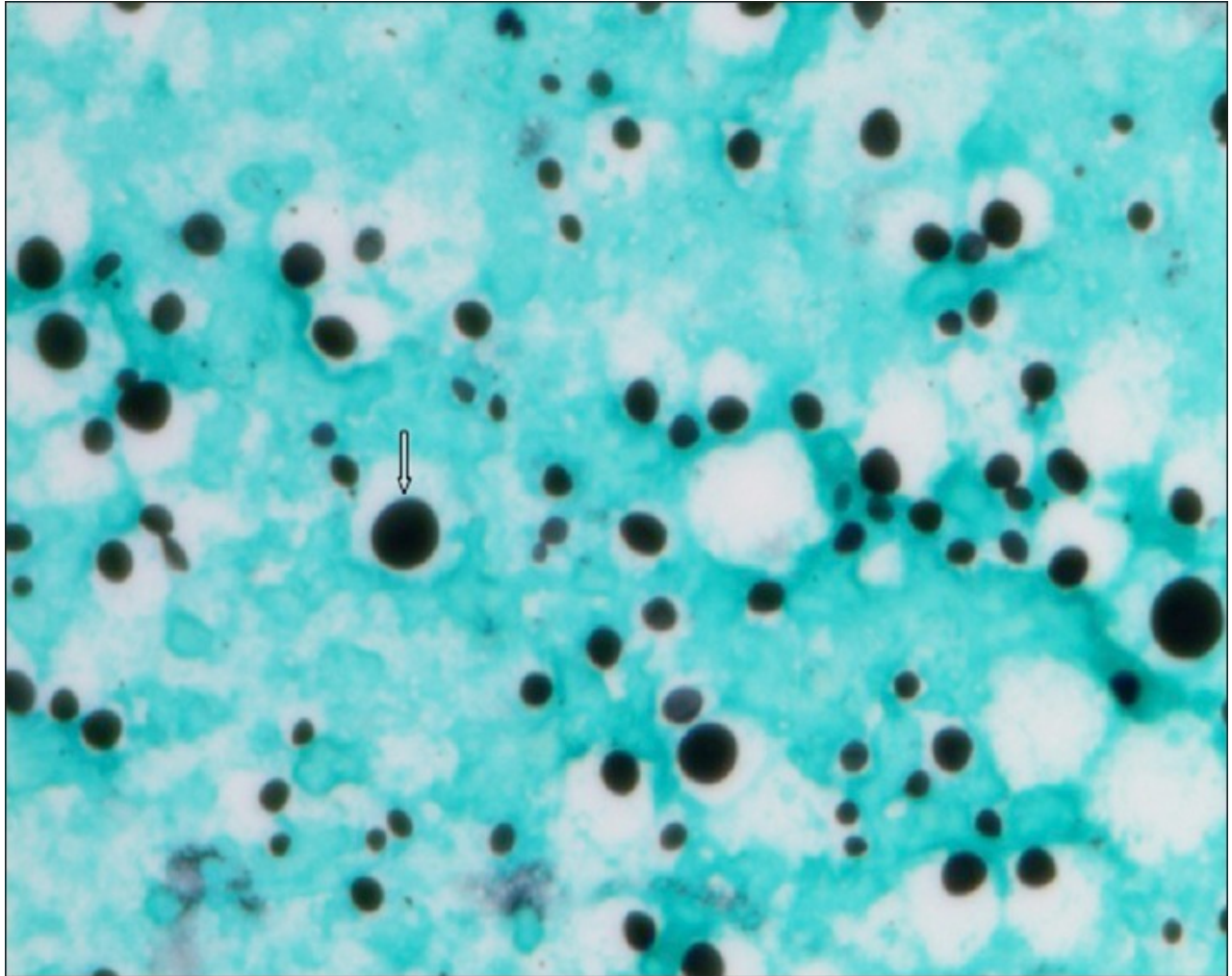
**Figure 2**

Repeat computed tomogram chest showing a right hilar mass now measuring 5.5 cm in its transverse diameter and increased peripheral opacities with a small right pleural effusion

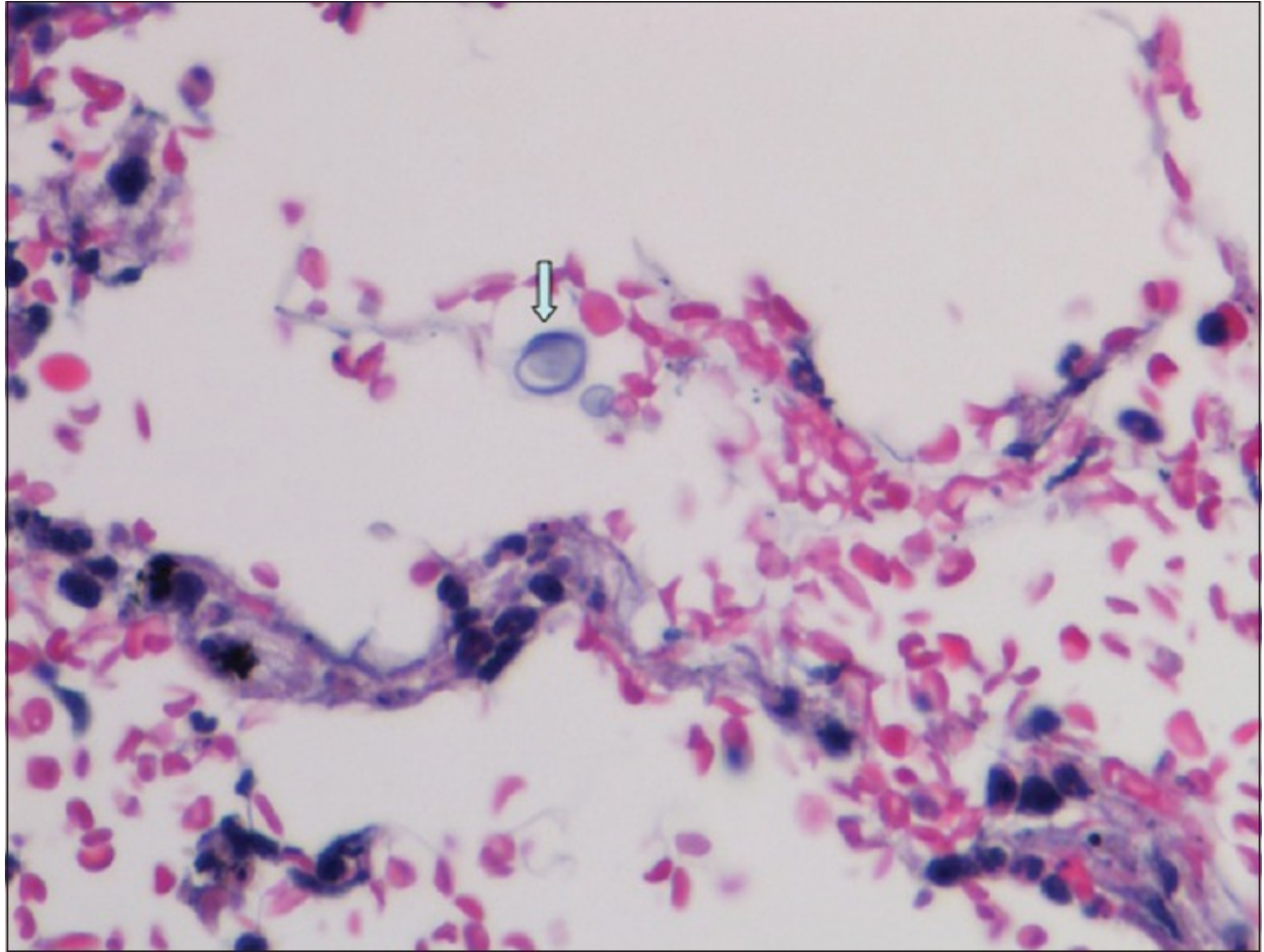


**Figure 3**

Computed tomogram chest with contrast showing right hilar mass and subcarinal lymphadenopathy with a small right pleural effusion

**Figure 4**

Slide treated with Gomori-Grocott methenamine silver stain showing *cryptococcus neoformans* cells (arrow) at high power

**Figure 5**

Slide treated with hematoxylin and eosin stain showing encapsulated yeast cells of *Cryptococcus neoformans* (arrow)

---

Articles from Lung India : Official Organ of Indian Chest Society are provided here courtesy of **Wolters Kluwer -- Medknow Publications**