

2015

Successful pregnancy outcome in paroxysmal nocturnal hemoglobinuria (PNH) following escalated eculizumab dosing to control breakthrough hemolysis

R. Sharma

Zucker School of Medicine at Hofstra/Northwell

A. Keyzner

Northwell Health

J. Liu

Northwell Health

T. Bradley

Zucker School of Medicine at Hofstra/Northwell

S. L. Allen

Zucker School of Medicine at Hofstra/Northwell

Follow this and additional works at: <https://academicworks.medicine.hofstra.edu/publications>



Part of the [Hematology Commons](#), and the [Oncology Commons](#)

Recommended Citation

Sharma R, Keyzner A, Liu J, Bradley T, Allen SL. Successful pregnancy outcome in paroxysmal nocturnal hemoglobinuria (PNH) following escalated eculizumab dosing to control breakthrough hemolysis. . 2015 Jan 01; 4(1):Article 2058 [p.]. Available from: <https://academicworks.medicine.hofstra.edu/publications/2058>. Free full text article.

This Article is brought to you for free and open access by Donald and Barbara Zucker School of Medicine Academic Works. It has been accepted for inclusion in Journal Articles by an authorized administrator of Donald and Barbara Zucker School of Medicine Academic Works. For more information, please contact academicworks@hofstra.edu.



ELSEVIER

Contents lists available at ScienceDirect

Leukemia Research Reports

journal homepage: www.elsevier.com/locate/lrr

Case report

Successful pregnancy outcome in paroxysmal nocturnal hemoglobinuria (PNH) following escalated eculizumab dosing to control breakthrough hemolysis

Ruby Sharma, Alla Keyzner, Johnson Liu, Thomas Bradley, Steven L. Allen

Division of Hematology, Department of Medicine, Hofstra North Shore-LIJ School of Medicine, Lake Success, NY, USA

ARTICLE INFO

Article history:

Received 3 July 2014

Received in revised form

26 March 2015

Accepted 10 May 2015

Available online 16 May 2015

Keywords:

Breakthrough PNH hemolysis complicating pregnancy

Escalated eculizumab dosing

ABSTRACT

Pregnancy in women with paroxysmal nocturnal hemoglobinuria (PNH) is associated with increased maternal and fetal morbidity and mortality. There is limited published experience regarding therapy of PNH during pregnancy. We describe a case of a 30 year old female with hypoplastic myelodysplastic syndrome and PNH. After two years of treatment with eculizumab, she became pregnant. She developed breakthrough hemolysis at 20 weeks gestation. Pharmacokinetic and pharmacodynamic studies demonstrated a subtherapeutic eculizumab level with absence of complement blockade. Escalation of her eculizumab dose successfully controlled hemolysis and restored therapeutic eculizumab level and activity. She delivered a healthy baby at 36 weeks.

© 2015 The Authors. Published by Elsevier Ltd. This is an open access article under the CC BY-NC-ND license (<http://creativecommons.org/licenses/by-nc-nd/4.0/>).

1. Introduction

Paroxysmal nocturnal hemoglobinuria (PNH) is a rare acquired clonal stem cell disorder characterized by intravascular hemolysis and thrombophilia. Pregnancy in PNH is associated with increased maternal and fetal morbidity and mortality due to thromboembolism, infection and premature birth [1]. Therefore, PNH has been considered a relative contraindication for pregnancy. The terminal complement cascade inhibitor eculizumab has become the standard treatment in patients with symptomatic PNH. There are limited published data regarding the use of eculizumab in pregnancy in either animal studies or in humans. We report a patient with PNH who became pregnant while on eculizumab, required dose escalation during the third trimester to control breakthrough hemolysis, and successfully delivered a healthy baby.

2. Materials and methods

Eculizumab levels were measured at Cambridge Biomedical using a manual ELISA method in which the microtitre plates are coated with C5, then blocked. Standards, controls, and unknowns were added. After incubation and washing, mouse anti-human IgG4 horseradish peroxidase (HRP) was added as the conjugate. Then the substrate 3,3',5,5'-tetramethylbenzidine (TMB) was added and the color reaction was halted using a stop reagent. The results were read spectrophotometrically at 450 nm using a plate reader [2]. The pharmacodynamics of eculizumab were

determined by measuring the capacity of the patient's serum to lyse chicken erythrocytes in a standard total human serum-complement hemolytic assay [3].

2.1. Case report

A 30 year old Chinese female presented with pancytopenia and direct antiglobulin negative hemolytic anemia in 2010. She was diagnosed with hypoplastic myelodysplastic syndrome due to dysplastic features noted on the bone marrow aspirate and biopsy, although with normal cytogenetics. A PNH clone was identified by flow cytometry with type I RBC 93.9% (reference range – 99.0 to 100.0%), type II RBC 0.10% (reference range – 0.00 to 0.99%) and type III RBC 6.00% (reference range – 0.00–0.01%). Her granulocyte clone size was 52.93% (reference range – 0.00–0.01%). She was treated with cyclosporine, horse anti-thymocyte globulin, steroids and standard dose eculizumab with a good response. Her lactate dehydrogenase (LDH) levels returned to normal with a simultaneous improvement in her hemoglobin level from 6 g/dl to 12 g/dl. She no longer required blood nor platelet transfusion. She had no thrombotic events. She was advised against pregnancy and urged to use non-hormonal contraceptives. Two years after the initial diagnosis, she was noted to have a decline in hemoglobin from 12 g/dl to 7 g/dl with a simultaneous rise in LDH to 1027 U/L and undetectable haptoglobin (Fig. 1). A repeat bone marrow aspiration and biopsy showed focal erythroid hyperplasia, mild dyserythropoiesis, normal myelopoiesis, small lymphoid aggregate, and increased iron stores.

<http://dx.doi.org/10.1016/j.lrr.2015.05.001>

2213-0489/© 2015 The Authors. Published by Elsevier Ltd. This is an open access article under the CC BY-NC-ND license (<http://creativecommons.org/licenses/by-nc-nd/4.0/>).

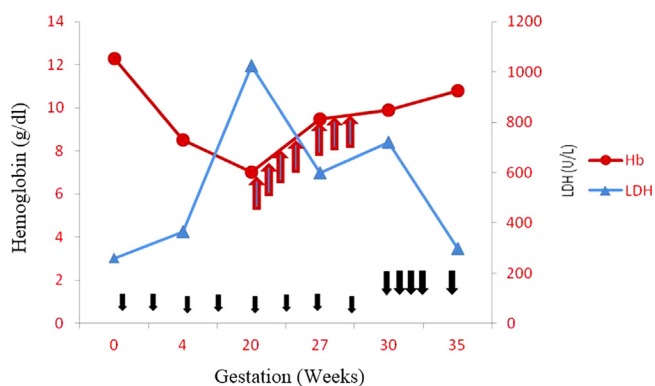


Fig. 1. Trend of LDH and hemoglobin measured at Baseline, 4 weeks (calculated retrospectively), 20 weeks, 27 weeks and 30 weeks and 35 weeks. Red cell transfusion indicated by red arrows. Small black arrows represent ecuzimab 900 mg every 2 weeks. Large black arrows represent ecuzimab 900 mg weekly x 4 doses followed by 1200 mg every 2 weeks.

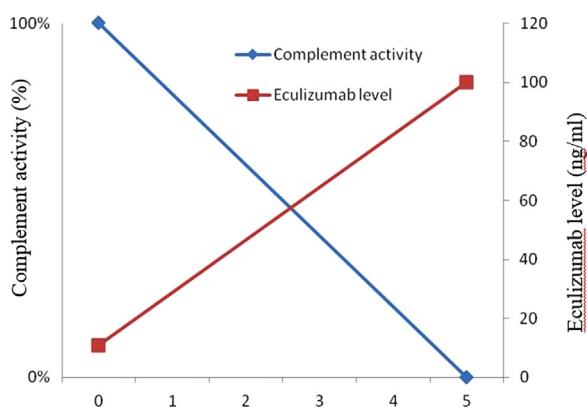


Fig. 2. Complement activity by pharmacodynamic assay (PD) shown on left Y axis. Ecuzimab level by pharmacokinetic assay (PK) shown on right Y axis. Graph depicts fully active complement system with subtherapeutic ecuzimab level before re-induction (week 0) and complete blockade of complement activity with therapeutic ecuzimab levels.

There was no evidence of clonal evolution based on cytogenetics. The PNH granulocyte clone size increased to 90%. On further investigation, she was found to be pregnant at 20 weeks gestation. Full anticoagulation with enoxaparin was begun due to the increased risk of thrombosis. She continued therapy with ecuzimab 900 mg every 2 weeks. She required an average of 1 unit of packed red blood cell transfusion per week for symptomatic anemia (Fig. 1). At week 30, her serum ecuzimab level was found to be less than 11 ug/ml (therapeutic > 99 ug/ml). Pharmacodynamic (PD) assay showed no complement blockade by ecuzimab. She was re-induced with ecuzimab 900 mg IV weekly x 4 doses, followed by 1200 mg IV every 2 weeks. Repeat ecuzimab level after 5 weeks was 100 ug/ml with complete complement blockade by PD assay and her hemolysis was controlled (Fig. 2). Her hemoglobin rose to 10.8 g/dl without further blood transfusion. She did not have evidence of pre-eclampsia nor proteinuria. She had an elective Cesarean section at 36 weeks and gave birth to a healthy female baby with APGAR score 9/9. Ecuzimab levels were undetectable in both cord blood and breast milk. She continued anticoagulation in the postpartum period. No thrombotic nor bleeding complications were noted in the postpartum period. She continued on ecuzimab 1200 mg

every 2 weeks for 3 months postpartum with stable hemoglobin and no evidence of active hemolysis. She remains stable on ecuzimab, the dose of ecuzimab was reduced to 900 mg every 2 weeks

3. Discussion

The median age at diagnosis of PNH is 34 years, so affected females are often in the reproductive age group. PNH is not known to adversely affect female fertility. There are 6 reported cases of successful pregnancies in PNH patients being treated with ecuzimab [4–7]. Kelly et al. described the first 3 women who received ecuzimab during pregnancy [4]. Two of these patients suffered from breakthrough hemolysis in the third trimester. Breakthrough hemolysis manifested itself with patients experiencing hemoglobinuria prior to their next scheduled dose of ecuzimab. Both of these patients were treated by reducing the interval between subsequent doses from 14 days to 12 days in one case and to 7 days in the other case. The third patient delivered at 28 weeks due to preeclampsia. Three other cases have been described [5–7]. One of them suffered breakthrough hemolysis and was treated by reducing the duration between ecuzimab doses to 7 days [7].

We describe the seventh case of successful pregnancy in the era of ecuzimab. Our patient was stable on standard dose ecuzimab until the second trimester. It has been noted that the dose of ecuzimab required to block complement during the latter stages of pregnancy is greater than in the non-pregnant state [4]. Our patient developed breakthrough hemolysis in the second trimester despite standard ecuzimab administration. Her ecuzimab level was sub-therapeutic and a pharmacodynamic assay demonstrated the absence of complement blockade. Rather than reducing the time interval between doses, we opted to escalate the dose of ecuzimab. Higher doses of ecuzimab have been needed to control atypical hemolytic uremic syndrome (aHUS) [8] and catastrophic antiphospholipid syndrome [9]. In aHUS, the recommended dose of ecuzimab is 33% higher than for PNH in order to completely block the complement cascade [10]. Utilizing this escalated dose of ecuzimab, we successfully achieved therapeutic ecuzimab levels with adequate complement blockade (Fig. 2) and controlled the patient's hemolysis (Fig. 1). This dose of ecuzimab was also recently reported in a pregnant patient with aHUS and found to be safe [11].

Pregnancy activates the complement cascade, with increased terminal complex formation in the third trimester [12]. We hypothesize that loss of control of complement-mediated hemolysis with ecuzimab during the second and third trimester appears to be due to the physiologic expansion of intravascular volume which occurs during pregnancy. Our patient's serum ecuzimab level was clearly subtherapeutic, reflecting the dilution which had occurred. Dose escalation restored the level to therapeutic range and controlled hemolysis.

Ecuzimab levels were not detectable in our patient's cord blood nor breast milk. It therefore does not appear to cross the placenta nor be excreted in breast milk, which is consistent with previous reports [4–7]. Forty-five percent of pregnancies in women with PNH result in spontaneous miscarriage and 6% in maternal mortality due to fatal thrombotic events [13]. Because of the risk of life threatening thrombotic complications, pregnant women with PNH should receive full anticoagulation during pregnancy and for at least 4–6 weeks postpartum [14].

Our case highlights that breakthrough hemolysis can occur early in gestation and that pregnant patients with PNH require close monitoring. It appears that ecuzimab can be safely used throughout pregnancy. Many PNH patients require either a shortening of dose interval or treatment with higher doses of ecuzimab in order to control hemolysis as pregnancy progresses.

Contribution

All authors were involved in drafting the article or revising it critically for important intellectual content. All authors approved the final version.

Conflict-of-interest disclosure

The authors declare no competing financial interests.

Acknowledgments

We are grateful to Alexion Pharmaceuticals for pharmacokinetic and pharmacodynamic measurements of eculizumab.

References

- [1] Fieni S, Bonfanti L, Gramellini D, Benassi L, Delsignore R. Clinical management of paroxysmal nocturnal hemoglobinuria in pregnancy: a case report and updated review. *Obstet Gynecol Surv* 2006;61(9):593–601.
- [2] Thomas TC, Rollins SA, Rother RP, et al. Inhibition of complement activity by humanized anti-C5 antibody and single-chain Fv. *Mol Immunol* 1996;33:1389–401.
- [3] Rinder CS, Rinder HM, Smith BR, Fitch JC, Smith MJ, Tracey JB, Matis LA, Squinto SP, Rollins SA. Blockade of C5a and C5b-9 generation inhibits leukocyte and platelet activation during extracorporeal circulation. *J Clin Invest* 1995;96:1564–72.
- [4] Kelly R, Arnold L, Richards S, et al. The management of pregnancy in paroxysmal nocturnal haemoglobinuria on long term eculizumab. *Br J Haematol* 2010;149(3):446–50.
- [5] Marasca R, Coluccio V, Santachiara R, et al. Pregnancy in PNH: another eculizumab baby. *Br J Haematol* 2010;150(6):707–8.
- [6] Danilov AV, Smith H, Craigo S, Feeney DM, Relias V, Miller KB. Paroxysmal nocturnal hemoglobinuria (PNH) and pregnancy in the era of eculizumab. *Leuk Res* 2009;33(6):e4–5.
- [7] Roth A, Tokareva O, Hock C, Duhren U. Management of pregnancy in paroxysmal nocturnal hemoglobinuria (PNH) in the era of eculizumab: a case report and updated review. *Onkologie* 2011;34(Suppl 6):67 Abstract 259.
- [8] Legendre CM, Licht C, Muus P, et al. Terminal complement inhibitor eculizumab in atypical hemolytic-uremic syndrome. *N Engl J Med* 2013;368(23):2169–81.
- [9] Shapira I, Andrade D, Allen SL, Salmon JE. Brief report: induction of sustained remission in recurrent catastrophic antiphospholipid syndrome via inhibition of terminal complement with eculizumab. *Arthritis Rheum* 2012;64(8):2719–23.
- [10] Loirat C, Frémeaux-Bacchi V. Atypical hemolytic uremic syndrome. *Orphanet J Rare Dis* 2011;6:60.
- [11] Ardissino G, Ossola MW, Baffero GM, Rigotti A, Cugno M. Eculizumab for atypical hemolytic uremic syndrome in pregnancy. *Obstet Gynecol* 2013;122:487–9.
- [12] Townsley DM, Young NS. Blood consult: paroxysmal nocturnal hemoglobinuria and its complications. *Blood* 2013;122(16):2795–8.
- [13] Bais J, Pel M, von dem Borne A, van der Lelie H. Pregnancy and paroxysmal nocturnal hemoglobinuria. *Eur J Obstet Gynecol Reprod Biol* 1994;53:211–4.
- [14] Ray JG, Burrows RF, Ginsberg JS, Burrows EA. Paroxysmal nocturnal hemoglobinuria and the risk of venous thrombosis: review and recommendations for management of the pregnant and nonpregnant patient. *Haemostasis* 2000;30(3):103–17.