

2014

## Intravenous albumin infusion is an effective therapy for hyponatremia in patient with malignant ascites

K. D. Jhaveri

*Zucker School of Medicine at Hofstra/Northwell*

A. Chawla

*Northwell Health*

C. Xu

A. Hazzan

*Zucker School of Medicine at Hofstra/Northwell*

Follow this and additional works at: <https://academicworks.medicine.hofstra.edu/publications>



Part of the [Nephrology Commons](#)

---

### Recommended Citation

Jhaveri K, Chawla A, Xu C, Hazzan A. Intravenous albumin infusion is an effective therapy for hyponatremia in patient with malignant ascites. . 2014 Jan 01; 24(1):Article 2362 [ p.]. Available from: <https://academicworks.medicine.hofstra.edu/publications/2362>. Free full text article.

This Article is brought to you for free and open access by Donald and Barbara Zucker School of Medicine Academic Works. It has been accepted for inclusion in Journal Articles by an authorized administrator of Donald and Barbara Zucker School of Medicine Academic Works. For more information, please contact [academicworks@hofstra.edu](mailto:academicworks@hofstra.edu).



Indian J Nephrol. 2014 Jan-Feb; 24(1): 51–53.

doi: [10.4103/0971-4065.125116](https://doi.org/10.4103/0971-4065.125116)

PMCID: PMC3927194

PMID: [24574634](https://pubmed.ncbi.nlm.nih.gov/24574634/)

## Intravenous albumin infusion is an effective therapy for hyponatremia in patient with malignant ascites

[K. D. Jhaveri](#), [A. Chawla](#), [C. Xu](#),<sup>1</sup> and [A. Hazzan](#)

Department of Internal Medicine, Division of Kidney Diseases and Hypertension, Hofstra North Shore-LIJ School of Medicine, Great Neck, New York, USA

<sup>1</sup>Department of Internal Medicine, Division of Nephrology, University of Chicago, Illinois

**Address for correspondence:** Dr. K. D. Jhaveri, 100 Community Drive, Second Floor, Great Neck, New York 11021, USA. E-mail:

[kdj200@gmail.com](mailto:kdj200@gmail.com)

**Copyright** : © Indian Journal of Nephrology

This is an open-access article distributed under the terms of the Creative Commons Attribution-Noncommercial-Share Alike 3.0 Unported, which permits unrestricted use, distribution, and reproduction in any medium, provided the original work is properly cited.

### Abstract

[Go to:](#)

There are few reports about the treatment of moderate to severe hyponatremia associated with malignant liver metastasis. Here, we report using intravenous salt poor albumin infusion to treat hypervolemic cirrhosis related hyponatremia. A 58-year-old female with ascites secondary to metastatic breast cancer was referred to our department with symptomatic hyponatremia (serum sodium concentration of 121 mEq/L). The serum sodium level was corrected slowly over 2 days with intravenous albumin infusion and the patient's symptoms – fatigue, nausea, dizziness and headache improved.

**Keywords:** Albumin infusion, cirrhosis, hypervolemic hyponatremia, hyponatremia, salt poor albumin

### Introduction

[Go to:](#)

Cirrhosis of the liver is frequently associated with chronic hypervolemic hyponatremia.[1] As prolonged hyponatremia of even modest degree (125 mmol/l) may cause irreversible neurological damage,[2] it is recommended that hyponatremia associated with cirrhosis should be treated once the serum sodium decreased below 130 mEq/L. The cause of the hyponatremia in cirrhosis patients is related to a marked reduction in systemic vascular resistance, especially in the splanchnic circulation and compensatory activation of endogenous vasoconstrictors including the rennin-angiotensin system, the sympathetic nervous system and antidiuretic hormone (ADH).[3] There are several reports showing that intravenous albumin infusion could be used effectively to treat hyponatremia in cirrhotic patients with ascites. [4,5,6,7,8,9] Massive hepatic metastasis also leads to ascites, few reports showed management of hyponatremia under this condition. Here, we presented a case of a patient with massive hepatic metastasis who presented to the hospital with a serum sodium concentration of 121 mEq/L, which corrected with intravenous albumin infusion.

### Case Report

[Go to:](#)

A 58-year-old African American female was referred to renal service with hyponatremia and a 2-day history of weakness, anorexia and headache. The patient had a medical history significant for metastatic breast cancer and ascites requiring frequent therapeutic paracentesis. On physical exam, the patient was noted to have marked ascites with a prominent fluid wave and bulging flanks, bilateral pitting edema

below the knees. Her vitals were significant for a pulse of 78 beats/min, blood pressure of 102/68 mm/Hg. Significant laboratory studies included a white blood cell count of  $4.3 \times 10^9/L$ , aspartate transaminase of 111 U/L, alanine transaminase of 49 U/L, albumin of 2.4 g/dl, serum sodium concentration of 121 mEq/L, and serum osmolality of 260 mosm/kg. Patient's serum sodium was 130-131 mEq/L at baseline. However, in the past 3 days, she was given dextrose 5% in 0.45% normal saline (D5 ½ NS) infusion because of her poor oral intake. Urine electrolytes showed urine sodium concentration of  $<10 \text{ mmol/L}$ , and the urine osmolality was 412 mos/kg. Computed tomography scan of the abdomen and pelvis showed innumerable metastasis throughout the liver. A liver sonogram ruled out Budd Chiari's syndrome. The low urinary sodium is consistent with low effective circulating volume depletion, in this case, secondary to large amount of ascites and cirrhotic state. The urine osmolality of 412 mos/kg indicated an inability to normally excrete free water, likely because of persistent secretion of ADH (SIADH). Therefore, a diagnosis of hypervolemic hyponatremia in the setting of liver metastasis was made. SIADH was excluded based on the volume status of the patient (not euvolemic).

The patient was treated with 100 ml 25% albumin intravenous infusion every 8 h for 2 days for her symptomatic hyponatremia. She was on fluid restriction to  $<1200 \text{ cc/day}$  and appropriately with sodium restriction to less than 2300 mg/day. Her serum sodium concentration increased to 134 mEq/L over 48 h [ [Figure 1](#) ] and her weakness, anorexia, and headache significantly improved. She was discharged from the hospital with recommendations for fluid restriction. Her serum sodium concentration maintained in the range of 134-140 mEq/L in the next 2 months after her discharge.

## Discussion

[Go to:](#)

Chronic hyponatremia (defined as a serum sodium concentration below 130 mEq/L) presents in up to 22% of people with cirrhosis.[10] The prevalence of patients with cirrhosis and serum concentrations less than or equal to 120 mEq/L is 1.2%.[11] Little data is available studying the prevalence of hyponatremia in patients with liver metastasis. Acute worsening of chronic hyponatremia can be a result of one of the following factors: Reduced effective arterial volume, generalized hemodynamic derangement with low peripheral resistance, hypothalamic overproduction of ADH (not SIADH), diuretic use, hypotonic fluid ingestion and reduced glomerular filtration.[10,12,13] In our patient, the intravenous infusion of D5 ½ NS which contains hypotonic sodium chloride may be a factor for the acute worsening of the underlying chronic hyponatremia.

Treatment of hyponatremia in patients with cirrhosis commonly includes sodium and fluid restriction, treatment with spironolactone and loop diuretics. Infusion of 3% saline infusion and vasopressin receptor antagonists have also been used to treat patients with profound hyponatremia and severe symptoms. Increasing the intravascular volume using albumin has been shown to correct hyponatremia in patients with cirrhosis by increasing urinary free water clearance.[4,5,6,7,8,9] In our patient, fluid restriction would not be very effective since the patient already had diminished oral intake. We did not want to give the patient diuretics as they can exacerbate the reduction in kidney perfusion, further impairing the ability to excrete free water. By giving albumin infusion in this patient, we likely improved renal blood flow, and improved free water clearance.

Albumin infusion may also have suppressed volume-mediated ADH by increasing the intravascular volume. As noted before the patient's hypervolemic status excludes the possible diagnosis of SIADH and the heightened ADH in cirrhotics is related to an appropriate response with reduced pulmonary vascular response in splanchnic bed. We should mention that, while the serum sodium concentration in our patient increased from 121 mEq/L to 134 mEq/L after albumin infusion, her serum albumin increased from 2.4 g/dl to 3.2 g/dl after 50 ml 25% albumin infusion  $\times 6$  times. The approximate sodium content in the 25% albumin preparation is 145 mEq/L. The concentration of sodium itself in "salt poor" albumin 25% 50 cc bag is close to 6.5-7.5 mEq only and 3 such infusions a day is not enough sodium intake to explain rise in sodium observed in this patient. If we take into consideration of the Donnan effect of serum albumin on

serum sodium (addition and reduction of 2 mmol/l for serum sodium per 1 g/dl decrease and increase of serum albumin, respectively),<sup>[14]</sup> the actually change of serum sodium concentration should be 11.4 mEq/L (close to the change in our patient-13 mEq/L). In summary, we showed that intravenous of salt poor albumin infusion is an effective therapy for hyponatremia in patients with liver metastasis, likely using a mechanism similar to that in cirrhotic patients with ascites.

## Footnotes

[Go to:](#)

**Source of Support:** Nil

**Conflict of Interest:** None declared.

## References

[Go to:](#)

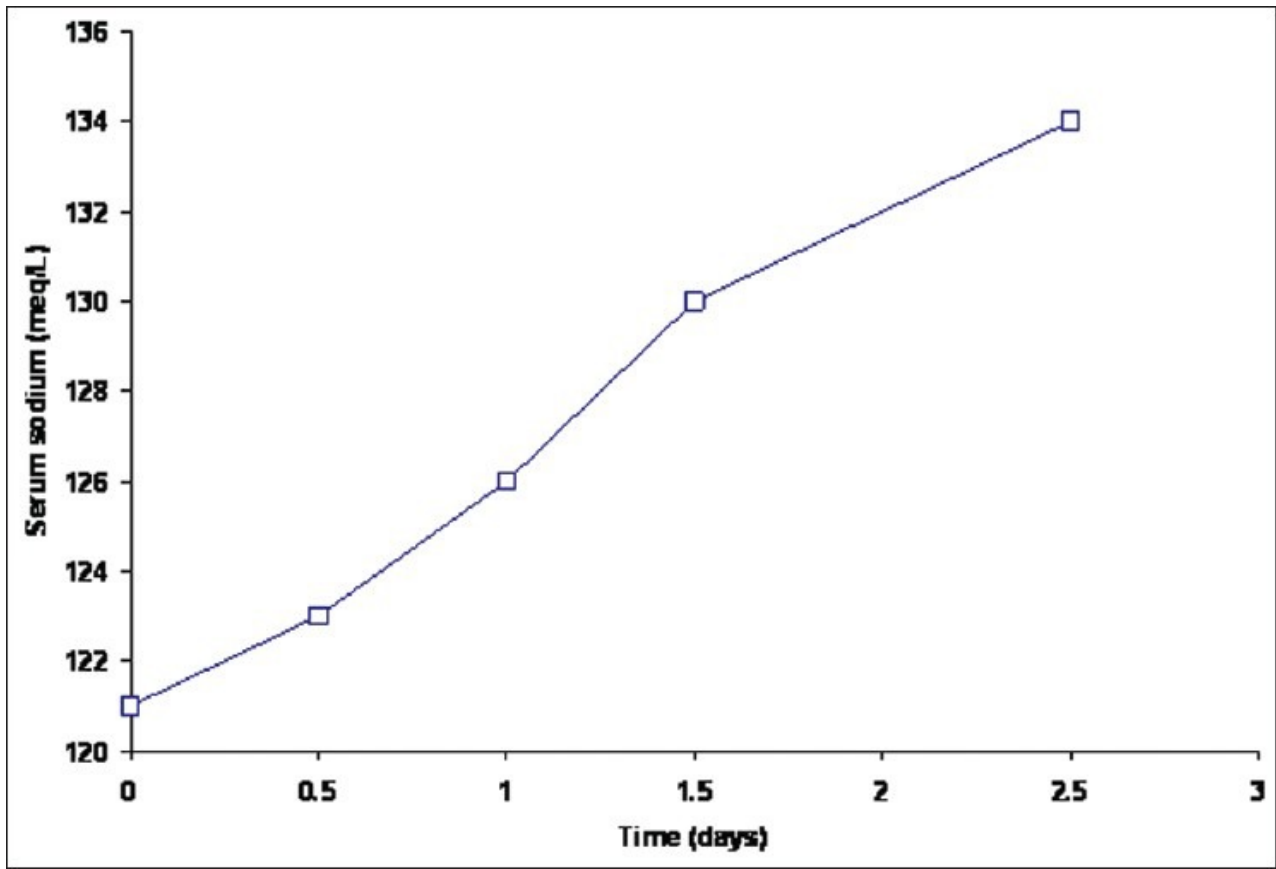
1. Arroyo V, Rodés J, Gutiérrez-Lizárraga MA, Revert L. Prognostic value of spontaneous hyponatremia in cirrhosis with ascites. *Am J Dig Dis.* 1976;21:249–56. [PubMed: 1266841]
2. Arieff AI, Llach F, Massry SG. Neurological manifestations and morbidity of hyponatremia: Correlation with brain water and electrolytes. *Medicine (Baltimore)* 1976;55:121–9. [PubMed: 1256311]
3. Groszmann RJ. Hyperdynamic circulation of liver disease 40 years later: Pathophysiology and clinical consequences. *Hepatology.* 1994;20:1359–63. [PubMed: 7927273]
4. Schedl HP, Bartter FC. An explanation for and experimental correction of the abnormal water diuresis in cirrhosis. *J Clin Invest.* 1960;39:248–61. [PMCID: PMC441802] [PubMed: 14442514]
5. Tristani FE, Cohn JN. Systemic and renal hemodynamics in oliguric hepatic failure: Effect of volume expansion. *J Clin Invest.* 1967;46:1894–906. [PMCID: PMC292942] [PubMed: 6073996]
6. Hagège H, Ink O, Ducreux M, et al. Treatment of ascites in patients with liver cirrhosis without neither hyponatremia nor renal insufficiency. Results of a randomized study comparing diuretics and punctures compensated by albumin. *Gastroenterol Clin Biol.* 1992;16(10):751–5. [PubMed: 1478401]
7. Vlahcevic ZR, Adham NF, Jick H, Moore EW, Chalmers TC. Renal effects of acute expansion of plasma volume in cirrhosis. *N Engl J Med.* 1965;272:387–91. [PubMed: 14242512]
8. Dandona P, Fonseca V, Baron DN. Hypoalbuminaemic hyponatraemia: A new syndrome? *Br A Med J.* 1985;291:1253–5. [PMCID: PMC1417090]
9. McCormick PA, Mistry P, Kaye G, Burroughs AK, McIntyre N. Intravenous albumin infusion is an effective therapy for hyponatraemia in cirrhotic patients with ascites. *Gut.* 1990;31:204–7. [PMCID: PMC1378381] [PubMed: 2311979]
10. Ginès P, Guevara M. Hyponatremia in cirrhosis: Pathogenesis, clinical significance, and management. *Hepatology.* 2008;48:1002–10. [PubMed: 18671303]
11. Angeli P, Wong F, Watson H, Ginès P CAPPS Investigators. Hyponatremia in cirrhosis: Results of a patient population survey. *Hepatology.* 2006;44:1535–42. [PubMed: 17133458]
12. Martín-Llahí M, Guevara M, Ginès P. Hyponatremia in cirrhosis: Clinical features and management. *Gastroenterol Clin Biol.* 2006;30:1144–51. [PubMed: 17075468]
13. Lindsay A. Profound hyponatremia incirrhosis: A case report. *Cases J.* 2010;3:77. [PMCID: PMC2851673] [PubMed: 20331881]
14. Tanemoto M. Effect of serum albumin on serum sodium: Necessity to consider the Donnan effect. *QJM.* 2008;101:827–8. [PubMed: 18725371]

## Figures and Tables

---

[Go to:](#)

Figure 1



Time course of changes in serum sodium in the patient

---

Articles from Indian Journal of Nephrology are provided here courtesy of **Wolters Kluwer -- Medknow Publications**