

2018

Delayed Pneumothorax: A Potential Complication Of Transbronchial Lung Biopsy

N. Narula
Northwell Health

F. Siddiqui

A. H. Siddiqui
Northwell Health

W. C. Man
Northwell Health

M. Chalhoub
Zucker School of Medicine at Hofstra/Northwell


Follow this and additional works at: <https://academicworks.medicine.hofstra.edu/publications>

 Part of the [Pulmonology Commons](#)

Recommended Citation

Narula N, Siddiqui F, Siddiqui AH, Man WC, Chalhoub M. Delayed Pneumothorax: A Potential Complication Of Transbronchial Lung Biopsy. . 2018 Jan 01; 23():Article 4307 [p.]. Available from: <https://academicworks.medicine.hofstra.edu/publications/4307>. Free full text article.

This Article is brought to you for free and open access by Donald and Barbara Zucker School of Medicine Academic Works. It has been accepted for inclusion in Journal Articles by an authorized administrator of Donald and Barbara Zucker School of Medicine Academic Works. For more information, please contact academicworks@hofstra.edu.



Case report

Delayed Pneumothorax: A Potential Complication Of Transbronchial Lung Biopsy

Naureen Narula^{a,*}, Faraz Siddiqui^b, Abdul Hasan Siddiqui^b, Wai C. Man^a, Michel Chalhoub^b

^a Department of Internal Medicine, Staten Island University Hospital, Staten Island, NY, USA

^b Pulmonary and Critical Care, Staten Island University Hospital, Staten Island, NY, USA

A B S T R A C T

The purpose of this article is to report a case of secondary tension pneumothorax presenting seven weeks post Transbronchial Lung biopsy. A 62 year old male with a known history of germ cell tumor was found to have a left-sided pneumothorax which later complicated to a tension pneumothorax. To the best of our knowledge this is the second case being reported for a delayed pneumothorax post a Transbronchial Lung Biopsy. The purpose of this case report is to create awareness among physicians to consider this diagnosis even at a later stage and the importance of patient education regarding the signs and symptoms of pneumothorax. Our case adds to the medical literature, a new presentation of a rare complication of delayed pneumothorax post TBB.

1. Introduction

Transbronchial lung biopsy (TBB) is the most common invasive procedure performed for the diagnosis of plethora of lung diseases. Due to its relative safety, it is utilized fairly commonly in ICUs throughout the United States. The procedure however comes with inherent risks, the most common being bleeding and pneumothorax. Occurrence of pneumothorax (PTX) post transbronchial lung biopsy is very low approximately 1–2% [9]. Incidence of delayed pneumothorax, defined as PTX post 4 hour of TBB, is reportedly 5% in the general population [1]. Delayed PTX post TBB presenting as a tension PTX has never been reported based on our extensive literature research. In this case report, we will be discussing a case of delayed tension PTX which presented 7 weeks post TBB.

2. Case report

A 62 year old-male presented to the emergency department with a chief complaint of chronic cough. His past medical history was significant for germ cell tumor, hypertension and persistent lower left lobe infiltrates for which he had multiple courses of antibiotics without any significant improvement. Computed tomography (CT) chest scan was ordered, which showed lower left lobe (LLL) consolidation. A working diagnosis of organizing pneumonia was established, and to confirm the diagnosis Transbronchial lung biopsy was planned. Transbronchial lung biopsy of LLL anteromedial and basal segments was performed successfully without any complication. The biopsy results were consistent with chronic lymphocytic predominance and no malignant cells were appreciated.

Immediate post procedure Chest X-ray (CXR) was reported normal and patient was discharged home. Patient was followed at an outpatient setting by both his primary medical doctor and pulmonologist and he continued to remain asymptomatic except for persistent cough. It was seven weeks later that he presented again to the emergency department with sudden onset of shortness of breath associated with diaphoresis. Symptoms started after a bout of cough and worsened over minutes. Patient denied any history of trauma. His vitals in ED showed a blood pressure of 90/54 mm Hg, respiratory rate of 32 per minute, heart rate of 125 beats per minute, oxygen saturation (SaO₂) of 89% on room air and 100% on O₂ via facemask. Bedside ultrasound showed absence of the lung sliding sign on the left side. Diagnosis of pneumothorax was suspected and a pigtail catheter was inserted. The next day when the shortness of breath worsened a repeat CXR showed findings positive for a tension pneumothorax for which a chest tube was inserted. Repeat CXR confirmed resolution of the pneumothorax. Prior to discharge, patient underwent Video assisted thoracoscopic surgery (VATS) with no subsequent problems.

3. Discussion

Our case aims to highlight a rare presentation of delayed pneumothorax developing seven weeks post TBB. To the best of our knowledge this is an exclusive case with such delayed presentation of this uncommon complication.

Iatrogenic pneumothorax occurs as a result of diagnostic and/or therapeutic interventions [2]. Incidence of iatrogenic pneumothorax post TBB in USA is reportedly 1–6% in general population [1] and 0–1.5% in

* Corresponding author.

E-mail addresses: drnaureennarula@gmail.com (N. Narula), drsiddiqui07@gmail.com (A.H. Siddiqui).

transplant patients [3]. As per current recommendations, it can be classified as acute, occurring within 1–4 hours post procedure or delayed, occurring after 4 hours post procedure. The current recommendations are to obtain CXR 30–60 minutes post TBB [2]. Recent literature have documented delayed pneumothoraces presenting as late as 24 hours post biopsy, despite a reported normal one and four hour post biopsy radiographs [2]. Occurrence of delayed pneumothorax post TBB is a very rare phenomenon. It is seen most commonly in post lung transplant patients and in chronic infection particularly tuberculosis (TB). Decreased immunity, delayed wound healing due to chronic inflammation have been hypothesized as the possible precipitating mechanisms in the literature [10], however the precise underlying mechanism remains unknown.

The incidence of iatrogenic tension pneumothorax varies significantly with the choice of imaging intervention used to guide the biopsy. CT guided biopsies are associated with significant risk for pneumothorax. In a study of 150 patients with difficult thoracic lesions, either poorly visualized by conventional radiographs or deemed inaccessible, CT guided biopsy was used to provide diagnosis. 42% (n=64) of the patients in this study developed pneumothorax as a post procedure complication [4]. Incidence of iatrogenic pneumothorax with electromagnetic navigation biopsy (ENB) is reportedly 5–8% [5]. However patients with underlying lung diseases are more prone to develop such complications [5]. This increased risk for pneumothorax can also be attributed to the prolonged duration for which biopsy needle remains in the lung [4]. However these navigation interventions significantly increases sensitivity and specificity for discriminating between necrotic and malignant biopsy specimens [6]. Although complications are to be expected, the benefits of these procedure

appear to exceed the risks in patients in whom a histological diagnosis is deemed necessary [7].

Kwan et al. described a case similar to ours previously in which a lung transplant patient developed pneumothorax five months post TBB. Multiple imaging interventions later confirmed pneumothorax originated from the biopsy site. This case highlighted the atypical presentation of delayed pneumothorax, 5 months after TBB despite normal reported post biopsy radiographs [8].

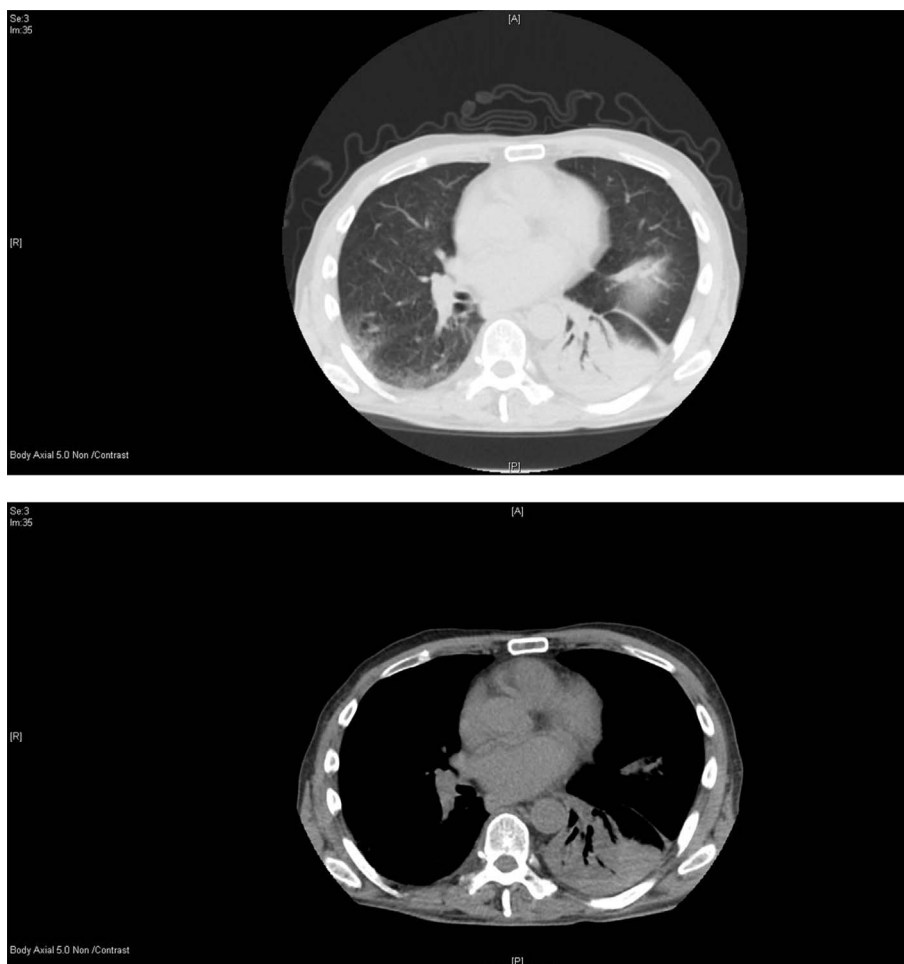
In our patient, the presence of low immunity, chronic cough and tissue inflammation most probably caused the delay in healing of the TBB sites. Our case adds to medical literature by describing a life-threatening complication of a very commonly performed procedure. It will help clinicians stratify high risk patients. It also confirmed the advantage of using bedside ultrasonography in critical care and its superiority over CXR in deciding immediate management. To the best of our knowledge this is the second case being reported for a delayed pneumothorax seven weeks post transbronchial biopsy. It is important to consider this diagnosis even at a later stage and patients should be educated regarding the signs and symptoms of pneumothorax.

4. Conclusion

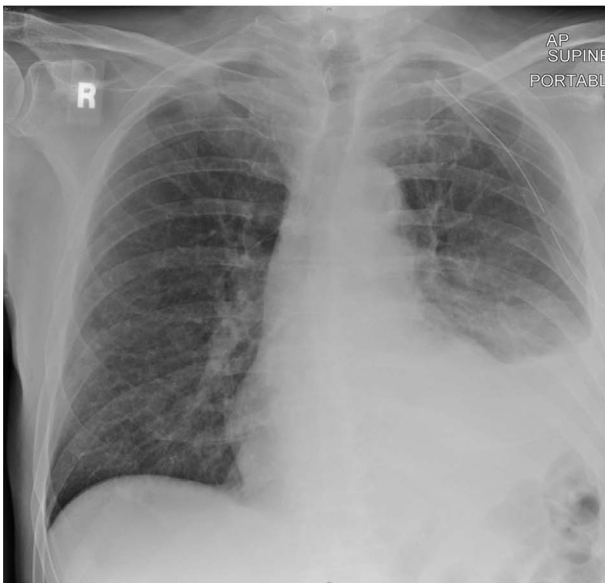
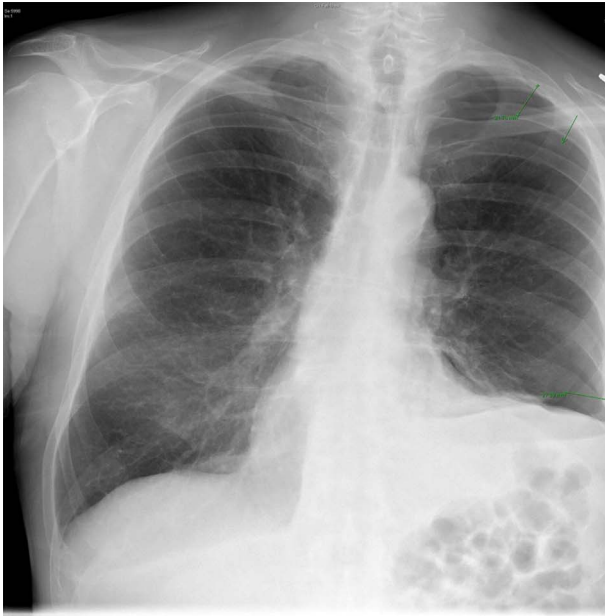Delayed pneumothorax is a rare life threatening iatrogenic complication of TBB. The diagnosis should be considered even months after TBB especially in patients with chronic lung diseases.

Images

- 1) CT scan.



XRAY.



Appendix A. Supplementary data

Supplementary data related to this article can be found at <http://dx.doi.org/10.1016/j.rmcr.2018.02.010>.

References

- [1] A.G. Arnold, P.W. Belfield, M.F. Myers, et al., Postal survey of medical bronchoscopies in the United Kingdom-1: deaths and complications [abstract], *Thorax* 39 (1984) 219–220.
- [2] A. Manhire, M. Charig, C. Clelland, et al., Guidelines for radiologically guided lung biopsy, *Thorax* 58 (11) (2003) 920–936.
- [3] T.J. McWilliams, T.J. Williams, H.M. Whitford, G.I. Snell, Surveillance bronchoscopy in lung transplant recipients: risk versus benefit, *J. Heart Lung Transplant.* 27 (11) (2008) 1203–1209.
- [4] E. van Sonnenberg, G. Casola, M. Ho, C.C. Neff, R.R. Varney, G.R. Wittich, et al., Difficult thoracic lesions: CT-guided biopsy experience in 150 cases, *Radiology* 167 (1988) 457–461.
- [5] P.A. Linden, Use of navigation bronchoscopy for biopsy and endobronchial fiducial placement, *Innovations* 6 (2011) 271–275.
- [6] K. Harris, D.J. Rohrbach, K. Attwood, J. Qiu, U. Sunar, Optical imaging of tissue obtained by transbronchial biopsies of peripheral lung lesions, *J. Thorac. Dis.* 9 (5) (2017 May) 1386–1392.
- [7] P.A. Bulpa, A.M. Dive, L. Mertens, M.A. Delos, J. Jamart, P.A. Evrard, M.R. Gonzalez, E.J. Installé, Combined bronchoalveolar lavage and transbronchial lung biopsy: safety and yield in ventilated patients, *Eur. Respir. J.* 21 (3) (2003 Mar) 489–494.
- [8] A.C. Kwan, S. Pipavath, P.J. Leary, G. Kicska, Delayed pneumothorax after bronchoscopy in a lung transplant patient, *Respir. Care* 58 (3) (2013 Mar) e18–e19.
- [9] Y. Huang, H. Huang, Q. Li, R.F. Browning, S. Parrish, J.F. Turner Jr., K. Zarogoulidis, I. Kougioumtzi, G. Dryllis, I. Kioumis, G. Pitsiou, A. Papaiwannou, S. Lampaki, N. Machairiotis, N. Katsikogiannis, A. Madesis, T. Karaiskos, Z. Li, P. Zarogoulidis, Transbronchial lung biopsy and pneumothorax, *J. Thorac. Dis.* 6 (S4) (2014) S443–S447, <http://dx.doi.org/10.3978/j.issn.2072-1439.2014.08.48>.
- [10] D.G. Yang, K.D. Kim, D.H. Shin, K.O. Choe, S.K. Kim, W.Y. Lee, Idiopathic bronchiolitis obliterans with organizing pneumonia presenting with spontaneous hydropneumothorax and solitary pulmonary nodule, *Respirology* 4 (1999) 267–270, <http://dx.doi.org/10.1046/j.1440-1843.1999.00187.x>.