

2018

An elderly patient's complete response to steroid therapy for collagenous gastritis

H. Lim

Northwell Health

B. Y. Wong

Zucker School of Medicine at Hofstra/Northwell

D. Elkowitz

Zucker School of Medicine at Hofstra/Northwell

K. Sultan

Zucker School of Medicine at Hofstra/Northwell

Follow this and additional works at: <https://academicworks.medicine.hofstra.edu/publications>



Part of the [Gastroenterology Commons](#)

Recommended Citation

Lim H, Wong BY, Elkowitz D, Sultan K. An elderly patient's complete response to steroid therapy for collagenous gastritis. . 2018 Jan 01; 9(8):Article 4443 [p.]. Available from: <https://academicworks.medicine.hofstra.edu/publications/4443>. Free full text article.

This Article is brought to you for free and open access by Donald and Barbara Zucker School of Medicine Academic Works. It has been accepted for inclusion in Journal Articles by an authorized administrator of Donald and Barbara Zucker School of Medicine Academic Works. For more information, please contact academicworks@hofstra.edu.

An elderly patient's complete response to steroid therapy for collagenous gastritis

Huei-Wen Lim , Benny Yiu Wong, David Elkowitz and Keith Sultan

Ther Adv Chronic Dis

2018, Vol. 9(8) 143–146

DOI: 10.1177/
2040622318759628

© The Author(s), 2018.
Reprints and permissions:
[http://www.sagepub.co.uk/
journalsPermissions.nav](http://www.sagepub.co.uk/journalsPermissions.nav)

Abstract: An 85-year-old woman presented with 9.1 kg (20 lb) weight loss over 5 months and an acute onset crampy abdominal pain. Examination revealed a diffusely tender abdomen, with gastric wall thickening noted on CT scan. Upper endoscopy showed diffuse severe erythema and friability. Histologic examination with hematoxylin and eosin staining revealed collagenous gastritis characterized by active chronic inflammation with sub-epithelial collagen deposition and erosion. The patient was started on steroid therapy with rapid clinical improvement and tapered off over 2.5 months. At 6 months, the patient reported an improved appetite with resolution of her abdominal pain. Repeat endoscopy revealed a grossly normal stomach and normal mucosal biopsies. She remains without complaints 1 year later. Collagenous gastritis, rare in the elderly, is a histologic diagnosis characterized by the deposition of a sub-epithelial collagen band thicker than 10 μm with an inflammatory infiltrate. In all ages the mucosa typically appears nodular and erythematous, caused by an uneven inflammation in the surrounding depressed mucosa with atrophic changes. Specific therapy has not been well-established, and the prognosis and potential for endoscopic or histological resolution remains unclear. While anecdotal, the success of steroids may offer a reasonable starting point for treatment of similar cases.

Keywords: collagenous gastritis, steroid, abdominal pain, collagen

Received: 5 September 2017; revised manuscript accepted: 16 January 2018.

Introduction

Collagenous gastritis is a rare entity characterized by the deposition of a sub-epithelial collagen band thicker than 10 μm with an infiltration of inflammatory mononuclear cells in the lamina propria.^{1–3} The first report, published in 1989 by Colletti and Trainer, presented a 15-year-old girl with recurrent abdominal pain and gastrointestinal bleeding who was found to have patchy chronic active gastritis with a sub-epithelial thickened band of collagen on biopsy.⁴ To date there have been fewer than 100 cases of collagenous gastritis reported in the literature, with most cases occurring in the pediatric population.⁵ Lagorce-Pages and colleagues described two distinct clinicopathologic patterns and presentation: (1) children or young adults presenting with epigastric pain and severe chronic anemia from upper gastrointestinal bleeding with disease limited to gastric mucosa and without colonic involvement; and (2) older adults presenting with chronic watery diarrhea found to

have both collagenous gastritis and collagenous colitis, with the clinical presentation reflecting the area of involved gastrointestinal tract.¹

In this report, we present a rare case of collagenous gastritis occurring in an elderly woman presenting with abdominal pain.

Case presentation

A 85-year-old woman with mild dementia, hypertension and hyperlipidemia presented with her caregiver to the outpatient clinic for evaluation of 'difficulty eating' and 9.1 kg (20 lb) weight loss over the prior 5 months. She denied nausea, vomiting, diarrhea, difficulty or pain with swallowing. There was no history of melena or hematochezia. The patient described feelings of severe anxiety when sitting down to a meal, which was confirmed by her caregiver's observations. Review of systems was

Correspondence to:
Huei-Wen Lim
Northwell Health, 300
Community Drive,
Manhasset, NY 11030, USA
lim.hueiwen@gmail.com
Benny Yiu Wong
David Elkowitz
Northwell Health,
Manhasset, NY, USA
Keith Sultan
Hofstra Northwell School
of Medicine, Manhasset,
NY, USA

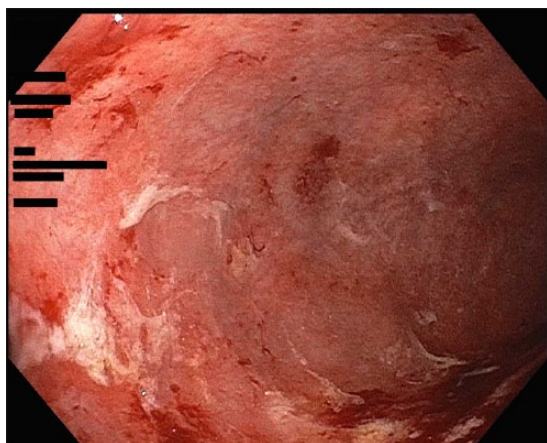


Figure 1. Esophagogastroduodenoscopy (EGD) revealing severe inflammation, friability and granularity around the entire examined stomach.

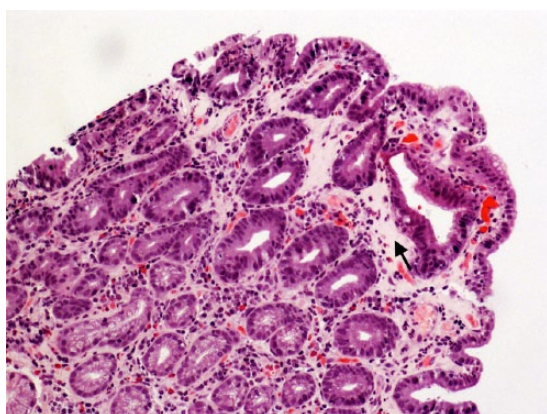


Figure 2. Hematoxylin and eosin staining showing collagenous gastritis characterized by active chronic inflammation with sub-epithelial collagen deposition and erosion.

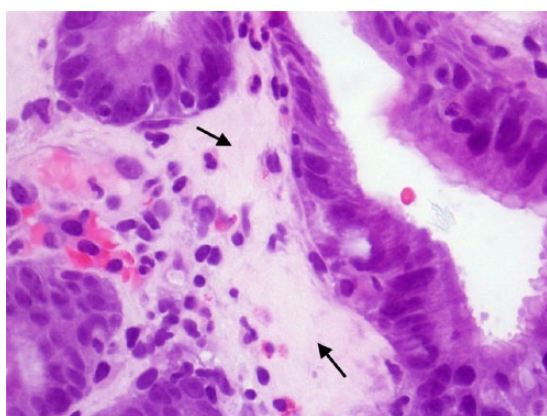


Figure 3. Hematoxylin and eosin staining showing collagenous gastritis characterized by active chronic inflammation with sub-epithelial collagen deposition and erosion.

otherwise unremarkable. There was no reported history of chronic NSAID or acetylsalicylic acid use, nor family history of any gastrointestinal disease. Physical examination at the outpatient clinic was unremarkable, including the abdominal exam. The diagnostic workup was limited to an upper gastrointestinal series, which was normal. The patient was referred back to her geriatrician and psychiatrist.

One month following initial gastrointestinal evaluation the patient was admitted for several days of diffuse, crampy abdominal pain, worse with food. Physical examination revealed a diffusely tender abdomen in all quadrants with guarding but no rebound. Laboratory values were unremarkable except for a mild microcytic hypochromic anemia (hemoglobin, 11.4 g/dl, MCV 77.5 fl, MCH 23.4 pg). A CT scan of her abdomen and pelvis showed diffuse gastric wall thickening suggestive of gastritis. Subsequently, she underwent an esophagogastroduodenoscopy that revealed diffuse severe inflammation, friability and granularity around the entire examined stomach (Figure 1). Histologic examination with hematoxylin and eosin staining revealed collagenous gastritis characterized by active chronic inflammation with sub-epithelial collagen deposition and erosion (Figures 2 and 3). The patient was diagnosed with collagenous gastritis. Celiac sprue serology including antigliadin, antitissue transglutaminase and antiendomysial antibodies were negative. Warthin Starry stain was negative for *Helicobacter pylori*.

After several days without a response to pantoprazole 40 mg twice a day and sucralfate 1 g orally four times a day, the patient was started on methylprednisolone 20 mg IV every 12 h for 4 days, with rapid improvement of her complaints. At discharge, she was transitioned to a prednisone for a total of 40 mg daily, followed by a taper for 2.5 months. At 6-month follow up the patient reported a marked improvement in appetite, with resolution of her abdominal pain. She was tolerating an oral diet and had gained 6.8 kg (15 lb). A repeat endoscopy revealed a grossly normal stomach and duodenum (Figure 4). Repeat biopsies were normal. Written informed consent for patient information and images to be published was provided by the patient's legally authorized representative.

Discussion

Collagenous gastroenteritides encompass a broad subset of presentations, the best defined and studied being collagenous colitis, first described

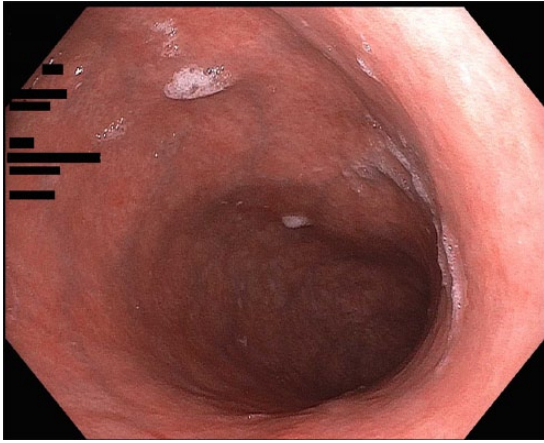


Figure 4. Esophagogastroduodenoscopy (EGD) poststeroid treatment revealing a normal stomach.

by Lindstrom in 1976.⁶ He described a case of a 48-year-old woman who presented with chronic diarrhea, normal endoscopic findings but with sub-epithelial collagen deposition on rectal biopsy.⁶ Since then, numerous case reports and case series of collagenous colitis have been published, helping us better understand its pathogenesis and clinical and histologic features, with recent studies suggesting that collagenous colitis is a relatively common cause of chronic diarrhea in adults.^{3,7,8}

Collagenous gastritis appears to be a far rarer entity. Patients with collagenous gastritis are generally children or young adults, with anemia and abdominal pain as the most common presentation. There is a predilection for women in all age group to have collagenous gastritis.⁵ The pathogenesis of this inflammatory process remains unknown. Adult collagenous gastritis may be associated with immune diseases such as lymphocytic gastritis, Sjogren syndrome, celiac disease and ulcerative colitis, suggesting that it may be a marker of a more extensive inflammatory disorder of the gastrointestinal tract in some cases.^{2,9,10} Rubio-Tapia and colleagues noted that olmesartan, an angiotensin II receptor antagonist used for hypertension, may be associated with a severe form of sprue-like enteropathy, when there was a marked weight gain in patients and a histologic improvement of the mucosa after discontinuation of olmesartan in all patients, including seven patients with collagenous gastritis.¹¹

Our patient presented at an advanced age with a presentation more typical among younger cases.

Since a colonoscopy was not clinically indicated, we cannot be certain whether there was any lower gastrointestinal involvement more common in older patients. Even if there was some undiagnosed collagenous colitis, the clinical presentation was still highly unusual for a geriatric case.

Collagenous gastritis is a histologic diagnosis. The endoscopic nodular and erythematous mucosal appearance is common in both adult and pediatric disease, although patients may have grossly normal appearing mucosa.^{2,5} The hallmark findings are plasma cell and lymphocytic infiltration of superficial and deep mucosa with thickened sub-epithelial collagen deposition greater than 10 μm along with entrapping dilated capillaries, usually more prevalent in the gastric body in pediatric patients and the antrum in adults.^{2,3,12} Kamimura and colleagues demonstrated that in collagenous gastritis, it is not the collagen deposition that causes the typical nodular appearance, but rather the glandular atrophy and collagen deposition caused by an uneven inflammation in the surrounding depressed mucosa.¹³ Collagenous colitis, in contrast, has more of an even distribution of inflammation throughout the mucosa, and as such changes seen are more homogeneous.^{13,14}

Specific therapy has not been well-established, and its prognosis and potential for endoscopic or histological resolution remains unclear. Collagen often persists for years, but may resolve histologically in a minority of patients. Lagorce-Pages and colleagues reported a complete absence of collagen deposit on repeat biopsy in a 40-year-old female treated with steroid.¹ However, in most reports, collagen deposits remain unchanged or become thicker as a result of continued inflammation.^{13,14} Anti-secretory agents including proton-pump inhibitor and H₂-receptor antagonists, steroids, iron supplementation, sucralfate, misoprostol, 5-aminosalicylate and gluten-free diet have previously been attempted, with limited success.^{1,14-18} Our patient fortunately experienced a total and rapid resolution of symptoms with steroid treatment superimposed upon a brief, apparently unsuccessful course of proton-pump inhibitor and sucralfate. The dose, tapering and duration of corticosteroid therapy was modeled on use for other inflammatory bowel diseases. While anecdotal, the success of this regimen may offer a reasonable starting point for treatment of similar cases.

Conclusion

Little is known about collagenous gastritis and its pathophysiology. There has not been a randomized control clinical trial to better allow us to understand its pathogenesis because of its rarity. The majority of descriptions in the literature are single-case reports, resulting in a lack of meaningful analysis on this curious conundrum. Future longitudinal studies are needed to investigate this pathophysiological distinctiveness. We believed we have described a rare case of collagenous gastritis that has sustained rapid symptom resolution after the use of steroids.

Funding

The author(s) received no financial support for the research, authorship, and/or publication of this article.

Conflict of interest statement

The author(s) declared no potential conflicts of interest with respect to the research, authorship, and/or publication of this article.

ORCID iD

Huei-Wen Lim  <https://orcid.org/0000-0002-6745-2277>

References

1. Lagorce-Pages C, Fabiani B, Bouvier R, *et al.* Collagenous gastritis: a report of six cases. *Am J Surg Pathol* 2001; 25: 1174–1179.
2. Vesoulis Z, Lozanski G, Ravichandran P, *et al.* Collagenous gastritis: a case report, morphologic evaluation, and review. *Mod Pathol* 2000; 13: 591–596.
3. Nielsen OH, Riis LB, Danese S, *et al.* Proximal collagenous gastroenteritides: clinical management. A systematic review. *Ann Med* 2014; 46: 311–317.
4. Colletti RB and Trainer TD. Collagenous gastritis. *Gastroenterology* 1989; 97: 1552–1555.
5. Kamimura K, Kobayashi M, Sato Y, *et al.* Collagenous gastritis: review. *World J Gastrointest Endosc* 2015; 7: 265–273.
6. Lindstrom CG. ‘Collagenous colitis’ with watery diarrhoea: a new entity? *Pathol Eur* 1976; 11: 87–89.
7. Williams JJ, Beck PL, Andrews CN, *et al.* Microscopic colitis: a common cause of diarrhoea in older adults. *Age Ageing* 2010; 39: 162–168.
8. Nielsen OH, Vainer B and Schaffalitzky de Muckadell OB. Microscopic colitis: a missed diagnosis? *Lancet* 2004; 364: 2055–2057.
9. Warren BF, Edwards CM and Travis SP. ‘Microscopic colitis’: classification and terminology. *Histopathology* 2002; 40: 374–376.
10. Stancu M, De Petris G, Palumbo TP, *et al.* Collagenous gastritis associated with lymphocytic gastritis and celiac disease. *Arch Pathol Lab Med* 2001; 125: 1579–1584.
11. Rubio-Tapia A, Herman ML, Ludvigsson JF, *et al.* Severe spruelike enteropathy associated with olmesartan. *Mayo Clin Proc* 2012; 87: 732–738.
12. Arnason T, Brown IS, Goldsmith JD, *et al.* Collagenous gastritis: a morphologic and immunohistochemical study of 40 patients. *Mod Pathol* 2015; 28: 533–544.
13. Kamimura K, Kobayashi M, Narisawa R, *et al.* Collagenous gastritis: endoscopic and pathologic evaluation of the nodularity of gastric mucosa. *Dig Dis Sci* 2007; 52: 995–1000.
14. Winslow JL, Trainer TD and Colletti RB. Collagenous gastritis: a long-term follow-up with the development of endocrine cell hyperplasia, intestinal metaplasia, and epithelial changes indeterminate for dysplasia. *Am J Clin Pathol* 2001; 116: 753–758.
15. Cote JF, Hankard GF, Faure C, *et al.* Collagenous gastritis revealed by severe anemia in a child. *Hum Pathol* 1998; 29: 883–886.
16. Dray X, Reignier S, Vahedi K, *et al.* Collagenous gastritis. *Endoscopy* 2007; 39: E292–E293.
17. Groisman GM, Meyers S and Harpaz N. Collagenous gastritis associated with lymphocytic colitis. *J Clin Gastroenterol* 1996; 22: 134–137.
18. Kori M, Cohen S, Levine A, *et al.* Collagenous gastritis: a rare cause of abdominal pain and iron-deficiency anemia. *J Pediatr Gastroenterol Nutr* 2007; 45: 603–606.