

2019

Touch preparation of skin biopsy specimen for rapid diagnosis of cutaneous *Nocardia nova* in the immunocompromised host

E. C. Traver

Zucker School of Medicine at Hofstra/Northwell

S. Husain

M. E. Grossman

Zucker School of Medicine at Hofstra/Northwell

Follow this and additional works at: <https://academicworks.medicine.hofstra.edu/publications>



Part of the [Dermatology Commons](#)

Recommended Citation

Traver EC, Husain S, Grossman ME. Touch preparation of skin biopsy specimen for rapid diagnosis of cutaneous *Nocardia nova* in the immunocompromised host. . 2019 Jan 01; 5(4):Article 4931 [p.].

Available from: <https://academicworks.medicine.hofstra.edu/publications/4931>. Free full text article.

This Article is brought to you for free and open access by Donald and Barbara Zucker School of Medicine Academic Works. It has been accepted for inclusion in Journal Articles by an authorized administrator of Donald and Barbara Zucker School of Medicine Academic Works. For more information, please contact academicworks@hofstra.edu.

Touch preparation of skin biopsy specimen for rapid diagnosis of cutaneous *Nocardia nova* in the immunocompromised host



Edward C. Traver, MD,^{a,b} Sameera Husain, MD,^c and Marc E. Grossman, MD,^{d,e}
Hempstead and New York, New York; Baltimore, Maryland; and New Haven, Connecticut

Key words: immunocompromised; *Nocardia nova*; touch preparation.

INTRODUCTION

Touch preparation is a simple bedside tool for the rapid diagnosis of cutaneous infections. We report an immunocompromised patient with disseminated nocardiosis and skin lesions diagnosed in less than an hour as *Nocardia nova* using touch preparation. Touch preparation can expedite diagnosis and treatment and may be especially useful for diagnosis of cutaneous infections in immunocompromised transplant patients.

CASE REPORT

A 60-year-old man with a history of myelodysplastic syndrome 15 months after undergoing a bone marrow transplant complicated by graft versus host disease that was treated with high-dose prednisone presented with acute onset left visual loss. The patient was also taking atovaquone, posaconazole, and valganciclovir for prophylaxis. An ophthalmic examination revealed vitritis, but anterior chamber paracentesis cultures and viral studies were negative. He was discharged on treatment-dose ganciclovir for presumed cytomegalovirus infection.

One month later the patient was readmitted with progressive symptoms and physical examination findings that were suggestive of endophthalmitis. Vitreous fluid cultures were performed. Magnetic resonance imaging of the brain and orbits revealed multiple supratentorial ring-enhancing lesions and enhancement of the left globus. He was treated with empiric intravenous linezolid, meropenem, voriconazole, and trimethoprim-sulfamethoxazole and

Abbreviations used:

AFB: acid-fast bacilli
 GMS: Gomori methenamine silver

intravitreal vancomycin, ceftazidime, and amphotericin. A computed tomography scan of the chest revealed left lung opacities. Bronchoscopy was performed. A transbronchial lung biopsy specimen was obtained, but staining with Gomori methenamine silver (GMS) stain or acid-fast bacilli (AFB) stain did not reveal any organisms. Nucleic acid amplification of a bronchiolar lavage sample identified *N nova* and *Klebsiella*, which was confirmed on standard culture.

On hospital day 6, dermatology was consulted for a skin lesion of 2 days' duration (Fig 1). An isolated 2-cm group of 3 red-brown papulonodules were present on the anterior surface of the right lower leg. Two 3-mm punch biopsy specimens were obtained, each in the center of a papulonodule. A touch preparation was performed at bedside by gently smearing the bottom of the biopsy specimen on a glass slide. The slide was dried and then stained with a modified acid-fast stain, which was decolorized with 1% sulfuric acid instead of acid alcohol (Fig 2). Microscopic examination of the touch preparation revealed abundant acid-fast branching filaments in a background of neutrophils, consistent with dissemination of *Nocardia* to the skin.

Histologic examination of the skin biopsy section stained with hematoxylin–eosin revealed suppurative

From the Zucker School of Medicine^a and the Department of Dermatology,^e Hofstra/Northwell, Hofstra University, Hempstead; University of Maryland School of Medicine,^b Baltimore; Department of Dermatology,^c Columbia University, New York; Department of Dermatology,^d Yale University School of Medicine, New Haven.

Funding sources: None.

Conflicts of interest: None disclosed.

Correspondence to: Edward C. Traver, MD, Department of Internal Medicine, University of Maryland Medical Center, 22 S Greene St, Baltimore, MD 21201. E-mail: etraver@som.umaryland.edu.

JAAD Case Reports 2019;5:389-91.
 2352-5126

© 2019 by the American Academy of Dermatology, Inc. Published by Elsevier, Inc. This is an open access article under the CC BY-NC-ND license (<http://creativecommons.org/licenses/by-nc-nd/4.0/>).

<https://doi.org/10.1016/j.jidcr.2019.02.010>

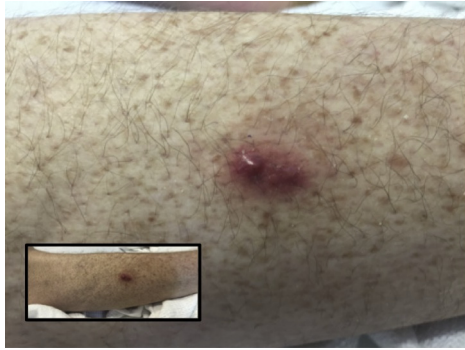


Fig 1. Red-brown papulonodules were present on the anterior surface of the right lower leg of a transplant patient for 2 days and diagnosed as cutaneous *Nocardia nova*. Inset, Wider view of the same leg.

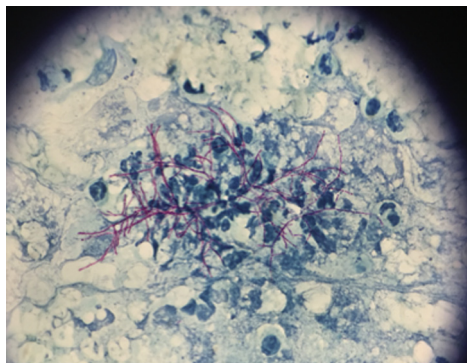


Fig 2. Touch preparation of a punch biopsy specimen of right lower leg papulonodules, prepared with modified acid-fast stain, revealed abundant acid-fast branching filaments in a background of neutrophils consistent with *Nocardia*. (Original magnification: $\times 40$.)

inflammation consistent with an abscess (Fig 3). Gram, modified acid-fast, AFB, and periodic acid–Schiff stains were negative for organisms. GMS stain of the biopsy revealed branching filamentous organisms throughout the reticular dermis and subcutis, consistent with *Nocardia* (Fig 3). Two weeks after initial dermatologic consultation, skin and vitreous fluid cultures all grew *N nova* (Fig 4).

Further questioning was conducted to determine possible exposures to *Nocardia*. The patient resided in suburban New Jersey and spent most of his time indoors. One month before symptom onset he had been outdoors while a tree on his property was trimmed and pulverized by a wood chipper. In addition, 4 months before admission, he had exco-riated his hand while gardening.

DISCUSSION

Nocardia are ubiquitous saprophytic Gram-positive branching filamentous bacteria of the

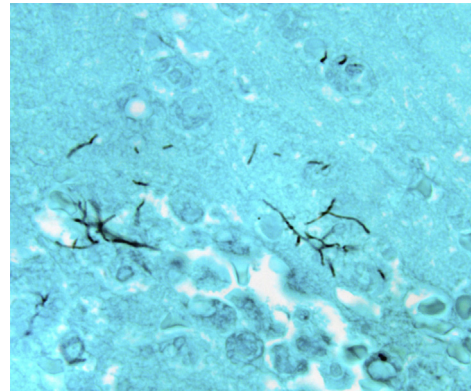


Fig 3. Gomori methenamine silver staining of a biopsy specimen obtained from right lower leg nodules revealed branching filamentous organisms consistent with *Nocardia*. (Original magnification: $\times 100$.)

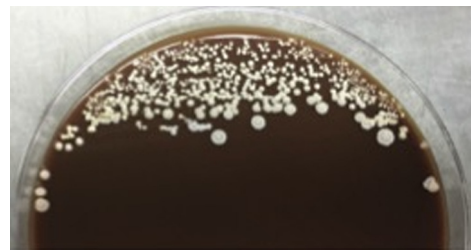


Fig 4. Fungal culture of the skin biopsy specimen revealed white cotton ball–like colonies on chocolate agar after 2 weeks of incubation, identified as *Nocardia nova*.

aerobic actinomyces family and are found in dirt, dust, organic matter, and sand. Most cases are acquired from the environment by inhalation or skin trauma from contaminated plants or tools; transmission from infected humans or other animals is rare. Cutaneous nocardiosis takes 4 forms: superficial skin infection, lymphocutaneous infection, mycetoma, or disseminated infection with skin involvement.^{1–3} Cutaneous *N nova* has been described in all 4 forms. Immunocompromised transplant patients are at increased risk for pulmonary and disseminated nocardiosis.⁴ *N nova* is the most frequently identified species in patients with bone marrow⁵ and solid organ⁶ transplants with nocardiosis.

The classification of *Nocardia* species has been recently refined and expanded using genetic identification with >50 recognized species, at least 33 of which cause disease in humans. *N nova* is a member of the *Nocardia asteroides* complex. Speciation, historically performed with biochemical analysis and antibiotic susceptibility profiling, is now performed primarily with genetic tests.⁷ Amplification and sequencing of the *hsp65* and *16S rRNA* genes

can rapidly identify the specific species and provides expected antibiotic susceptibility while awaiting cultures, which grow in 2 to 14 days.

Nocardia can be detected by microscopy, culture, and molecular tests. Microscopic examination of tissue and smears demonstrate fine, beaded, branching organisms on Gram and modified acid-fast stains.⁷ Gram staining is the most reliable because some organisms are not acid-fast, even within the same sample. In this case report, Gram, AFB, and modified acid-fast stains of the tissue were negative, but GMS stain was positive. This suggests that GMS should be performed in parallel with Gram and modified acid-fast stains if there is a suspicion of Nocardia.

Touch preparation has been described extensively in the oncologic literature as a diagnostic tool for solid and hematologic malignancies, but it can also be used to rapidly diagnose invasive cutaneous infections. The utility of touch preparations for rapid diagnosis of cutaneous infections has been reported in only 7 reports of 10 cases of 5 fungal infections⁸ and 2 parasite infections.^{9,10} The majority of these cases involved patients who were immunocompromised. It is possible that touch preparation is more successful in immunocompromised patients because larger numbers of organisms may proliferate in the skin and be more easily visualized.

Touch preparation can preliminarily diagnose many cutaneous infections and guide life-saving treatment. Bacterial infections especially may require further genetic, biochemical, and antibiotic sensitivity testing to confirm the diagnosis. In the case of Nocardia, a touch preparation of acid-fast branching filaments is relatively specific and can direct the laboratory toward more specific tests.

We described a case of disseminated *N nova* infection caused by nocardial pneumonia that was

likely acquired by inhalation of aerosolized plant material, which spread to involve the eye, brain, and skin. Cutaneous nocardiosis was diagnosed within 1 hour of examination of the patient by using the simple touch preparation technique that revealed characteristic acid-fast, branching filaments. The diagnosis was confirmed by skin biopsy histology and culture. *N nova* may be a more aggressive species of Nocardia with extensive dissemination in the immunocompromised host.

REFERENCES

1. Kalb RE, Kaplan MH, Grossman ME. Cutaneous nocardiosis. Case reports and review. *J Am Acad Dermatol*. 1985;13:125-133.
2. Shapiro PE, Grossman ME. Disseminated Nocardia asteroides with pustules. *J Am Acad Dermatol*. 1989;20:889-892.
3. Grossman ME, Fox LP, Kovarik C, Rosenbach M. *Cutaneous manifestations of infection in the immunocompromised host*. New York: Springer-Verlag; 2012.
4. Lebeaux D, Morelon E, Suarez F, et al. Nocardiosis in transplant recipients. *Eur J Clin Microbiol Infect Dis*. 2014;33:689-702.
5. Shannon K, Pasikhova Y, Ibekweh Q, Ludlow S, Baluch A. Nocardiosis following hematopoietic stem cell transplantation. *Transpl Infect Dis*. 2016;18:169-175.
6. Peleg AY, Husain S, Qureshi ZA, et al. Risk factors, clinical characteristics, and outcome of Nocardia infection in organ transplant recipients: a matched case-control study. *Clin Infect Dis*. 2007;44:1307-1314.
7. Brown-Elliott BA, Brown JM, Conville PS, Wallace RJ Jr. Clinical and laboratory features of the Nocardia spp. based on current molecular taxonomy. *Clin Microbiol Rev*. 2006;19:259-282.
8. Singer HM, Reddy BY, Grossman ME. Touch preparation for the rapid diagnosis of disseminated aspergillosis. *JAAD Case Rep*. 2017;3:202-204.
9. McGovern TW, Williams W, Fitzpatrick JE, Cetron MS, Hepburn BC, Gentry RH. Cutaneous manifestations of African trypanosomiasis. *Arch Dermatol*. 1995;131:1178-1182.
10. Berger RS, Perez-Figaredo RA, Spielvogel RL. Leishmaniasis: the touch preparation as a rapid means of diagnosis. *J Am Acad Dermatol*. 1987;16:1096-1105.