

2020

The Role of Chest Imaging in Patient Management during the COVID-19 Pandemic: A Multinational Consensus Statement from the Fleischner Society.

G. D. Rubin

C. J. Ryerson

L. B. Haramati

N. Sverzellati

J. P. Kanne

See next page for additional authors

Follow this and additional works at: <https://academicworks.medicine.hofstra.edu/publications>

 Part of the [Critical Care Commons](#)

Recommended Citation

Rubin GD, Ryerson CJ, Haramati LB, Sverzellati N, Kanne JP, Raoof S, Schluger NW, Volpi A, Yim J, Leung AN, . The Role of Chest Imaging in Patient Management during the COVID-19 Pandemic: A Multinational Consensus Statement from the Fleischner Society.. . 2020 Jan 01; 296(1):Article 6209 [p.]. Available from: <https://academicworks.medicine.hofstra.edu/publications/6209>. Free full text article.

This Article is brought to you for free and open access by Donald and Barbara Zucker School of Medicine Academic Works. It has been accepted for inclusion in Journal Articles by an authorized administrator of Donald and Barbara Zucker School of Medicine Academic Works. For more information, please contact academicworks@hofstra.edu.

Authors

G. D. Rubin, C. J. Ryerson, L. B. Haramati, N. Sverzellati, J. P. Kanne, S. Raof, N. W. Schluger, A. Volpi, J. Yim, A. N. Leung, and +10 additional authors

The Role of Chest Imaging in Patient Management during the COVID-19 Pandemic: A Multinational Consensus Statement from the Fleischner Society

Geoffrey D. Rubin, Department of Radiology, Duke University School of Medicine, Durham North Carolina	Christopher J. Ryerson, Department of Medicine, University of British Columbia, Vancouver, Canada
Linda B. Haramati, Department of Radiology, Montefiore Medical Center, Albert Einstein College of Medicine, Bronx, NY	Nicola Sverzellati, Scienze Radiologiche, Department of Medicine and Surgery, University of Parma, Parma Italy
Jeffrey P. Kanne, Department of Radiology, University of Wisconsin School of Medicine and Public Health, Madison, Wisconsin	Suhail Raouf, Division of <i>Pulmonary, Critical Care & Sleep Medicine</i> , Lenox Hill Hospital, New York, New York
Neil W. Schluger, Division of Pulmonary, Allergy and Critical Care Medicine, Columbia University Irving Medical Center, New York	Annalisa Volpi, 1st Anesthesia and Intensive Care Unit, University Hospital of Parma, Parma, Italy
Jae-Joon Yim, Division of Pulmonary and Critical Medicine, Seoul National University College of Medicine, Seoul, South Korea	Ian B. K. Martin, Department of Emergency Medicine The Medical College of Wisconsin School of Medicine, Milwaukee, WI
Deverick J. Anderson, Director, Duke Center for Antimicrobial Stewardship and Infection Prevention, Duke University Medical Center, Durham, NC	Christina Kong, Medical Director of Pathology and Clinical Laboratory Medicine, Stanford University Medical Center, Stanford, California
Talissa Altes, Department of Radiology, University of Missouri, Columbia, Missouri	Andrew Bush, Department of Paediatrics and Paediatric Respiriology, Royal Brompton Hospital, London, United Kingdom
Sujal R. Desai, Department of Radiology, Royal Brompton & Harefield NHS Foundation Trust, London AND National Heart and Lung Institute, Imperial College, London, United Kingdom	Jonathan Goldin, Department of Radiology, David Geffen School of Medicine at University of California Los Angeles
Jin Mo Goo, Department of Radiology, Seoul National University College of Medicine, Seoul, South Korea	Marc Humbert, Department of Respiratory and Intensive Care Medicine, Université Paris-Saclay, Hôpital Bicêtre, Le Kremlin-Bicêtre, France
Yoshikazu Inoue, Department of Pathology, National Hospital Organization Kinki-Chuo Chest Medical Center, Osaka, Japan	Hans-Ulrich Kauczor, Diagnostic and Interventional Radiology, University Hospital Heidelberg, Germany
Fengming Luo, Department of Pulmonary and Critical Care Medicine, West China Hospital, Sichuan University, China	Peter J. Mazzone, Respiratory Institute, Cleveland Clinic, Cleveland, Ohio
Mathias Prokop, Department of Radiology and Nuclear Medicine, Radboud University Medical Center, Nijmegen, the Netherlands	Martine Remy-Jardin, Department of Thoracic Imaging - Hospital Calmette, University Centre of Lille. Lille, France
Luca Richeldi, Division of Pulmonary Medicine, Università Cattolica del Sacro Cuore, Rome, Italy	Cornelia M. Schaefer-Prokop, Department of Radiology and Nuclear Medicine, Meander Medical Centre, Amersfoort, the Netherlands
Noriyuki Tomiyama, Department of Radiology, Osaka University Graduate School of Medicine, Osaka, Japan	Athol U. Wells, Department of Pulmonary Medicine, Royal Brompton Hospital, London, United Kingdom
Ann N. Leung, Department of Radiology, Stanford University School of Medicine, Stanford, California	

Address correspondence to G.D.R., Department of Radiology, Duke University School of Medicine, Box 3808 DUMC, Durham, NC 27710 (e-mail: *grubin@duke.edu*).

Essentials

- Imaging is not indicated in patients with suspected COVID-19 and mild clinical features unless they are at risk for disease progression.
- Imaging is indicated in a patient with COVID-19 and worsening respiratory status.
- In a resource-constrained environment, imaging is indicated for medical triage of patients with suspected COVID-19 who present with moderate-severe clinical features and a high pre-test probability of disease.

Article Type: Special Report

Abstract

With more than 900,000 confirmed cases worldwide and nearly 50,000 deaths during the first three months of 2020, the COVID-19 pandemic has emerged as an unprecedented healthcare crisis. The spread of COVID-19 has been heterogeneous, resulting in some regions having sporadic transmission and relatively few hospitalized patients with COVID-19 and others having community transmission that has led to overwhelming numbers of severe cases. For these regions, healthcare delivery has been disrupted and compromised by critical resource constraints in diagnostic testing, hospital beds, ventilators, and healthcare workers who have fallen ill to the virus exacerbated by shortages of personal protective equipment. While mild cases mimic common upper respiratory viral infections, respiratory dysfunction becomes the principal source of morbidity and mortality as the disease advances. Thoracic imaging with chest radiography (CXR) and computed tomography (CT) are key tools for pulmonary disease diagnosis and management, but their role in the management of COVID-19 has not been considered within the multivariable context of the severity of respiratory disease, pre-test probability, risk factors for disease progression, and critical resource constraints. To address this deficit, a multidisciplinary panel comprised principally of radiologists and pulmonologists from 10 countries with experience managing COVID-19 patients across a spectrum of healthcare environments evaluated the utility of imaging within three scenarios representing varying risk factors, community conditions, and resource constraints. Fourteen key questions, corresponding to 11 decision points within the three scenarios and three additional clinical situations, were rated by the panel based upon the anticipated value of the information that thoracic imaging would be expected to provide. The results were aggregated, resulting in five main and three additional recommendations intended to guide medical practitioners in the use of CXR and CT in the management of COVID-19.

Editor's note: This article is being simultaneously published in *Chest*.

© 2020 RSNA; American College of Chest Physicians, published by Elsevier Inc.

On March 11, 2020 the World Health Organization (WHO) officially characterized the rapid global spread of coronavirus disease 2019 (COVID-19) as a pandemic and called for urgent international action in four key areas: to prepare and be ready; detect, protect, and treat; reduce transmission; and innovate and learn (1). At the time of writing (April 1, 2020), there are over 900,000 confirmed COVID-19 cases and nearly 50,000 deaths in 205 countries around the world, with the majority of cases concentrated in 4 countries: United States, Italy, Spain, and China (2, 3). With sustained community transmission now established in multiple countries on multiple continents, the WHO public health goal has changed from containment to mitigation of the pandemic's impact. Consequently, strategies are now focused on efforts to reduce the incidence, morbidity, and mortality of COVID-19 by breaking the chain of human transmission through social distancing and imposed quarantine.

Diagnostic Testing

Early detection and containment of infection caused by the novel coronavirus SARS-CoV2 has been hindered by the need to develop, mass produce, and widely disseminate the required molecular diagnostic test, a real-time reverse transcriptase-polymerase chain reaction (RT-PCR) assay. Early reports of test performance in the Wuhan outbreak showed variable sensitivities ranging from 37% to 71% (4, 5). While laboratory-based performance evaluations of RT-PCR test show high analytical sensitivity and near-perfect specificity with no misidentification of other coronaviruses or common respiratory pathogens, test sensitivity in clinical practice may be adversely affected by a number of variables including: adequacy of specimen, specimen type, specimen handling, and stage of infection when the specimen is acquired (CDC guidelines for in-vitro diagnostics) (6, 7). False negative RT-PCR tests have been reported in patients with CT findings of COVID-19 who were eventually tested positive with serial sampling (8). Limited testing capacity due to insufficient specimen collection kits, lab test supplies, and testing equipment precluded early widespread testing and is believed to have contributed to rapid and unchecked transmission of infection within communities by undetected individuals with milder, limited, or no symptoms (9, 10). For example, CT screening of 82 asymptomatic individuals with confirmed COVID-19 from the cruise ship "Diamond Princess" showed findings of pneumonia in 54% (11).

Imaging Logistics During Pandemic

Provision of diagnostic imaging services to large numbers of patients suspected or confirmed to have COVID-19 during an outbreak can be challenging, as each study is lengthened and complicated by the need for strict adherence to infection control protocols designed to minimize risk of transmission and protect healthcare personnel (12). Droplet transmission followed by contaminated surfaces are believed to be the main modes of spread for SARS-CoV2 in radiology suites; all patients undergoing imaging should be masked and imaged using dedicated equipment that is cleaned and disinfected after each patient encounter (13). Although personal protection equipment (PPE) recommendations vary between countries, the current Centers of Disease Control (CDC) guidelines recommend radiology staff wear a mask, goggles or face shield, gloves, and an isolation gown. In countries with more stringent PPE protocols, a surgical cap and shoe covers may be added, while a surgical mask and goggles or face shield are suggested in some countries with less stringent PPE protocols (14). Additional precautions are required for specific situations that are more likely to generate aerosols, including patients receiving non-invasive ventilation, during intubation or extubation, throughout bronchoscopy, or when receiving nebulized therapies. Portable imaging, including imaging patients through glass walls, has been used in some hospitals to further reduce the chance of spreading infection.

Written from multidisciplinary and multinational perspectives, this Fleischner statement is intended to provide context for the use of imaging to direct patient management during the COVID-19 pandemic in different practice settings, different phases of epidemic outbreak, and environments of varying critical resource availability. This document is structured around three clinical scenarios and three additional situations in which chest imaging is often considered in the evaluation of patients with potential COVID-19 infection. The committee elected to present this document as a consensus statement rather than a guideline given the limited evidence base and the urgent need for direction on this topic for the medical community.

Methods

This Consensus Statement is based upon expert opinion amongst a panel of 15 thoracic radiologists, 10 pulmonologists/intensivists (including one anesthesiologist), and 1 pathologist, as well as additional experts in emergency medicine, infection control, and laboratory

medicine. The panel included individuals from the United States, Italy, China, Germany, France, United Kingdom, Netherlands, South Korea, Canada, and Japan, representing 9 of the 15 countries with the highest number of confirmed COVID-19 cases reported worldwide as of April 1, 2020 (2). The panel possessed experience managing patients during periods of local viral amplification and critical resource constraints in Wuhan China, Northern Italy, and New York City.

A subcommittee composed of five radiologists, four pulmonologists/intensivists (including one anesthesiologist), and one emergency medicine physician identified and iteratively developed three scenarios that illustrate imaging-related dilemmas occurring in common clinical presentations and across varying risk factors, community conditions, and resource constraints. These scenarios included 11 distinct nodes where imaging potentially provides clinically actionable information (**Figs 1, 2, 3**), with three additional situations identified in which chest imaging is also often considered (**Fig 4**). The entire panel was convened during a single session using a live audio and video interface (Zoom Video Communications, San Jose, CA). The three scenarios and three additional situations were presented, discussed, and refined. The panel independently and anonymously rated the appropriateness of imaging with chest radiography (CXR) or CT at each of these decision points on a five-point scale. At least 70% agreement on the direction of a recommendation was considered consensus. The scenarios are intended to support the management of adults only. Children, who are typically spared from severe infections (15), merit separate consideration, particularly with regard to use of radiation-associated procedures, and are beyond the scope of the current document.

The final document was supported by a comprehensive literature search for relevant articles. Using the search terms “((coronavirus OR COVID OR SARS-CoV OR *nCoV*) AND (CT OR Computed Tomography OR Radio* OR Imag*))”, a total of 137 English articles published between Dec 1, 2019 and March 23, 2020 were identified. Each article was assessed for relevance to the primary objective and a summary of key findings from relevant articles was created.

The Use of Imaging in COVID-19

The value of an imaging test relates to the generation of results that are clinically actionable either for establishing a diagnosis or for guiding management, triage, or therapy. That value is diminished by costs that include the risk of radiation exposure to the patient, risk of COVID-19 transmission to uninfected healthcare workers and other patients, consumption of PPE, and need for cleaning and downtime of radiology rooms in resource-constrained environments. The appropriate use of imaging in each of the scenarios was considered on this basis.

This statement focuses exclusively on the use of chest radiography (CXR) and computed tomography of the thorax (CT). While ultrasound has been suggested as a potential triage and diagnostic tool for COVID-19 given the predilection for the disease in subpleural regions, there is limited experience at this time (16), as well as infection control issues.

CXR is insensitive in mild or early COVID-19 infection (17). However, with respect to the relative value of CXR or CT for detecting the presence of viral pneumonia, the experience is vastly different dependent upon community norms and public health directives. When patients are encouraged to present early in the course of their disease, as was the case in Wuhan, China, CXR has little value. The greater sensitivity of CT for early pneumonic changes is more relevant in the setting of a public health approach that required isolation of all infected patients within an environment where the reliability of COVID-19 testing was limited and turnaround times were long (4). Alternatively, in New York City where patients were instructed to stay at home until they experienced advanced symptoms, CXR was often abnormal at the time of presentation. Equipment portability with imaging performed within an infected patient's isolation room is another factor that may favor CXR in selected populations, effectively eliminating the risk of COVID-19 transmission along the transport route to a CT scanner and within the room housing a CT scanner, particularly in environments lacking PPE. In hospitalized patients CXR can be useful for assessing disease progression and alternative diagnoses such as lobar pneumonia, suggestive of bacterial superinfection, pneumothorax and pleural effusion.

CT is more sensitive for early parenchymal lung disease, disease progression, and alternative diagnoses including acute heart failure from COVID-19 myocardial injury (18) and when

acquired with intravenous contrast material, pulmonary thromboembolism. Leveraging these superior capabilities depends upon the availability of CT capacity, particularly considering the potential reduction in CT scanner availability due to the additional time required to clean and disinfect equipment following imaging of patients with suspected COVID-19. Some centers rely on the improved depiction of COVID-19 findings with CT relative to CXR (19) and their association with clinical worsening to determine patient disposition to home, hospital admission, or intensive care. In recognition of variance amongst local practice patterns and resource availability, it is important to state at the outset that the scenarios specify the use of imaging but do *not* articulate the relative merit of CXR versus CT. Ultimately, the choice of imaging modality is left to the judgement of clinical teams at the point-of-care accounting for the differing attributes of CXR and CT, local resources, and expertise.

Overview of Clinical Scenarios

The scenarios apply only to patients presenting with features consistent with COVID-19 infection. The severity of respiratory disease and pre-test probability of COVID-19 infection are specified for each scenario, with additional key considerations including the presence of risk factors for disease progression, evidence of disease progression, and the presence of significant critical resource constraints (**Table 1**). The scenarios distinguish mild respiratory disease from moderate-to-severe respiratory disease based on the absence vs. presence of significant pulmonary dysfunction or damage. Pre-test probability is defined by the background prevalence of infection and can be estimated by observed transmission patterns: low by sporadic transmission; moderate by clustered transmission; and high by community transmission (20). Individual pre-test probability is further modified if there is known exposure through contact with a confirmed case of COVID-19 (21). For health care providers, the CDC categorizes medical-related exposures into low, medium, and high-risk groups (22). Within a diagnostic radiology department, brief (a few minutes or less) unprotected interaction with a patient with COVID-19 as well as prolonged close contact with a masked, infected patient by a medical provider wearing PPE are categorized as low-risk exposures (21, 22). Risk factors for poor outcomes in patients with COVID-19 infection are considered separately from pre-test

probability, with common risk factors including age > 65 years, cardiovascular disease, diabetes, chronic respiratory disease, hypertension, and immune-compromised (23). Identifying a patient as being at high risk for COVID-19 progression is not necessarily a feature of any single risk factor, but is rather a clinical judgement based on the combination of underlying comorbidities and general health status that suggests a higher level of clinical concern. Where appropriate, management variations based upon risk factors for disease progression are called out explicitly, as in Scenario 1. All clinical scenarios begin by characterizing COVID-19 status based upon the availability of laboratory test results.

Scenario 1: Mild Features of COVID-19

The first scenario (**Fig 1**) addresses a patient presenting for evaluation at an outpatient clinic or via telehealth with mild respiratory features consistent with COVID-19 infection, any pre-test probability of COVID-19 infection, and no significant critical resource constraints. When COVID-19 test results are unavailable, patients with moderate-to-high pre-test probability should be initially managed as if COVID-19 testing is positive, while patients with low pre-test probability should be initially managed as if COVID-19 testing is negative. Imaging is advised for patients with risk factors for COVID-19 progression and either positive COVID-19 testing or moderate-to-high pre-test probability in the absence of COVID-19 testing (**Fig 1, Q1**). Imaging provides a baseline for future comparison, may establish manifestations of important comorbidities in patients with risk factors for disease progression (**Table 1**), and may influence the intensity of monitoring for clinical worsening. Imaging is not advised for patients with mild features who are COVID-19 positive without accompanying risk factors for disease progression, or for patients with mild features who are COVID-19 negative (**Fig 1, Q2 & Q3**). The panel felt that the yield of imaging in these settings would be very low and that it was safe for most patients to self-monitor for clinical worsening. Regardless of COVID-19 test results and risk factors, imaging is advised for patients with mild clinical features who subsequently develop clinical worsening (**Fig 1, Q4 & Q5**). In the absence of clinical worsening, management involves support and isolation of patients with positive COVID-19 testing or patients with moderate to high pre-test probability without COVID-19 test results available.

Although not specifically addressed by this scenario, in the presence of significant resources constraints, there is no role for imaging of patients with mild features of COVID-19.

Scenario 2: Moderate to Severe Features of COVID-19

The second scenario (**Fig 2**) addresses a patient presenting with moderate-to-severe features consistent with COVID-19 infection, any pre-test probability of COVID-19 infection, and no significant critical resource constraints. Separate ratings were obtained for COVID-19 positive patients and either COVID-19 negative patients or patients for whom COVID-19 testing is unavailable (**Fig 2, Q6 & Q7**). Imaging is advised regardless of the results or availability of COVID-19 testing given the impact of imaging in both circumstances.

For COVID-19 positive patients, imaging establishes baseline pulmonary status and identifies underlying cardiopulmonary abnormalities that may facilitate risk stratification for clinical worsening. In the presence of clinical worsening, imaging is again advised to assess for COVID-19 progression or secondary cardiopulmonary abnormalities such as pulmonary embolism, superimposed bacterial pneumonia, or heart failure that can potentially be secondary to COVID-19 myocardial injury (**Fig 2, Q8**).

For COVID-19 negative patients or any patient for whom testing is not performed, imaging may reveal an alternative diagnosis to explain the patient's clinical features, which should direct patient care as per existing clinical guidelines or standard clinical practice. If an alternative diagnosis is not revealed or images demonstrate features of COVID-19 infection, then subsequent clinical evaluation would depend upon the pre-test probability of COVID-19 infection and COVID-19 test availability. Falsely negative COVID-19 testing is more prevalent in high pre-test probability circumstances and repeat COVID-19 testing is therefore advised if available. Depending upon the imaging findings, other clinical investigations may be pursued.

Scenario 3: Moderate-to-Severe Features of COVID-19 in a Resource Constrained Environment

The third scenario (**Fig 3**) addresses a patient presenting with moderate-to-severe features consistent with COVID-19 infection within an environment of high community disease burden and critical resource limitations as seen in Wuhan, China, in regions of Italy and Spain, and in New York City. Because healthcare personnel and infrastructure may be overwhelmed by a high influx of new patients and resources are limited to provide critical care, urgent decision-making and triage are of primary importance. At the time of this writing, turnaround times for COVID-19 test results range from 6 to over 48 hours with most sites waiting at least 12 hours for results. This is an impractically long time period to consider triage to limited hospital beds and ventilators. However, rapid point-of-care (PoC) COVID-19 tests are expected to be released into clinical environments during the first week of April 2020, providing routine turnaround times of less than an hour and potentially as little as 5 minutes (24-27). While the initial availability and sample processing capacity of PoC COVID-19 testing is expected to be limited, this should increase over time.

The third scenario first considers the potential availability of PoC COVID-19 testing. Imaging is advised when PoC COVID-19 testing is available and positive (**Fig 3, Q9**) for the same reasons as described for Scenario 2. Based upon imaging findings and clinical features, patients are subsequently supported and monitored with a level of intensity consistent with clinical features. Imaging is again indicated if patients subsequently clinically worsen (**Fig 3, Q11**).

Imaging is advised to support more rapid triage of patients in a resource-constrained setting when PoC COVID-19 testing is not available or negative (**Fig 3, Q10**). Imaging may reveal features of COVID-19, which within this scenario may be taken as a presumptive diagnosis of COVID-19 for medical triage and associated decisions regarding disposition, infection control, and clinical management. In this high pre-test probability environment, and as described for Scenario 2, the possibility of falsely negative COVID-19 testing creates a circumstance where a COVID-19 diagnosis may be presumed when imaging findings are strongly suggestive of COVID-

19 despite negative COVID-19 testing. This guidance represents a variance from other published recommendations which advise against the use of imaging for the initial diagnosis of COVID-19 (28) and was supported by direct experience amongst panelists providing care within the conditions described for this scenario. The relationship between disease severity and triage may need to be fluid depending upon resources and case load. When imaging reveals an alternative diagnosis to COVID-19, management is based upon established guidelines or standard clinical practice.

Additional Key Questions:

Daily chest radiographs are not indicated in stable intubated patients with COVID-19 (Q12)

Multiple studies have shown no difference in important outcomes (mortality, length of stay, and ventilator days) for intensive care unit patients imaged on-demand as compared to a daily routine protocol (29-32). Avoidance of non-value-added imaging is particularly important in the COVID-19 patient population to minimize exposure risk of radiology technologists and to conserve PPE.

CT scan is indicated in a patient who has functional impairment and/or hypoxemia after recovery from COVID-19 (Q13)

With the recent emergence of SARS-CoV2 as a human pathogen, there are no long-term follow-up studies of survivors. Postmortem evaluation of a single patient who succumbed to severe COVID-19 showed pathologic findings consistent with diffuse alveolar damage, similar to findings previously described with severe acute respiratory syndrome (SARS) and Middle East respiratory syndrome (MERS) (33). Patients with functional impairment following recovery from COVID-19 should undergo imaging to differentiate between expected morphologic abnormalities as sequelae of infection, mechanical ventilation, or both versus a different and potentially treatable process.

COVID-19 testing is indicated in a patient who is found incidentally to have typical findings of COVID-19 on a CT scan. (Q14)

While CT findings of COVID-19 infection are nonspecific, their presence in an asymptomatic patient with no or mild respiratory symptoms is concerning in a setting of known community transmission, particularly if there is no better alternative diagnosis. Asymptomatic carriers of COVID-19 have been estimated to comprise 17.9% - 33.3% of all infected cases (34, 35). Asymptomatic infection with suggestive CT findings in the lung has been documented in screened cruise ship passengers (11). It is believed that the presence of undetected infected and mildly symptomatic or asymptomatic individuals may be contributing to the rapid geographic spread of SARS-CoV2 (9). RT-PCR testing in this scenario is important to potentially identify an occult infection and limit further transmission both within the community and in the environment where the patient is receiving medical care. In highly prevalent areas, an additional uncertainty is whether CT should be used as a screening tool either as a stand-alone or as an adjunct to RT-PCR to exclude occult infection prior to surgery or intensive immunosuppressive therapies.

The panel's ratings are provided in **Figure 4**, and a summary of all recommendations is provided in **Table 2**.

Additional Resources

For purposes of image interpretation and reporting, readers are referred to a recently published systematic review of imaging findings of COVID-19 (36) and a multi-society consensus paper on reporting chest CT findings related to COVID-19 (37). As an aid to improving radiologist and pulmonologist familiarity with the imaging findings of COVID-19, we provide the following link (<https://www.fleischner-covid19.org>) to the Fleischner Society website where an educational repository of proven COVID-19 cases can be found.

Conclusion

This statement is intended to offer guidance to physicians on the use of thoracic imaging across a breadth of healthcare environments. It represents the collective opinions and perspectives of thoracic radiology, pulmonology, intensive care, emergency medicine, laboratory medicine, and infection control experts practicing in 10 countries, representative of the highest burden of COVID-19 worldwide. It also represents opinion at a moment in time within a highly-dynamic environment where the status of regional epidemics and the availability of critical resources to combat those epidemics vary daily. The evidence base supporting the use of imaging across the scenarios presented is scant and the advice presented herein may undergo refinement through rigorous scientific investigation, exposing nuances of image interpretation that may lead to prognostic information and guide management decisions. At the time of this writing, no therapy has been confirmed to alter the course of COVID-19, there is no known cure, and there is no vaccine for prevention. As effective treatments are developed, thoracic imaging may find new roles by establishing treatment response or characterizing patients as likely responders to novel therapies.

References

1. World Health Organization: Director-General's opening remarks at the media briefing on COVID-19 - 11 March 2020. <https://www.who.int/dg/speeches/detail/who-director-general-s-opening-remarks-at-the-media-briefing-on-covid-19---11-march-2020>. Updated March 11, 2020. Accessed April 1, 2020.
2. World Health Organization: Coronavirus disease (COVID-19) Situation Dashboard. <https://experience.arcgis.com/experience/685d0ace521648f8a5beeeee1b9125cd>. Updated April 1, 2020. Accessed April 1, 2020.
3. Johns Hopkins University: Coronavirus COVID-19 Global Cases by the Center for Systems Science and Engineering (CSSE). <https://gisanddata.maps.arcgis.com/apps/opsdashboard/index.html#/bda7594740fd40299423467b48e9ecf6>. Updated April 1, 2020. Accessed April 1, 2020.
4. Ai T, Yang Z, Hou H, Zhan C, Chen C, Lv W, Tao Q, Sun Z, Xia L. Correlation of Chest CT and RT-PCR Testing in Coronavirus Disease 2019 (COVID-19) in China: A Report of 1014 Cases. *Radiology* 2020;200642. doi: 10.1148/radiol.2020200642
5. Li Y, Yao L, Li J, Chen L, Song Y, Cai Z, Yang C. Stability Issues of RT-PCR Testing of SARS-CoV-2 for Hospitalized Patients Clinically Diagnosed with COVID-19. *J Med Virol* 2020. doi: 10.1002/jmv.25786
6. Wang W, Xu Y, Gao R, Lu R, Han K, Wu G, Tan W. Detection of SARS-CoV-2 in Different Types of Clinical Specimens. *JAMA : the journal of the American Medical Association* 2020. doi: 10.1001/jama.2020.3786
7. Zou L, Ruan F, Huang M, Liang L, Huang H, Hong Z, Yu J, Kang M, Song Y, Xia J, Guo Q, Song T, He J, Yen HL, Peiris M, Wu J. SARS-CoV-2 Viral Load in Upper Respiratory Specimens of Infected Patients. *N Engl J Med* 2020;382(12):1177-1179. doi: 10.1056/NEJMc2001737
8. Fang Y, Zhang H, Xie J, Lin M, Ying L, Pang P, Ji W. Sensitivity of Chest CT for COVID-19: Comparison to RT-PCR. *Radiology* 2020;200432. doi: 10.1148/radiol.2020200432
9. Li R, Pei S, Chen B, Song Y, Zhang T, Yang W, Shaman J. Substantial undocumented infection facilitates the rapid dissemination of novel coronavirus (SARS-CoV2). *Science* 2020. doi: 10.1126/science.abb3221
10. Rothe C, Schunk M, Sothmann P, Bretzel G, Froeschl G, Wallrauch C, Zimmer T, Thiel V, Janke C, Guggemos W, Seilmaier M, Drosten C, Vollmar P, Zwirgmaier K, Zange S, Wolfel R, Hoelscher M. Transmission of 2019-nCoV Infection from an Asymptomatic Contact in Germany. *N Engl J Med* 2020;382(10):970-971. doi: 10.1056/NEJMc2001468
11. Inui S, Fujikawa A, Jitsu M, Kunishima N, Watanabe S, Suzuki Y, Umeda S, Uwabe Y. Chest CT Findings in Cases from the Cruise Ship "Diamond Princess" with Coronavirus Disease 2019 (COVID-19). *Radiology: Cardiothoracic Imaging* 2020;2(2). doi: 10.1148/ryct.2020200110

12. Mossa-Basha M, Meltzer CC, Kim DC, Tuite MJ, Kolli KP, Tan BS. Radiology Department Preparedness for COVID-19: Radiology Scientific Expert Panel. *Radiology* 2020:200988. doi: 10.1148/radiol.2020200988
13. Kooraki S, Hosseiny M, Myers L, Gholamrezanezhad A. Coronavirus (COVID-19) Outbreak: What the Department of Radiology Should Know. *J Am Coll Radiol* 2020. doi: 10.1016/j.jacr.2020.02.008
14. Centers for Disease Control and Prevention: Coronavirus Disease 2019 (COVID-19) Interim Infection Prevention and Control Recommendations. <https://www.cdc.gov/coronavirus/2019-ncov/infection-control/control-recommendations.html#adhere>. Updated April 1, 2020. Accessed April 1, 2020.
15. Dong Y, Mo X, Hu Y, Qi X, Jiang F, Jiang Z, Tong S. Epidemiological Characteristics of 2143 Pediatric Patients With 2019 Coronavirus Disease in China. *Pediatrics* 2020. doi: 10.1542/peds.2020-0702
16. Soldati G, Smargiassi A, Inchingolo R, Buonsenso D, Perrone T, Briganti DF, Perlini S, Torri E, Mariani A, Mossolani EE, Tursi F, Mento F, Demi L. Is there a role for lung ultrasound during the COVID-19 pandemic? *J Ultrasound Med* 2020. doi: 10.1002/jum.15284
17. Wong HYF, Lam HYS, Fong AH, Leung ST, Chin TW, Lo CSY, Lui MM, Lee JCY, Chiu KW, Chung T, Lee EYP, Wan EYF, Hung FNI, Lam TPW, Kuo M, Ng MY. Frequency and Distribution of Chest Radiographic Findings in COVID-19 Positive Patients. *Radiology* 2020:201160. doi: 10.1148/radiol.2020201160
18. Driggin E, Madhavan MV, Bikdeli B, Chuich T, Laracy J, Bondi-Zoccai G, Brown TS, Nigoghossian C, Zidar DA, Haythe J, Brodie D, Beckman JA, Kirtane AJ, Stone GW, Krumholz HM, Parikh SA. Cardiovascular Considerations for Patients, Health Care Workers, and Health Systems During the Coronavirus Disease 2019 (COVID-19) Pandemic. *J Am Coll Cardiol* 2020. doi: 10.1016/j.jacc.2020.03.031
19. Orsi MA, Oliva AG, Cellina M. Radiology Department Preparedness for COVID-19: Facing an Unexpected Outbreak of the Disease. *Radiology* 2020. doi: 10.1148/radiol.2020201214
20. World Health Organization: Critical preparedness, readiness and response actions for COVID-19. <https://www.who.int/emergencies/diseases/novel-coronavirus-2019/technical-guidance/critical-preparedness-readiness-and-response-actions-for-covid-19>. Updated March 22, 2020. Accessed April 1, 2020.
21. Center for Disease Control and Prevention: Coronavirus Disease 2019 (COVID-19) Public Health Recommendations for Community-Related Exposure. <https://www.cdc.gov/coronavirus/2019-ncov/php/public-health-recommendations.html>. Updated March 30, 2020. Accessed April 1, 2020.
22. Center for Disease Control and Prevention: Interim U.S. Guidance for Risk Assessment and Public Health Management of Healthcare Personnel with Potential Exposure in a Healthcare Setting to Patients with Coronavirus Disease (COVID-19). <https://www.cdc.gov/coronavirus/2019-ncov/hcp/guidance-risk-assesment-hcp.html>. Updated March 7, 2020. Accessed April 1, 2020.

23. Wu Z, McGoogan JM. Characteristics of and Important Lessons From the Coronavirus Disease 2019 (COVID-19) Outbreak in China: Summary of a Report of 72314 Cases From the Chinese Center for Disease Control and Prevention. JAMA : the journal of the American Medical Association 2020. doi: 10.1001/jama.2020.2648
24. DiaSorin Molecular: Simplexa COVID-19 Direct Kit. <https://molecular.diasorin.com/us/kit/simplexa-covid-19-direct-kit/>. Accessed April 1, 2020.
25. bioMérieux: First of 3 diagnostic tests for SARS-CoV-2 coronavirus available from bioMérieux. <https://www.biomerieux.com/en/novel-coronavirus-covid-19>. Updated March 11, 2020. Accessed April 1, 2020.
26. Cepheid: Xpert® Xpress SARS-CoV-2 has received FDA Emergency Use Authorization. <https://www.cepheid.com/coronavirus>. Accessed April 1, 2020.
27. Abbott: ID NOW COVID-19 Molecular. In minutes. On the front line. <https://www.alere.com/en/home/product-details/id-now-covid-19.html>. Accessed April 1, 2020.
28. American College of Radiology: ACR Recommendations for the use of Chest Radiography and Computed Tomography (CT) for Suspected COVID-19 Infection. <https://www.acr.org/Advocacy-and-Economics/ACR-Position-Statements/Recommendations-for-Chest-Radiography-and-CT-for-Suspected-COVID19-Infection>. Updated March 22, 2020. Accessed April 1, 2020.
29. Oba Y, Zaza T. Abandoning daily routine chest radiography in the intensive care unit: meta-analysis. Radiology 2010;255(2):386-395. doi: 10.1148/radiol.10090946
30. Hejblum G, Chalumeau-Lemoine L, loos V, Boelle PY, Salomon L, Simon T, Vibert JF, Guidet B. Comparison of routine and on-demand prescription of chest radiographs in mechanically ventilated adults: a multicentre, cluster-randomised, two-period crossover study. Lancet 2009;374(9702):1687-1693. doi: 10.1016/S0140-6736(09)61459-8
31. Lakhal K, Serveaux-Delous M, Lefrant JY, Capdevila X, Jaber S, AzuRea network for the RadioDay study g. Chest radiographs in 104 French ICUs: current prescription strategies and clinical value (the RadioDay study). Intensive Care Med 2012;38(11):1787-1799. doi: 10.1007/s00134-012-2650-9
32. Suh RD, Genshaft SJ, Kirsch J, Kanne JP, Chung JH, Donnelly EF, Ginsburg ME, Heitkamp DE, Henry TS, Kazerooni EA, Ketai LH, McComb BL, Ravenel JG, Saleh AG, Shah RD, Steiner RM, Mohammed TL. ACR Appropriateness Criteria(R) Intensive Care Unit Patients. Journal of thoracic imaging 2015;30(6):W63-65. doi: 10.1097/RTI.0000000000000174
33. Xu Z, Shi L, Wang Y, Zhang J, Huang L, Zhang C, Liu S, Zhao P, Liu H, Zhu L, Tai Y, Bai C, Gao T, Song J, Xia P, Dong J, Zhao J, Wang FS. Pathological findings of COVID-19 associated with acute respiratory distress syndrome. The lancet Respiratory medicine 2020. doi: 10.1016/S2213-2600(20)30076-X

34. Mizumoto K, Kagaya K, Zarebski A, Chowell G. Estimating the asymptomatic proportion of coronavirus disease 2019 (COVID-19) cases on board the Diamond Princess cruise ship, Yokohama, Japan, 2020. *Euro Surveill* 2020;25(10). doi: 10.2807/1560-7917.ES.2020.25.10.2000180
35. Nishiura H, Kobayashi T, Suzuki A, Jung SM, Hayashi K, Kinoshita R, Yang Y, Yuan B, Akhmetzhanov AR, Linton NM, Miyama T. Estimation of the asymptomatic ratio of novel coronavirus infections (COVID-19). *Int J Infect Dis* 2020. doi: 10.1016/j.ijid.2020.03.020
36. Salehi S, Abedi A, Balakrishnan S, Gholamrezanezhad A. Coronavirus Disease 2019 (COVID-19): A Systematic Review of Imaging Findings in 919 Patients. *AJR American journal of roentgenology* 2020:1-7. doi: 10.2214/AJR.20.23034
37. Simpson S, Kay FU, Abbara A, Bhalla S, Chung JH, Chung M, Henry TS, Kanne JP, Kligerman S, Ko JP, Litt H. Radiological Society of North America Expert Consensus Statement on Reporting Chest CT Findings Related to COVID-19. Endorsed by the Society of Thoracic Radiology, the American College of Radiology, and RSNA. *Radiology: Cardiothoracic Imaging* 2020;2(2). doi: 10.1148/ryct.2020200152

Table 1. Definitions and Criteria for Key Components of Common Clinical Scenarios

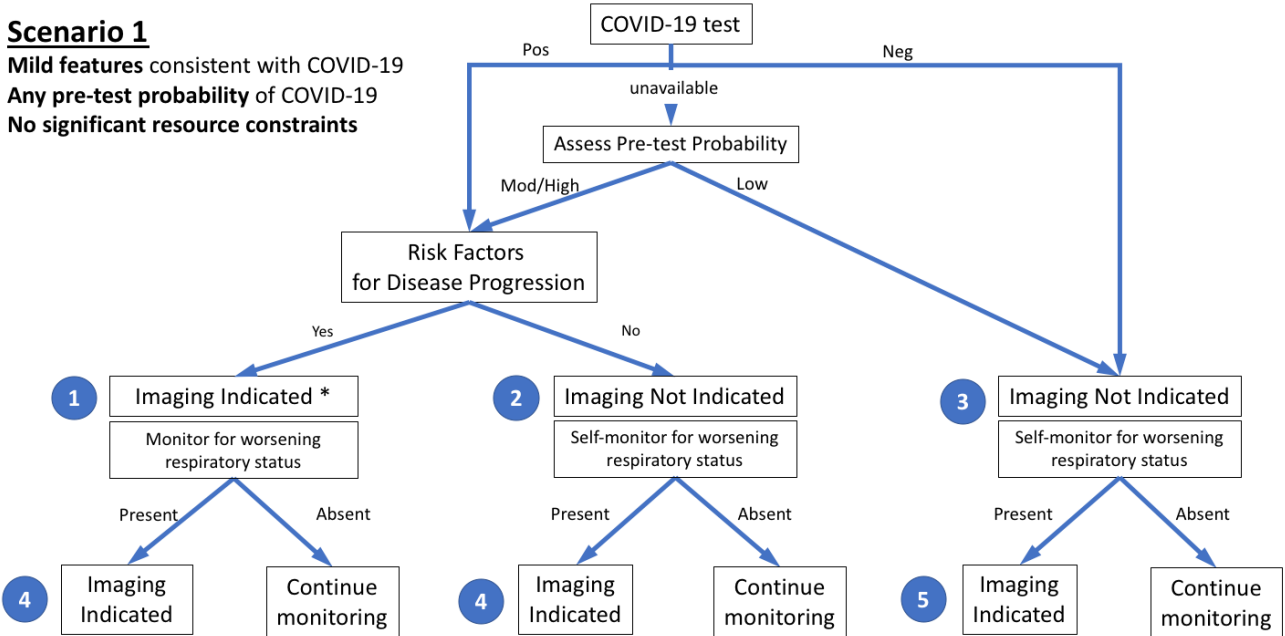
Definitions and criteria for key components of common clinical scenarios
Severity of respiratory disease
<input type="checkbox"/> Mild: No evidence of significant pulmonary dysfunction or damage (e.g., absence of hypoxemia, no or mild dyspnea)
<input type="checkbox"/> Moderate-to-severe: Evidence of significant pulmonary dysfunction or damage (e.g., hypoxemia, moderate-to-severe dyspnea)
Pre-test probability
<input type="checkbox"/> Based upon background prevalence of disease as estimated by observed transmission patterns. May be further modified by individual’s exposure risk. Sub-categorized as:
<input type="radio"/> Low: Sporadic transmission
<input type="radio"/> Medium: Clustered transmission
<input type="radio"/> High: Community transmission
Risk factors for disease progression
<input type="checkbox"/> Present: Clinical judgement regarding combination of age > 65 years and presence of comorbidities (e.g., cardiovascular disease, diabetes, chronic respiratory disease, hypertension, immune-compromised)
<input type="checkbox"/> Absent: Defined by the absence of risk factors for disease progression
Disease progression
<input type="checkbox"/> Progression of mild disease to moderate-to-severe disease as defined above.
<input type="checkbox"/> Progression of moderate-to-severe disease with worsening objective measures of hypoxemia.
Resource constraints
<input type="checkbox"/> Limited access to personnel, personal protective equipment, COVID-19 testing ability (including swabs, reagent, or personnel), hospital beds, and/or ventilators with the need to rapidly triage patients.

Table 2. Summary of Recommendations for Imaging

Summary of Recommendations for Imaging
Main Recommendations
<input type="checkbox"/> Imaging is not routinely indicated as a screening test for COVID-19 in asymptomatic individuals
<input type="checkbox"/> Imaging is not indicated for patients with mild features of COVID-19 unless they are at risk for disease progression (Scenario 1)
<input type="checkbox"/> Imaging is indicated for patients with moderate to severe features of COVID-19 regardless of COVID-19 test results (Scenarios 2 and 3)
<input type="checkbox"/> Imaging is indicated for patients with COVID-19 and evidence of worsening respiratory status (Scenarios 1, 2, and 3)
<input type="checkbox"/> In a resource constrained environment where access to CT is limited, CXR may be preferred for patients with COVID-19 unless features of respiratory worsening warrant the use of CT (Scenarios 2 and 3)
Additional Recommendations
<input type="checkbox"/> Daily chest radiographs are NOT indicated in stable intubated patients with COVID-19
<input type="checkbox"/> CT is indicated in patients with functional impairment and/or hypoxemia after recovery from COVID-19
<input type="checkbox"/> COVID-19 testing is indicated in patients incidentally found to have findings suggestive of COVID-19 on a CT scan

Scenario 1

Mild features consistent with COVID-19
Any pre-test probability of COVID-19
No significant resource constraints



* Clinical judgement should dictate the use of imaging through consideration of patient risk factors and local resources.

Figure 1: The first of three clinical scenarios presented to the panel with final recommendations. Mild features refer to absence of significant pulmonary dysfunction or damage. Pre-test probability is based upon background prevalence of disease and may be further modified by individual’s exposure risk. The absence of resource constraints corresponds to sufficient availability of personnel, personal protective equipment, COVID-19 testing, hospital beds, and/or ventilators with the need to rapidly triage patients. Numbers in blue circles indicate key questions referenced in the text and presented in Figure 4. Contextual detail and considerations for imaging with CXR (chest radiography) versus CT (computed tomography) are presented in the text. (Pos=positive, Neg=negative, Mod=moderate). [Although not covered by this scenario and not shown in the figure, in the presence of significant resources constraints, there is no role for imaging of patients with mild features of COVID-19.]

Scenario 2

Moderate to severe features consistent with COVID-19

Any pre-test probability of COVID-19

No significant resource constraints

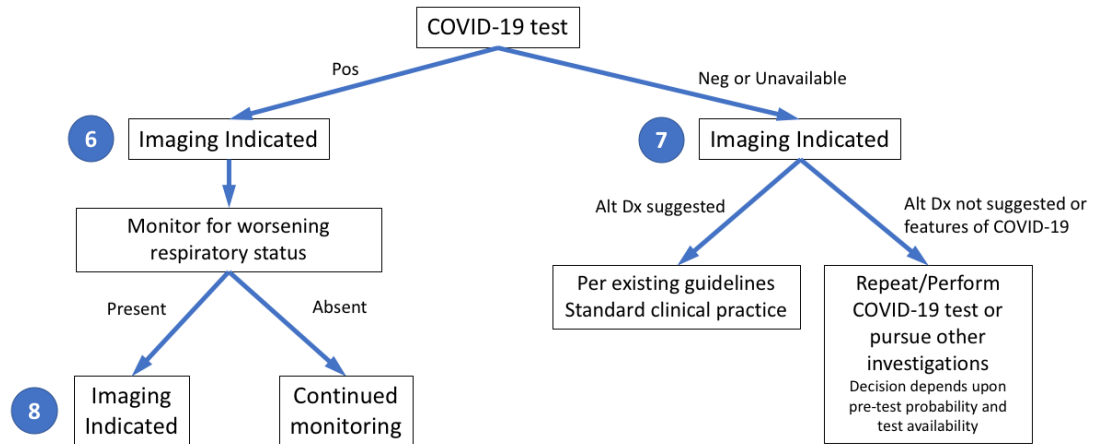


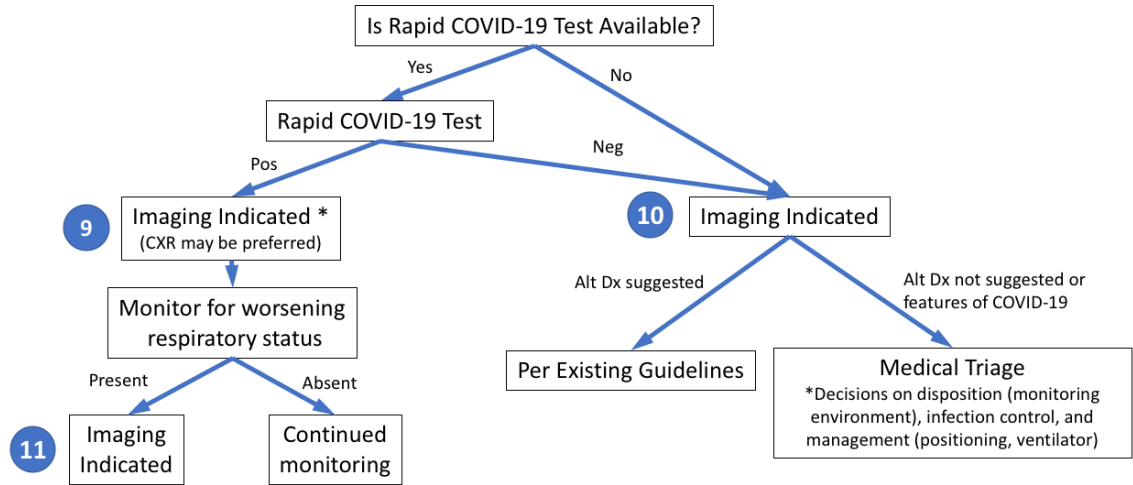
Figure 2: The second of three clinical scenarios presented to the panel with final recommendations. Moderate-to-severe features refer to evidence of significant pulmonary dysfunction or damage. Pre-test probability is based upon background prevalence of disease and may be further modified by individual’s exposure risk. The absence of resource constraints corresponds to sufficient availability of personnel, personal protective equipment, COVID-19 testing, hospital beds, and/or ventilators with the need to rapidly triage patients. Numbers in blue circles indicate key questions referenced in the text and presented in Figure 4. Contextual detail and considerations for imaging with CXR (chest radiography) versus CT (computed tomography) are presented in the text. (Pos=positive, Neg=negative, Alt Dx=alternate diagnosis).

Scenario 3

Moderate to severe features consistent with COVID-19

High pre-test probability of COVID-19

Resource constrained (Need for urgent patient triage due to lack of resources – beds, ventilators, medical personnel, PPE, COVID tests)



* Lower priority if severely resource constrained, relative to 10 or 11.

Figure 3: The third of three clinical scenarios presented to the panel with final recommendations. Moderate-to-severe features refer to evidence of significant pulmonary dysfunction or damage. High pre-test probability is based upon high background prevalence of disease associated with community transmission. Rapid COVID-19 test is a point-of-care test with a less than one-hour turnaround time. Numbers in blue circles indicate key questions referenced in the text and presented in Figure 4. Contextual detail and considerations for imaging with CXR (chest radiography) versus CT (computed tomography) are presented in the text. (Pos=positive, Neg=negative, Alt Dx=alternate diagnosis).

Key questions	Proportion of committee members	Summary
1 Is imaging indicated in a patient with mild features, a positive COVID-19 test, and risk factors for disease progression?		71% in favor
2 Is imaging indicated in a patient with mild features, a positive COVID-19 test, and no risk factors for disease progression?		77% against
3 Is imaging indicated in a patient with mild features consistent with COVID-19 and a negative COVID-19 test?		88% against
4 Is imaging indicated in a patient with a positive COVID-19 test and mild features who subsequently has clinical worsening?		96% in favor
5 Is imaging indicated in a patient with a negative COVID-19 test and mild features who subsequently has clinical worsening?		96% in favor
6 Is imaging indicated in a hospitalized patient with moderate-severe features and positive COVID-19 test?		92% in favor
7 Is imaging indicated in a hospitalized patient with moderate-severe features consistent with COVID-19 and a negative COVID-19 test?		100% in favor
8 Is imaging indicated in a hospitalized patient with moderate-severe features and positive COVID-19 test who subsequently has clinical worsening?		93% in favor
9 In a resource-constrained environment, is imaging indicated in a patient who presents with moderate-severe features and a positive COVID-19 test?		76% in favor
10 In a resource-constrained environment without a PoC COVID-19 test available, is imaging indicated in the medical triage of patients who present to the emergency room with moderate-severe features consistent with COVID-19?		89% in favor
11 In a resource-constrained environment, is imaging indicated in a hospitalized patient with a positive COVID-19 test who subsequently has clinical worsening?		96% in favor
12 Are daily chest radiographs indicated in stable intubated patients with COVID-19?		83% against
13 Is CT indicated in a patient who has a residual functional impairment and/or hypoxemia after recovery from COVID-19?		88% in favor
14 Is COVID-19 testing indicated in a patient who is incidentally found to have findings suggestive of COVID-19 on a CT scan?		100% in favor

Legend: ■ Strongly against ■ Weakly against ■ Neutral ■ Weakly in favor ■ Strongly in favor

Figure 4: Panel members (total n=27) developed 14 key questions (numerals in left column correspond to question numbers in text and Figures 1-3) that were used to support creation of common scenarios and recommendations related to the use of chest imaging in patients with features of COVID-19. The proportion of panel member votes for each question is presented on a 5-point scale, as well as a summary column that shows the total percentage who voted for or against imaging for each key question, excluding those members who were neutral or who abstained (1 panel member abstained for questions 1 and 2).