

2020

Obstructive lung disease secondary to compression of the bronchus by an enlarged pulmonary artery

J. Panthappattu

V. Sharma

S. Verma

A. Talwar

Zucker School of Medicine at Hofstra/Northwell

Follow this and additional works at: <https://academicworks.medicine.hofstra.edu/publications>



Part of the [Internal Medicine Commons](#)

Recommended Citation

Panthappattu J, Sharma V, Verma S, Talwar A. Obstructive lung disease secondary to compression of the bronchus by an enlarged pulmonary artery. . 2020 Jan 01; 37(2):Article 6243 [p.]. Available from: <https://academicworks.medicine.hofstra.edu/publications/6243>. Free full text article.

This Article is brought to you for free and open access by Donald and Barbara Zucker School of Medicine Academic Works. It has been accepted for inclusion in Journal Articles by an authorized administrator of Donald and Barbara Zucker School of Medicine Academic Works. For more information, please contact academicworks@hofstra.edu.



Lung India. 2020 Mar-Apr; 37(2): 158–160.

Published online 2020 Feb 27.

doi: 10.4103/lungindia.lungindia_436_19; 10.4103/lungindia.lungindia_436_19

PMCID: PMC7065542

PMID: [32108602](https://pubmed.ncbi.nlm.nih.gov/32108602/)

Obstructive lung disease secondary to compression of the bronchus by an enlarged pulmonary artery

[Justin Panthappattu](#),¹ [Vidhu Sharma](#),² [Sameer Verma](#),^{2,3} and [Arunabh Talwar](#)^{2,3}

¹*St. George's University School of Medicine, Grenada, West Indies*

²*Northwell Health, Department of Pulmonary, Critical Care and Sleep Medicine, New Hyde Park, NY, USA*

³*Heart and Lung Research Unit, The Feinstein Institute for Medical Research, Manhasset, NY, USA*

Address for correspondence: Dr. Arunabh Talwar, Northwell Health, Department of Pulmonary, Critical Care and Sleep Medicine, 410 Lakeville Road, Suite 107 New Hyde Park, NY 11040, USA. E-mail:

arunabhtalwar1@gmail.com

Received 2019 Sep 16; Accepted 2019 Sep 30.

[Copyright](#) : © 2020 Indian Chest Society

This is an open access journal, and articles are distributed under the terms of the Creative Commons Attribution-NonCommercial-ShareAlike 4.0 License, which allows others to remix, tweak, and build upon the work non-commercially, as long as appropriate credit is given and the new creations are licensed under the identical terms.

Abstract

In clinical practice, the presence of wheezing generally indicates an airway disease. In rare circumstances, adjacent mediastinal structures may compress the tracheobronchial tree leading to obstructive physiology. Compression of the tracheobronchial region by an enlarged pulmonary artery (PA) is exceedingly rare. We present here a case of pulmonary hypertension, where the enlarged PA resulted in obstructive lung physiology with a relevant review of the literature.

KEY WORDS: Bronchial compression, intrathoracic obstruction, obstructive lung disease, pulmonary artery dilatation, pulmonary hypertension

INTRODUCTION

Diseases of the airways present with airflow limitation leading to obstructive lung physiology. Rarely, problems outside of the conducting airways can lead to such a phenomenon. Airway compression by enlarged blood vessels is one such cause.^[1] We present here a case of dynamic right mainstem bronchus compression caused by the enlargement of the pulmonary artery (PA) in a patient with pulmonary hypertension (PHTN).

CASE REPORT

A nonsmoking 74-year-old male with a history of pulmonary embolism was evaluated for dyspnea on exertion and cough. On examination, he was hemodynamically stable, with a room air saturation of 88%. On examination, he had wheezing in both lower lung posterior hemithoraces but was more pronounced on

the right side. Echocardiogram showed pulmonary arterial systolic pressure of 65 mmHg. His 6-min walk test was 317 m. Right heart catheterization showed right atrial pressure of 13 mmHg; mean pulmonary arterial pressure of 44 mmHg; mean pulmonary arterial wedge pressure of 14 mmHg; cardiac output of 2.65 L/min; and pulmonary vascular resistance of 11.32 wood units.

Spirometry showed an obstructive pattern [Table 1]. The flow-volume loop also showed flattening in the expiratory phase [Figure 1]. Computed tomography (CT) angiography showed an enlarged PA measuring 7 cm with compression of the right mainstem bronchus by the right PA [Figure 2]. Therapeutic stenting of the airway was entertained; however, he was deemed a high-risk surgical candidate. Instead, we continued medical management and follow-up.

DISCUSSION

This case outlines a rare cause of dyspnea in a patient with pulmonary arterial hypertension with enlarged PA or its branches causing airflow limitation due to extrinsic compression of the airways.

Enlargement in thoracic vascular structures is a known cause of airway compression, which can be classified as congenital or acquired.[1] Congenital vascular malformations causing extrinsic airway obstruction are common in children.[1] In this population, airway cartilage is more elastic and hence susceptible to compression. Acquired vascular malformations leading to tracheobronchial compression are more common in adults. Severe aortic aneurysm secondary to atherosclerosis is the most common cause of bronchial compression in this clinical setting.[2]

PHTN is associated with PA dilatation.[3] The scenario of enlarged PA associated with congenital heart disease likely leading to tracheobronchial compression has been well documented in children.[4] However, pulmonary arterial hypertension with enlarged PA leading to tracheobronchial compression with symptoms of wheezing in adults is distinctively rare. After a review of the literature, we found seven cases of symptomatic bronchial compression by an enlarged PA (averaging approximately 73.67 mm) [Table 2]. In each of these cases, a patient with PHTN was diagnosed and had dyspnea that was unresponsive to treatment. Further investigation identified an enlarged PA with associated bronchial compression.

Vascular bronchial compression may be misdiagnosed with asthma because of shared presenting symptoms of dyspnea and cough.[5] Chest X-ray is an initial test in patients with respiratory complaints. However, its usefulness is limited in cases of vascular airway compression as the only abnormality seen on a chest X-ray may be mediastinal widening. Pulmonary function tests are a more accurate diagnostic test. The flow-volume loop in bronchial compression may show a characteristic expiratory flattening, as seen in this case [Figure 1]. During expiration, the pleural pressure becomes positive relative to intra-airway pressure. In the presence of external compression, this difference is amplified and is reflected by end-expiratory loop flattening representing variable intrathoracic obstruction.[2] CT angiography is considered the gold standard for defining the vasculature and the spatial relationship between the vessels and the airways. This modality can be combined with bronchoscopy.[1] After identifying the cause, treatment of the lesion is typically attempted by surgical decompression of the vascular abnormality or airway stenting. Although airway stenting in such cases appears to be an attractive alternative as is that it is less invasive, there is always a risk of wall erosion by the stent hence it has not been much reported in these cases.[1] Surgical interventions to relieve the extrinsic airway compression are of high risk in patients with PHTN. [9]

CONCLUSION

Wheezing in patients can occur from many causes. In patients with PHTN, the cause of wheezing may be the first indication of compression of the tracheobronchial tree from an enlarged PA.

Declaration of patient consent

The authors certify that they have obtained all appropriate patient consent forms. In the form the patient(s) has/have given his/her/their consent for his/her/their images and other clinical information to be reported in the journal. The patients understand that their names and initials will not be published and due efforts will be made to conceal their identity, but anonymity cannot be guaranteed.

Financial support and sponsorship

Nil.

Conflicts of interest

There are no conflicts of interest.

REFERENCES

1. Kanabuchi K, Noguchi N, Kondo T. Vascular tracheobronchial compression syndrome in adults: A review. *Tokai J Exp Clin Med.* 2011;36:106–11. [PubMed: 22167491]
2. Jaijee SK, Ariff B, Howard L, O'Regan DP, Gin-Sing W, Davies R, et al. Left main bronchus compression due to main pulmonary artery dilatation in pulmonary hypertension: Two case reports. *Pulm Circ.* 2015;5:723–5. [PMCID: PMC4671747] [PubMed: 26697180]
3. Badagliacca R, Poscia R, Pezzuto B, Papa S, Nona A, Mancone M, et al. Pulmonary arterial dilatation in pulmonary hypertension: Prevalence and prognostic relevance. *Cardiology.* 2012;121:76–82. [PubMed: 22433455]
4. Bové T, Demanet H, Casimir G, Viart P, Goldstein JP, Deuvaert FE. Tracheobronchial compression of vascular origin. Review of experience in infants and children. *J Cardiovasc Surg (Torino)* 2001;42:663–6. [PubMed: 11562597]
5. Achouh L, Montani D, Garcia G, Jaïs X, Hamid AM, Mercier O, et al. Pulmonary arterial hypertension masquerading as severe refractory asthma. *Eur Respir J.* 2008;32:513–6. [PubMed: 18669791]
6. Morjaria S, Grinnan D, Voelkel N. Massive dilatation of the pulmonary artery in association with pulmonic stenosis and pulmonary hypertension. *Pulm Circ.* 2012;2:256–7. [PMCID: PMC3401880] [PubMed: 22837867]
7. Arimura FE, Santiago RS, Gavilanes F, et al. Idiopathic pulmonary arterial hypertension leading to dynamic bronchial compression and orthopnea: a case report of the use of electrical impedance tomography (eit) as a new investigation tool in pulmonary function test. *Am J Resp Crit Care.* 2015;191:Abstract.
8. Nokes B, Jensen EA, Cartin-Ceba R. Unusual cause of severe airflow limitation in a patient with Eisenmenger syndrome. *Am J Respir Crit Care Med.* 2019;199:e33–4. [PubMed: 30383401]
9. Ramakrishna G, Sprung J, Ravi BS, Chandrasekaran K, McGoon MD. Impact of pulmonary hypertension on the outcomes of noncardiac surgery: Predictors of perioperative morbidity and mortality. *J Am Coll Cardiol.* 2005;45:1691–9. [PubMed: 15893189]

Figures and Tables

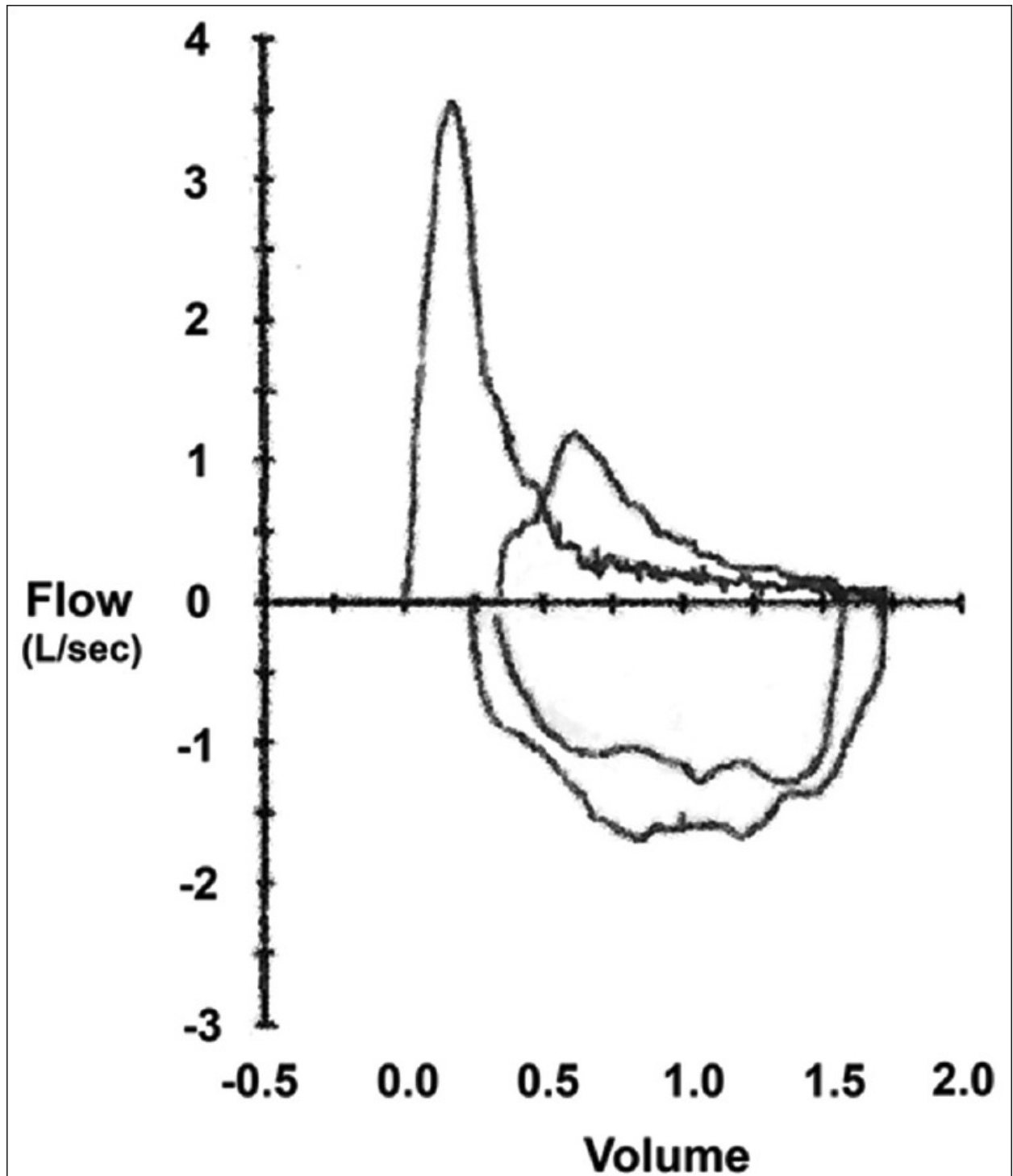
Table 1

Spirometry measurements

	Reference Values	LLN-ULN	Measured values	Percentage predicted
FEV1 (L)	2.76	2.0-3.5	0.70	25.36
FVC (L)	3.81	3.0-4.7	1.73	45.41
FEV1/FVC (%)	73	63.3-82.7	41	

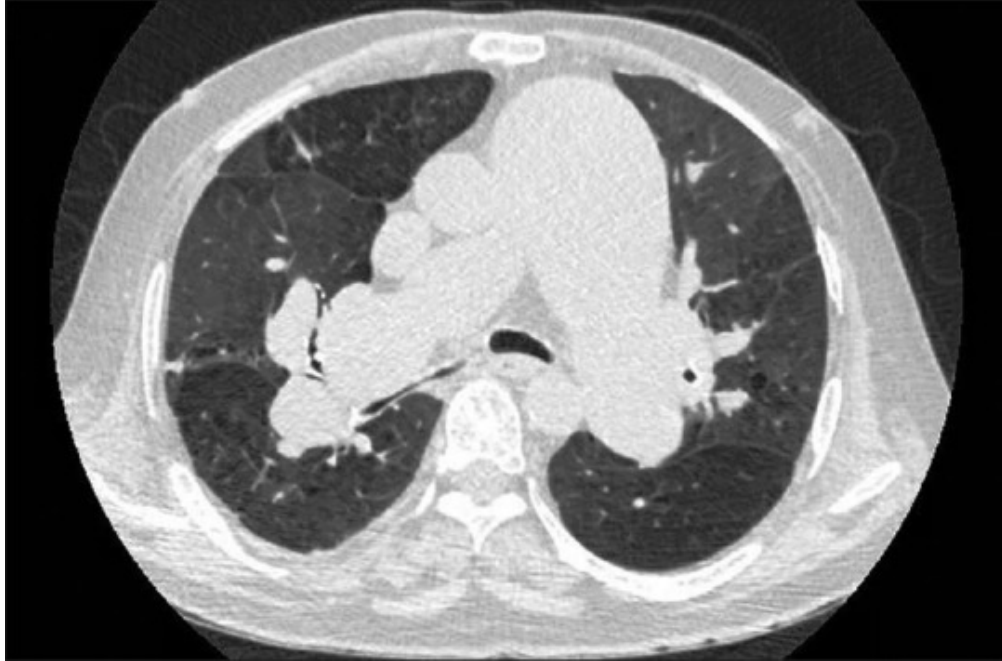LLN-ULN: Lower limit of normal-upper limit of normal, FEV1: Forced expiratory volume in 1 s, FVC: Forced vital capacity

Figure 1



[Open in a separate window](#)

Spirogram demonstrating expiratory flattening of flow-volume curve

Figure 2

Computed tomography scan of the chest demonstrating a slit like compression of the right main stem bronchus from the enlarged right pulmonary artery. Please note that the main pulmonary artery trunk is also enlarged

Table 2

List of cases of symptomatic bronchial vascular compression by enlarged pulmonary artery

Author	Journal	Patient age and sex	WHO PHTN Group	PA dilatation	Intervention
Achouh <i>et al.</i> [5]	European Respiratory Journal 2008	34 male	Group I	Pulmonary trunk to aortic diameter ratio >2	Medical management Bosentan
Achouh <i>et al.</i> [5]	European Respiratory Journal 2008	56 male	Group I	Pulmonary trunk to aortic diameter ratio >1.5	Medical management Bosentan
Morjaria <i>et al.</i> [6]	Pulm Circ 2012	55 male	Group IV	Not reported	Medical management Bosentan
Jaijee <i>et al.</i> [2]	Pulm Circ 2015	73 female	Group I	91 mm	Medical management Bosentan Sildenafil
Jaijee <i>et al.</i> [2]	Pulm Circ 2015	63 male	Group I	51 mm	Medical management Bosentan Sildenafil
Arimura <i>et al.</i> [7]	Am J Respir Crit Care Med 2015	42 female	Group I	79 mm	Not reported
Nokes <i>et al.</i> [8]	Am J Respir Crit Care Med 2019	63 female	Group I	Dilation see in APCs	Not reported

APCs: Aortopulmonary collaterals, PHTN: Pulmonary hypertension, PA: Pulmonary artery

Articles from Lung India : Official Organ of Indian Chest Society are provided here courtesy of **Wolters Kluwer -- Medknow Publications**