

2020

COVID-19 Presenting as Acute Hepatitis

P. Wander

GME, pwander@northwell.edu

M. Epstein

Zucker School of Medicine at Hofstra/Northwell, mepstein@northwell.edu

D. Bernstein

Zucker School of Medicine at Hofstra/Northwell, dbernste@northwell.edu

Follow this and additional works at: <https://academicworks.medicine.hofstra.edu/articles>



Part of the [Hepatology Commons](#)

Recommended Citation

Wander P, Epstein M, Bernstein D. COVID-19 Presenting as Acute Hepatitis. . 2020 Jan 01; 115(6):Article 6255 [p.]. Available from: <https://academicworks.medicine.hofstra.edu/articles/6255>. Free full text article.

This Article is brought to you for free and open access by Donald and Barbara Zucker School of Medicine Academic Works. It has been accepted for inclusion in Journal Articles by an authorized administrator of Donald and Barbara Zucker School of Medicine Academic Works. For more information, please contact academicworks@hofstra.edu.

COVID-19 Presenting as Acute Hepatitis

Praneet Wander, MD¹, Marcia Epstein, MD² and David Bernstein, MD¹

Am J Gastroenterol 2020;00:1–2. <https://doi.org/10.14309/ajg.0000000000000660>

Coronavirus disease (COVID-19) is a novel enveloped RNA betacoronavirus that emerged from Wuhan, China, in December 2019 and rapidly has become a worldwide pandemic affecting hundreds of thousands of people and causing death in an estimated 0.5%–3% of infected cases (1). The most common clinical presentation is respiratory symptoms such as fever, shortness of breath, and cough associated with radiographical findings consistent with pneumonia (2). The prevalence of abnormal liver tests on the initial presentation of COVID-19 is still undetermined. Currently, there are no approved therapies for COVID-19 other than supportive care, enrollment in clinical trials, and the use of off-label therapies such as vitamin C and hydroxychloroquine without supportive, randomized clinical trials to support their efficacy. We report our first case of COVID-19 presenting as acute, nonicteric hepatitis.

A 59-year-old woman presented to the emergency department with a chief concern of dark urine. On entering our facility, she was isolated and a surgical mask was placed on her face as per our protocol. She denied cough, sore throat, shortness of breath, diarrhea, nausea, vomiting, or abdominal pain. She lives alone and denied sick contacts. She had a medical history of well-controlled human immunodeficiency virus (CD4 499 and viral load undetectable), hypertension, hyperlipidemia, Graves disease, and a left facial paralysis secondary to previous actinomycosis infection. She denied recent intake of

acetaminophen or any antibiotics. Her outpatient medications included clonidine, fish oil, levothyroxine, amlodipine, propranolol, hydrochlorothiazide, MVI, and *Genvoya* (elvitegravir, cobicistat, emtricitabine, and tenofovir alafenamide). Recent outpatient liver chemistries were normal. She was admitted because of the concern of rising liver tests in a patient with human immunodeficiency virus disease.

On presentation, her temperature was 37.2 °C. There were no cutaneous manifestations, her lung examination was normal, and there was no jaundice, right upper quadrant tenderness, hepatomegaly, or splenomegaly. Laboratory results were as follows: white blood cell count 3.71 G/L, platelets 140 G/L, serum bilirubin 0.6 mg/dL (N: < 25), AST 1230 IU/L (N: < 50), ALT 697 IU/L (N: < 50), alkaline phosphatase 141 IU/L (N: < 125), serum albumin 3.1 g/dL (N: > 3.5), INR 1.08, and ferritin 6,606 ng/mL (N: < 150). An abdominal sonogram with Doppler revealed a normal liver with patent vasculature. The following serological tests were performed and all tested negative: hepatitis A, B, C, E, *Cytomegalovirus*, Epstein-Barr and respiratory viral panel. Blood cultures and screening for autoimmune markers were negative.

On admission day 2, 18 hours after presentation to the emergency department, she developed a fever to 39 °C with SpO₂ 94% on room air. A chest x-ray showed bilateral interstitial opacities. Nasopharyngeal samples taken for the SARS-CoV PCR test were positive, and the patient was placed on 3 L of oxygen. On admission day 4, she was started on a 5-day course of hydroxychloroquine 200 mg BID. She did well and was discharged to home on hospital day 8 with serum bilirubin 0.6 mg/dL, AST 114 IU/L, ALT 227 IU/L, alkaline phosphatase 259 IU/L, serum albumin 2.8 g/dL, and INR 1.13 (Figure 1). Her outpatient medications including her human immunodeficiency virus treatment were continued throughout her entire admission.

COVID-19 infection typically presents with respiratory symptoms such as fever, sore throat, cough, and shortness of breath. In high-volume centers such as

ours, liver test abnormalities are being noted following COVID-19 diagnosis. We report our first case of COVID-19 infection presenting as acute nonicteric hepatitis before the development of fever and respiratory symptoms.

Our patient was on a stable outpatient medication regimen and had normal outpatient liver tests just before admission for COVID-19. Her initial presentation was not typical for COVID-19, and she was evaluated for acute hepatitis. This workup was negative, and 18 hours after admission, she developed respiratory symptoms and was subsequently diagnosed with COVID-19. She was treated for COVID-19 with hydroxychloroquine, and her symptoms improved, as did her liver chemistries. Because all other causes of acute nonicteric hepatitis were ruled out, it seems highly likely that her acute hepatitis was caused by COVID-19 infection.

There is currently no standard of care for the treatment of COVID-19 infection. Current therapies include implementing infection control measures, symptomatic treatment, and supportive care including supplemental oxygen and mechanical ventilation when appropriate. There are currently no approved therapies to treat COVID-19 infection. Clinical trials are ongoing to evaluate antiviral therapies and immune-modulator therapies.

The antimalarial and anti-inflammatory medication, hydroxychloroquine, has been widely used to treat COVID-19 infection without any available data from randomized clinical trials to inform clinical guidance on the use, dosing, or duration of hydroxychloroquine for prophylaxis or the treatment of COVID-19 infection (3).

Hydroxychloroquine has been shown to have in vitro activity against SARS-CoV and SARS-CoV-2 (COVID-19) (4). A single, nonrandomized study of 36 patients in France suggested that hydroxychloroquine lowered coronavirus levels in the blood as compared to untreated controls and shortened recovery time (5). Six of the 20 patients who received hydroxychloroquine also received azithromycin, whereas none of the control received azithromycin. A randomized study from China reported

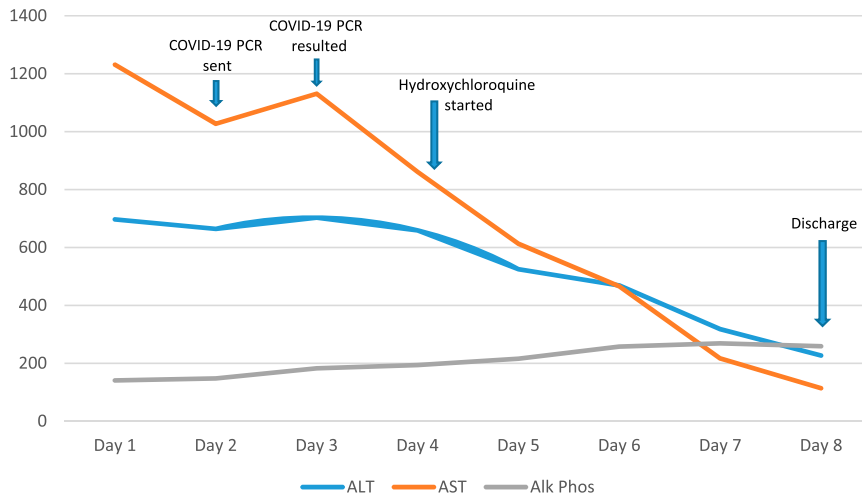


Figure 1. Liver tests during hospital course.

that hydroxychloroquine showed no benefit in treating COVID-19 infection (6). Hydroxychloroquine is currently under investigation in clinical trials for pre-exposure or postexposure prophylaxis of COVID-19 infection and treatment of patients with mild, moderate, and severe COVID-19.

On review of the limited literature to date, our case appears to be the first reported case of COVID-19 infection presenting as acute hepatitis before the development of respiratory symptoms. Clinicians should be aware in this era of COVID-19 infection that acute nonicteric hepatitis may be the virus' initial

presentation before the development of respiratory symptoms. Patients with risk factors for COVID-19 presenting with acute hepatitis should be isolated and undergo testing for COVID-19. Further observational studies are needed to determine the frequency of this presentation and that of mild-to-moderate liver test abnormalities during this evolving pandemic.

CONFLICTS OF INTEREST

Guarantor of the article: David Bernstein, MD.

Specific author contributions: All authors contributed to the writing of the case report.

Financial support: None to report.

Potential competing interests: None to report.

REFERENCES

- Chen N, Zhou M, Dong X, et al. Epidemiological and clinical characteristics of 99 cases of 2019 novel coronavirus pneumonia in Wuhan, China: A descriptive study. *Lancet* 2020;395:507–13.
- Huang C, Wang Y, Li X, et al. Clinical features of patients infected with 2019 novel coronavirus in Wuhan, China. *Lancet* 2020; 395:497–506.
- CDC.gov. Accessed March 29, 2020.
- Yao X, Ye F, Zhang M, et al. In vitro antiviral activity and projection of optimized dosing design of hydroxychloroquine for the treatment of severe acute respiratory syndrome coronavirus 2 (SARS-CoV-2). *Clin Infect Dis* 2020:ciaa237. doi: 10.1093/cid/ciaa237. [Epub ahead of print].
- Gautret P, Lagier JC, Parola P et al. Hydroxychloroquine and azithromycin as a treatment of COVID-19: Results of an open-label non-randomized clinical trial. *Int J Antimicrob Agents* 2020. Accessed March 29, 2020. [Epub ahead of print].
- Chen J, Liu D, Liu L, et al. A pilot study of hydroxychloroquine in treatment of patients with common coronavirus-19. *J Zhejiang Univ* 2020. Accessed March 29, 2020. doi: 10.3785/j.issn.1008-9292.2020.03.03.

¹Division of Hepatology, Northwell Health and Zucker School of Medicine at Hofstra/Northwell, Hempstead, New York, USA; ²Division of Infectious Diseases, Northwell Health and Zucker School of Medicine at Hofstra/Northwell, Hempstead, New York, USA. **Correspondence:** Praneet Wander, MD. E-mail: praneet_wander@hotmail.com.