

2020

A case of *Listeria monocytogenes* meningitis complicated by Hydrocephalus and Intraventricular hemorrhage: A review of treatment options and outcomes

S. Gerstein

Northwell Health

P. Gautam-Goyal

Zucker School of Medicine at Hofstra/Northwell

S. Goyal

Follow this and additional works at: <https://academicworks.medicine.hofstra.edu/publications>




Part of the [Infectious Disease Commons](#)

Recommended Citation

Gerstein S, Gautam-Goyal P, Goyal S. A case of *Listeria monocytogenes* meningitis complicated by Hydrocephalus and Intraventricular hemorrhage: A review of treatment options and outcomes. . 2020 Jan 01; 19():Article 6274 [p.]. Available from: <https://academicworks.medicine.hofstra.edu/publications/6274>. Free full text article.

This Article is brought to you for free and open access by Donald and Barbara Zucker School of Medicine Academic Works. It has been accepted for inclusion in Journal Articles by an authorized administrator of Donald and Barbara Zucker School of Medicine Academic Works. For more information, please contact academicworks@hofstra.edu.



A case of *Listeria monocytogenes* meningitis complicated by Hydrocephalus and Intraventricular hemorrhage: A review of treatment options and outcomes

Shawn Gerstein^{a,*}, Pranisha Gautam-Goyal^a, Sameer Goyal^b

^a North Shore University Hospital, Department of Infectious Diseases, 400 Community Drive, Manhasset, NY, 11030, United States

^b North Shore University Hospital, Department of Infectious Diseases, 300 Community Drive, Manhasset, NY, 11030, United States

ARTICLE INFO

Article history:

Received 13 January 2020

Received in revised form 16 January 2020

Accepted 16 January 2020

Keywords:

Listeria

Intracerebral

Intrathecal

Hydrocephalus

Hemorrhage

Meningitis

ABSTRACT

Listeria monocytogenes is a gram-positive bacillus known to cause various human infections including central nervous system infections. The most common central nervous system manifestations are meningitis and rhomboencephalitis, however rare complications including hydrocephalus and intracerebral hemorrhage can occur and are associated with increased mortality and incidence of lasting neurologic sequelae. The mortality ranges from 17 % to greater than 30 % in patients with neurological involvement [1–3]. Various case reports have studied the differing treatment approaches and outcomes of patients who experienced these complications, and there is still no consensus on optimal treatment approaches. In this paper, we report a case of *Listeria* meningitis complicated by both acute hydrocephalus and intracerebral hemorrhage and analyze the factors that led to a favorable outcome by reviewing the existing literature.

© 2020 The Authors. Published by Elsevier Ltd. This is an open access article under the CC BY-NC-ND license (<http://creativecommons.org/licenses/by-nc-nd/4.0/>).

Introduction

Listeria monocytogenes is a gram positive bacillus known for causing invasive disease such as bacteremia and CNS (Central Nervous System) infections in vulnerable populations including pregnant women, immunosuppressed patients, and those at extremes of age including neonates and the elderly. It is primarily thought to be acquired from food, including raw vegetables, dairy, meat, fish, and poultry. CNS manifestations can range from a mild febrile illness with mental status changes to more severe manifestations including coma and death. Meningoencephalitis is the most common CNS *Listeria* infection, with less common complications including ventriculitis, rhomboencephalitis, hemorrhage, and hydrocephalus [2].

Hydrocephalus has been a recognized complication of *Listeria monocytogenes* meningoencephalitis (LMME) leading to significant morbidity and mortality. The etiology of hydrocephalus is likely multifactorial and related to factors such as a high level of CSF protein and impaired CSF absorption due to the obliteration of the subarachnoid space by meningeal exudates or defective CSF

reabsorption through arachnoid granulations because of severe inflammatory reaction [2,4]. After *S. pneumoniae*, *L. monocytogenes* is the second most common pathogen causing hydrocephalus [3].

Intracranial hemorrhage associated with *L. monocytogenes* has been reported even less frequently than hydrocephalus, with most cases occurring in pediatric populations. However it has been reported in adults, where it has been found to be an independent marker of unfavorable outcomes [5]. The underlying pathophysiology of intraventricular hemorrhage in *L. monocytogenes* infection is hypothesized to be related to dysregulation of both the coagulation and fibrinolytic pathways and to vascular endothelial cell swelling and activation [2,5].

Clinical case

We present a case of a 62 year old female with a past medical history significant for multiple myeloma status post stem cell transplant 16 months prior and subsequently treated with pomalidomide and biweekly dexamethasone, and well controlled diabetes who initially was brought to the hospital by her family for headaches beginning that morning. Subsequently she became more lethargic, confused, and febrile to a temperature of 102 degrees Fahrenheit. On arrival to the emergency department she was found to be septic, with a fever of 103.2 degrees Fahrenheit and tachycardia with a HR of 127 bpm. Initial work up showed a

* Corresponding author at: 28-22 Astoria Boulevard Apartment 3B, Long Island City, NY, 11102, United States.

E-mail address: Shawn.gerstein@gmail.com (S. Gerstein).

possible infiltrate on chest x-ray concerning for pneumonia, a urinalysis concerning for urinary tract infection, and a respiratory viral panel by PCR which was positive for coronavirus. The patient was initiated on vancomycin and piperacillin-tazobactam empirically. Initial CT scan of the head was largely unremarkable, showing only mild prominence of the ventricles and global cerebral volume loss (Fig. 1). The patient was admitted to the medical wards, where she had rapid deterioration of her clinical status resulting in obtundation, acute hypoxic respiratory failure and septic shock requiring intubation and vasopressors.

The infectious work up revealed *Escherichia coli* bacteremia thought to be secondary to a urinary source. On the second day of admission she was escalated to meropenem, but she continued to spike fevers with no improvement in mental status despite weaning off sedation. On the 6th day of admission, a repeat CT scan of her head revealed a new hydrocephalus with transependymal flow and questionable midbrain lucency (Fig. 2). Subsequent Magnetic Resonance Imaging of the brain showed intraventricular hemorrhage. An external ventricular drain (EVD) was placed emergently by neurosurgery, and the resulting cerebrospinal fluid analysis showed 22 nucleated cells with 35 % neutrophils and 35 % lymphocytes, an elevated protein of 84 and low normal glucose of 49, though cerebrospinal fluid glucose was less than 60 percent of serum glucose. Cerebrospinal fluid PCR returned positive for *Listeria monocytogenes* and antimicrobials were changed to ampicillin, in addition to ceftriaxone to cover for *E coli* bacteremia. The patient was later started on gentamicin to add double coverage for *Listeria* and was given a dose of intrathecal amikacin. After 5 days the EVD was clamped, and when subsequent CT showed no further enlargement of the ventricles, the EVD was removed 8 days after originally having been placed. The patient showed improvement in mental status, first localizing to voice and then partially following commands. She was successfully extubated on hospital day 16. Upon further questioning, her spouse mentioned that the patient had been to an international barbecue a week prior to admission, and might have eaten uncooked food there, illuminating the possible source of infection.

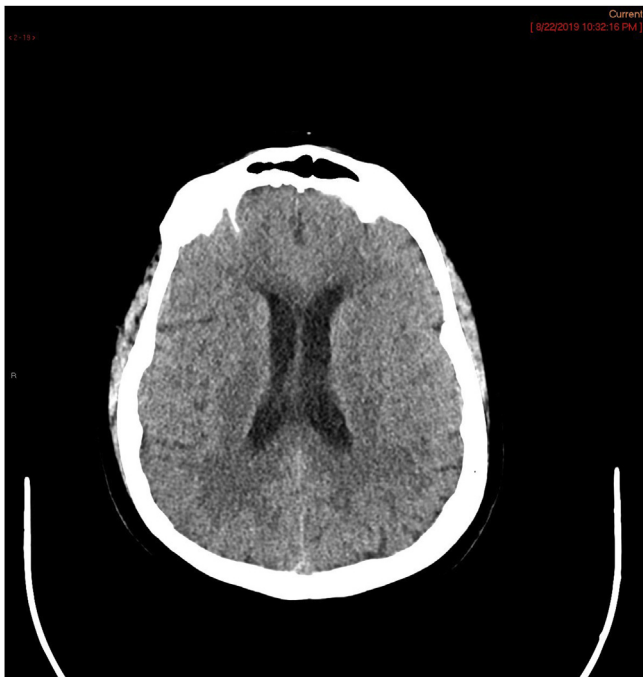

Fig. 1. non-contrast CT of head showing no hydrocephalus with micro vascular ischemic changes.

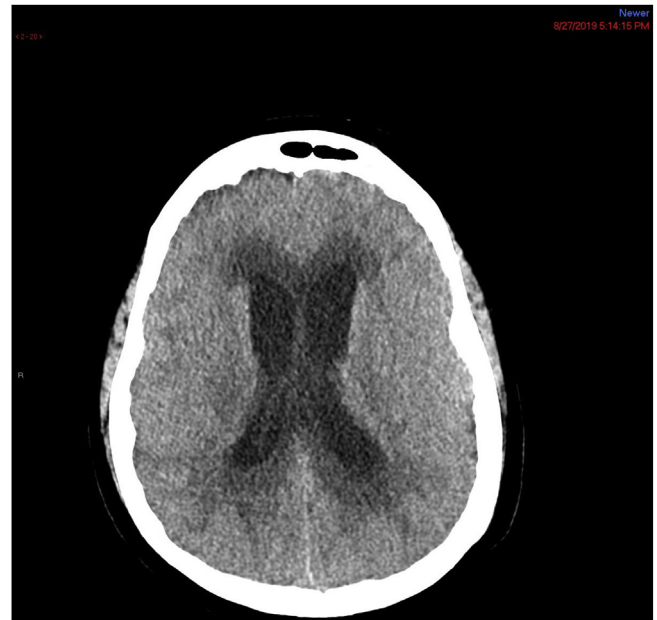

Fig. 2. Non-contrast CT of head with diffuse ventriculomegaly and hydrocephalus of bilateral temporal horns.

Discussion

Neurolisteriosis, a central nervous system (CNS) infection caused by *L. monocytogenes*, represents 5 %–10 % of listeriosis cases [3]. Hydrocephalus and intracranial hemorrhage are rare complications of listeriosis, occurring in 10 %–15 % and 3 % of neurolisteriosis cases, respectively [4,6]. This represents a higher incidence of hydrocephalus due to *Listeria* than the overall incidence of hydrocephalus as a complication of bacterial meningitis, estimated at 5 % [7]. The likelihood of developing hydrocephalus is more with symptoms lasting >4 days, with incidence greater than 30 % as per the review by Pelegrin et al. [1]. It is often not diagnosed on admission, and initial CT might appear normal, as with our patient, often leading to delayed detection up to a median of 6 days after admission. This complication also carries significant morbidity and mortality. In the study by Pelegrin et al., hydrocephalus was associated with a mortality of 75 %, representing 43 % of the total mortality due to LMME. Another study by Charlier et al. reports a three-month mortality around 30 %, with persisting neurological impairment reported in 44 % of surviving patients [8]. Liang et al. found a similar grim prognosis when reviewing 18 cases of non-perinatal listeriosis in patient's age range 3–75 years, with 27.7 % mortality (5/18) and 23 % (3/13) of the survivors with significant neurologic impairment [2].

These high morbidity and mortality figures occurred in the setting of a range of treatment courses, as there is no clear consensus on optimal management. In several cases, patients did not receive appropriate coverage for *Listeria* until the organism was confirmed by either culture or PCR analysis, while in other cases *Listeria* was covered empirically from the onset of hospitalization, with or without double coverage utilizing an aminoglycoside. While dual therapy with ampicillin and aminoglycosides has been proposed in guidelines, Pelegrin and colleagues found no mortality difference between ampicillin monotherapy and combination therapy with an aminoglycoside [1,9] In the same study, while adjunctive administration of dexamethasone and phenytoin did not provide a clear mortality benefit, the use of dexamethasone showed a trend towards fewer neurologic sequelae and those who received

phenytoin experienced no seizures. Dexamethasone did not show any clear benefit in prophylaxis against hydrocephalus, as had been suggested by animal models. Most patients we reviewed received an external ventricular catheter without significant differences in outcome from those who hadn't. Appropriate empirical antimicrobial therapy and consultation with neurosurgery regarding management of hydrocephalus were seen as the key features of management by Pelegrin and colleagues, while inappropriate empiric antimicrobial therapy and hydrocephalus were the main independent prognostic factors associated with mortality [1].

The use of intrathecal/intraventricular antimicrobials in this setting has not been well studied. A review of the existing literature reveals no standard protocol for the administration of intraventricular antimicrobials in the setting of CNS infections [10]. The risk reward profile focuses on the advantages of higher doses of antimicrobials in the CSF than can cross the blood brain barrier alone versus the increased risk of toxicity. A clinical cohort study by Shoft and colleagues found a mortality benefit with no significant adverse events when utilizing intraventricular antimicrobials alongside systemic antimicrobials in a population of post-neurosurgical patients [11]. A case report by Richards and colleagues demonstrated the efficacy of using intraventricular antimicrobials in a patient with recurrent *Listeria monocytogenes* meningitis following treatment failure with systemic therapy alone [12].

Our case is unique as the patient experienced two rare complications of neurolisteriosis: hydrocephalus and intraventricular hemorrhage both of which are associated with high morbidity and mortality, as well as lasting neurologic impairment. Despite these complications she did relatively well, regaining most of her functional status prior to discharge aside from some mild cognitive impairment. This could be influenced by multiple factors including the initiation of appropriate antimicrobials within 24 h of presentation, double coverage with an aminoglycoside as well as intraventricular administration, the placement of an EVD, steroids for the initial 5 days of hospitalization, and anti-seizure medications. As previously discussed, the data on the utility of steroids, dual antimicrobial coverage, and anti-epileptics in the setting of neurolisteriosis is conflicting, and there is no definitive evidence if it played a role in our patient's positive outcome. The utilization of a dose of an intrathecal aminoglycoside was relatively novel compared to other reported cases and merits further study as a potentially beneficial addition to standard therapy in this setting.

Sources of funding

There was no funding for this report.

Consent

Not applicable.

Author contribution

- 1) Shawn Gerstein: resources, conceptualization, writing-original draft, writing- review and editing
- 2) Pranisha Gautam-Goyal: resources, conceptualization, writing-original draft, writing-review and editing
- 3) Sameer Goyal: writing-review and editing

Declarations of Competing Interest

The authors have no conflicts of interest to report.

References

- [1] Pelegrín I, Moragas M, Suárez C, et al. *Listeria monocytogenes* meningoencephalitis in adults: analysis of factors related to unfavourable outcome. *Infection* 2014;42 (October (5)):817–27.
- [2] Liang J, He X, Ye H. Rhombencephalitis caused by *Listeria monocytogenes* with hydrocephalus and intracranial hemorrhage: a case report and review of literature. *World J Clin Cases* 2019;7(February (4)):538–47.
- [3] Nachmias B, Orenbuch-Harroch E, Makranz C, et al. Early hydrocephalus in *listeria* meningitis: case report and review of the literature. *ID Cases* 2015;2015:248302.
- [4] Kasanmoentalib ES. Hydrocephalus in adults with community-acquired bacterial meningitis. *Neurology* 2010;75(10):918–23.
- [5] Mook-Kanamori BB, Fritz D, Brouwer MC, et al. Intracerebral hemorrhages in adults with community associated bacterial meningitis in adults: should we reconsider anticoagulant therapy? *PLoS One* 2012;7:e45271.
- [6] Ito H, Kobayashi S, Iino M, et al. *Listeria monocytogenes* meningoencephalitis presenting with hydrocephalus and ventriculitis. *Intern Med* 2008;47:323–4.
- [7] S. Gaini, G.H. Karlsen, A. Nandy, et al. Culture Negative *Listeria monocytogenes* Meningitis Resulting in Hydrocephalus and Severe Neurological Sequelae in a Previously Healthy Immunocompetent Man with Penicillin Allergy, Hindawi Publishing Corporation, *Case Reports in Neurological Medicine* 2015, Article ID 248302, 5.
- [8] Charlier C, Perrodeau É, Leclercq A, et al. Clinical features and prognostic factors of listeriosis: the MONALISA national prospective cohort study. *Lancet Infect Dis* 2017;17:510–9.
- [9] Tunkel AR, Hartman BJ, Kaplan SL, Kaufman BA, Roos KL, Scheld WM, et al. Practice guidelines for the management of bacterial meningitis. *Clin Infect Dis* 2004;39:1267–84.
- [10] Mrowczynski O, Langan S, Rizk E. Intra-cerebrospinal fluid antibiotics to treat central nervous system infections: a review and update. *Clin Neurol Neurosurg* 2018;170(July):140–58.
- [11] Shofty B, Neuberger A, Naffaa ME, et al. Intrathecal or intraventricular therapy for post-neurosurgical Gram-negative meningitis: matched cohort study. *Clin Microbiol Infect* 2015;22:66–70.
- [12] Richards S, Lambert CM, Scott AC. Recurrent *Listeria monocytogenes* meningitis treated with intraventricular vancomycin. *J Antimicrob Chemother* 1992;29 (March (3)):351–3.