

2020

## Letter: Surgical Management of Brain Tumor Patients in the COVID-19 Era

BE Zacharia

DG Eichberg

ME Ivan

S Hanft

JA Boockvar

*Zucker School of Medicine at Hofstra/Northwell*

*See next page for additional authors*

Follow this and additional works at: <https://academicworks.medicine.hofstra.edu/publications>



Part of the [Neurology Commons](#)

---

### Recommended Citation

Zacharia B, Eichberg D, Ivan M, Hanft S, Boockvar J, Isildak H, Mansouri A, Komotar R, D'Amico R. Letter: Surgical Management of Brain Tumor Patients in the COVID-19 Era. . 2020 Jan 01; 87(2):Article 6385 [ p.]. Available from: <https://academicworks.medicine.hofstra.edu/publications/6385>. Free full text article.

This Article is brought to you for free and open access by Donald and Barbara Zucker School of Medicine Academic Works. It has been accepted for inclusion in Journal Articles by an authorized administrator of Donald and Barbara Zucker School of Medicine Academic Works. For more information, please contact [academicworks@hofstra.edu](mailto:academicworks@hofstra.edu).

---

**Authors**

BE Zacharia, DG Eichberg, ME Ivan, S Hanft, JA Boockvar, H Isildak, A Mansouri, RJ Komotar, and RS D'Amico

## Letter: Surgical Management of Brain Tumor Patients in the COVID-19 Era

To the Editor:

The “coronavirus disease 2019” or COVID-19, caused by the severe acute respiratory syndrome coronavirus 2 (SARS-CoV-2) (Figure), has resulted in a worldwide pandemic and critically burdened healthcare systems. We aim at establishing guidelines regarding optimal surgical decision-making for treating brain tumor patients in the COVID-19 era.

### INTRACRANIAL TUMOR SURGICAL CASE STRATIFICATION

Decisions regarding surgical intervention in this resource-scarce time must undergo rigorous ethical and clinical evaluation. Except in emergency cases, we advocate using multidisciplinary conferences to gather consensus regarding surgical urgency.<sup>1-4</sup> Table 1 outlines our stratification used to guide surgical timing.

#### Screening/Testing Guidelines

In regions with high baseline COVID-19 rates and available testing, all patients should undergo testing as close as possible to surgery. Some institutions recommend 2 tests given the relatively high false-negative test rate.<sup>5</sup> In regions where COVID-19 testing is not readily available, all patients should be screened with a questionnaire to assess the likelihood of active disease and prior exposure. Positive-screened patients should undergo testing when available or undergo 14-d preoperative quarantine. If testing

remains unavailable, enhanced personal protective equipment (PPE) (Table 1) precautions should be considered.<sup>6</sup> In institutions without routine testing availability and without high rates of disease presence, those patients who screen negative may likely proceed to the operating room with standard precautionary measures.

### GENERAL PERIOPERATIVE CRANIAL PRECAUTIONS

Enhanced PPE should be utilized for these procedures in patients who screen positive via questionnaire or testing. Only essential staff should be permitted in the operating room. Aerosolization of the virus prior to and during intubation remains possible where it can deposit on fomites in the operating room, or even possibly remain suspended in the air.<sup>7,8</sup> All staff nonessential to intubation should leave the room during intubation.

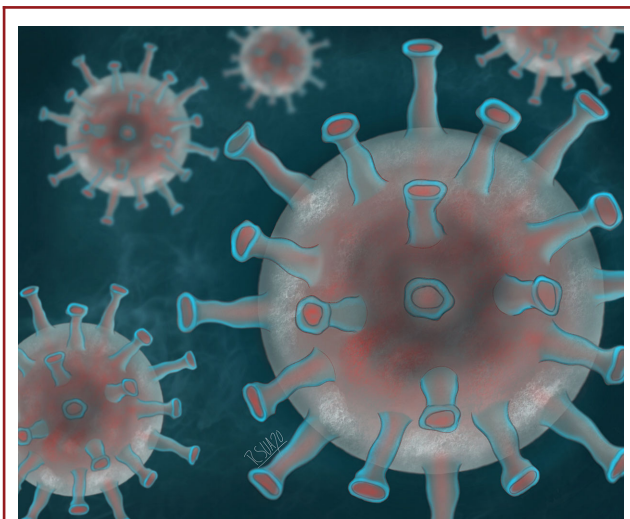
### ENDOSCOPIC ENDONASAL PROCEDURES

Given the high viral load in the upper airway of infected patients, aerosolization of SARS-CoV-2 may be extremely high during sinonasal and upper airway procedures, particularly when powered instruments (such as drills) are employed.<sup>9</sup> The American Association of Otolaryngology—Head and Neck Surgery (AAO-HNS) recommends deferring endoscopic endonasal procedures unless emergent or until preoperative COVID-19 testing can be performed.<sup>10</sup>

Several scenarios, including high-flow cerebrospinal fluid (CSF) leak, pituitary apoplexy, and progressive neurological deficits secondary to an enlarging sellar lesion, may be deemed emergent. Per the AAO-HNS, all surgeries should be performed using enhanced PPE, regardless of COVID-19 testing status.<sup>10</sup> Strong consideration should be given to transcranial approaches to the sella when feasible (Table 2).

### PARANASAL SINUS INVOLVEMENT AND MASTOID DRILLING DURING TRANSCRANIAL SURGERY

Given that the paranasal sinuses are in direct communication with the upper airway, extreme caution should be exercised to avoid sinus entry during transcranial surgery. Previous publications have reported coronavirus (although not specifically SARS-CoV-2) involving the middle ear<sup>11,12</sup>; as mastoid drilling can aerosolize the virus, surgical approaches involving mastoid drilling should be either deferred if nonurgent or avoided in favor of safer approaches.



**FIGURE.** Illustration of SARS-CoV-2, the virus that causes COVID-19.

**TABLE 1. Surgical Timing Recommendations Based on Brain Tumor Surgical Indications**

Category/procedure	Recommendation
<b>Emergent (performed as soon as possible)</b> <ul style="list-style-type: none"> <li>● Impending herniation, hydrocephalus</li> </ul>	<ul style="list-style-type: none"> <li>● Assume patient is COVID-19 positive</li> <li>● Use enhanced PPE<sup>a</sup></li> </ul>
<b>Urgent (performed as soon as possible, 2 to 7 d)</b> <ul style="list-style-type: none"> <li>● Suspicion for high-grade malignancy</li> <li>● Rapidly progressive neurological deficits</li> </ul>	<ul style="list-style-type: none"> <li>● Stabilize patient medically</li> <li>● If COVID-19 testing available: <ul style="list-style-type: none"> <li>– proceed with surgery</li> <li>– preoperative testing as close as possible to surgery</li> <li>– quarantine until testing returns negative</li> <li>– rapid testing the day of surgery if available</li> </ul> </li> <li>● If testing unavailable: <ul style="list-style-type: none"> <li>– assume patient is COVID-19 positive</li> <li>– use enhanced PPE<sup>a</sup></li> <li>– only a minimum number of required staff permitted in the operating room</li> </ul> </li> </ul>
<b>Semiurgent (performed within 1 to 4 wk)</b> <ul style="list-style-type: none"> <li>● Mild or asymptomatic brain lesions</li> <li>● Benign or stable imaging (absence of edema, mass effect, midline shift, etc)</li> <li>● Delay in surgery may cause progression of neurological deficit or disease</li> </ul>	<ul style="list-style-type: none"> <li>● Stabilize patient medically</li> <li>● If testing not widely available: <ul style="list-style-type: none"> <li>– preoperative testing as close as possible to surgery if the patient screens negative and has been self-quarantined for 14 d</li> </ul> </li> <li>● If testing available: <ul style="list-style-type: none"> <li>– proceed with surgery following preoperative testing as close as possible to surgery and quarantine until testing returns negative</li> <li>– rapid testing the day of surgery if available</li> </ul> </li> <li>● Consider stereotactic radiosurgery as an alternative to open surgery and traditional fractionated radiotherapy in equivocal cases to preserve hospital resources and minimize risk of staff exposure</li> </ul>

PPE, personal protective equipment; PAPR, powered air-purifying respirator.

<sup>a</sup>Enhanced PPE defined as an N95 respirator with facial protection or PAPR, surgical bouffant/cap, gloves, and gown.

## AWAKE CRANIOTOMIES

Although SARS-CoV-2 transmission during an awake craniotomy has never been reported, there is a theoretically high risk of viral transmission, as a laryngeal mask airway may

be repeatedly inserted and removed throughout the surgery and virus particles may be transmitted while the patient is breathing and speaking. It may be prudent to use nonawake strategies for eloquent area mapping, such as asleep intraoperative electromyography.<sup>13</sup> Biopsy rather than surgical resection with the speech

**TABLE 2. High-Risk COVID-19 Transmission Brain Tumor Surgical Approach Recommendations**

Surgical approach	Recommendations
Endoscopic endonasal Awake craniotomy	<ul style="list-style-type: none"> <li>● Consider transcranial approach if feasible</li> <li>● Consider asleep mapping with intraoperative electromyogram mapping</li> <li>● Consider biopsy only if near speech areas (Broca/Wernicke)</li> </ul>
Approaches requiring mastoid air cell drilling (ie, retrosigmoid craniotomy, posterior petrosectomy) Frontal craniotomies Benign tumors that are at high risk for prolonged hospital stay causing obstructive hydrocephalus	<ul style="list-style-type: none"> <li>● Enhanced PPE for all staff even if negative COVID-19 testing due to false-negative rate</li> <li>● Avoid entering paranasal sinuses</li> <li>● Consider CSF diversion with ETV or VPS and defer tumor resection</li> </ul>
All high-risk surgical approaches	<ul style="list-style-type: none"> <li>● Defer surgery if elective</li> <li>● Enhanced PPE for all staff even if negative COVID-19 testing due to false-negative rate</li> <li>● Minimal staff in operating room at all times</li> </ul>

CSF, cerebrospinal fluid; ETV, endoscopic third ventriculostomy; PPE, personal protective equipment; VPS, ventriculoperitoneal shunt.

mapping of left fronto-temporal-insular gliomas should be considered.

## CONSUMPTION OF PPE AND HOSPITAL RESOURCES

Neurosurgeons should maintain extreme vigilance with PPE. For surgeries likely to result in prolonged hospitalization, surgical staging may be prudent. If a smaller surgical intervention is planned, the neurosurgeon should consider operating without an assistant. Reflexive intensive care unit (ICU) care for postoperative craniotomy patients can likely be avoided following most straightforward operations. Rapid discharges with close telemedicine follow-up should be employed. For patients with extensive preoperative neurological disability preventing early home discharge, social services should be activated upon hospital admission for swift rehab disposition. Expedient but safe discharges can conserve hospital beds for COVID-19 patients.

## PATIENT AND CAREGIVER SUPPORT



Brain tumor patients are particularly vulnerable in the COVID-19 era. Patients frequently suffer from neurological and functional impairment, thus requiring support via family, home nursing services, and physical, occupational, and speech therapy, many of which cannot be currently delivered. Preoperative consideration of these issues is paramount.




Patients undergoing radiation and/or chemotherapy are frequently immunosuppressed and are at exquisite risk for the development of infection. As per National Cancer Institute recommendations, patients should practice respiratory precautions, limit exposure to others, and have access to several weeks of medications.<sup>14</sup>



## Disclosures


The authors have no personal, financial, or institutional interest in any of the drugs, materials, or devices described in this article. Dr Zacharia is a member of the NICO Corporation Speakers Bureau and is a consultant for Medtronic Incorporated.

**Brad E. Zacharia, MD, MS**  




**Daniel G. Eichberg, MD**  




**Michael E. Ivan, MD, MBS**   

**Simon Hanft, MD**  

**John A. Boockvar, MD** 

**Huseyin Isildak, MD**  

**Alireza Mansouri, MD, MSc**   

**Ricardo J. Komotar, MD**   

**Randy S. D'Amico, MD** 

\*Department of Neurosurgery  
The Pennsylvania State University  
College of Medicine  
Hershey, Pennsylvania

<sup>‡</sup>Penn State Cancer Institute  
Hershey, Pennsylvania

<sup>§</sup>Department of Neurosurgery  
University of Miami  
Miami, Florida

<sup>¶</sup>Sylvester Comprehensive Cancer Center  
Miami, Florida

<sup>||</sup>Department of Neurosurgery  
Rutgers-Robert Wood Johnson Medical School  
New Brunswick, New Jersey

<sup>#</sup>Department of Neurosurgery  
Lennox Hill Hospital/Northwell Health  
New York, New York

<sup>\*\*</sup>Department of Otolaryngology—Head and Neck Surgery  
The Pennsylvania State University  
College of Medicine  
Hershey, Pennsylvania

## REFERENCES

- Eichberg DG, Shah AH, Luther EM, et al. Letter: academic neurosurgery department response to COVID-19 pandemic: the University of Miami/Jackson Memorial Hospital model. *Neurosurgery*. 2020.
- Zoia C, Bongetta D, Veiceschi P, et al. Neurosurgery during the COVID-19 pandemic: update from Lombardy, Northern Italy. *Acta Neurochir (Wien)*. published online: March 28, 2020 (doi:10.1007/s00701-020-04305-w).
- Tan YT, Wang JW, Zhao K, et al. Preliminary recommendations for surgical practice of neurosurgery department in the central epidemic area of 2019 coronavirus infection. *Curr Med Sci*. published online: March 26, 2020 (doi:10.1007/s11596-020-2173-5).
- Burke JF, Chan AK, Mummaneni V, et al. Letter: the coronavirus disease 2019 global pandemic: a neurosurgical treatment algorithm. *Neurosurgery*. published online: 2020 (doi:10.1093/neuros/nyaa116).
- Wang Y, Kang H, Liu X, Tong Z. Combination of RT-qPCR testing and clinical features for diagnosis of COVID-19 facilitates management of SARS-CoV-2 outbreak. *J Med Virol*. (doi:10.1002/jmv.25721).
- Saadi RA, Bann DV, Patel VA, Goldenberg D, May J, Isildak H. A commentary on safety precautions for otologic surgery during the COVID-19 pandemic. *Otolaryngol Head Neck Surg*. In Press.
- Cook TM, El-Boghdady K, McGuire B, McNarry AF, Patel A, Higgs A. Consensus guidelines for managing the airway in patients with COVID-19: guidelines from the Difficult Airway Society, the Association of Anaesthetists the Intensive Care Society, the Faculty of Intensive Care Medicine and the Royal College of Anaesthetists. *Anaesthesia*. published online: March 27 (doi:10.1111/anae.15054).
- Cheung JC-H, Ho LT, Cheng JV, Cham EYK, Lam KN. Staff safety during emergency airway management for COVID-19 in Hong Kong. *Lancet Respir Med*. 2020;8(4):PE19.
- Vukkadala N, Qian ZJ, Holsinger FC, Patel ZM, Rosenthal E. COVID-19 and the otolaryngologist—preliminary evidence-based review. *Laryngoscope*. published online: March 26, 2020 (doi:10.1002/lary.28672).
- American Academy of Otolaryngology—Head and Neck Surgery. *Academy Supports CMS, Offers Specific Nasal Policy*. March 18, 2020. <https://www.entnet.org/content/academy-supports-cms-offers-specific-nasal-policy>. Accessed March 20, 2020.
- Pitkaranta A, Jero J, Arruda E, Virolainen A, Hayden FG. Polymerase chain reaction-based detection of rhinovirus, respiratory syncytial virus, and coronavirus in otitis media with effusion. *J Pediatr*. 1998;133(3):390-394.
- Pitkaranta A, Virolainen A, Jero J, Arruda E, Hayden FG. Detection of rhinovirus, respiratory syncytial virus, and coronavirus infections in acute otitis media by

- reverse transcriptase polymerase chain reaction. *Pediatrics*. 1998;102(2 Pt 1):291-295.
13. Yingling CD, Ojemann S, Dodson B, Harrington MJ, Berger MS. Identification of motor pathways during tumor surgery facilitated by multichannel electromyographic recording. *J Neurosurg*. 1999;91(6):922-927.
  14. National Cancer Institute. Coronavirus: What People With Cancer Should Know. 2020. <https://www.cancer.gov/contact/emergency-preparedness/coronavirus>. Accessed April 3, 2020.

## Acknowledgments

We would like to thank Roberto Suazo for contributing original high-quality artwork.

Copyright © 2020 by the Congress of Neurological Surgeons

---

10.1093/neuros/nyaa162

---