

2020

Delay in Diagnosis of Barrett's Esophagus Cancer During the COVID-19 Pandemic: Lessons Learned.

A. J. Trindade

Zucker School of Medicine at Hofstra/Northwell

A. Rishi

Zucker School of Medicine at Hofstra/Northwell

Follow this and additional works at: <https://academicworks.medicine.hofstra.edu/publications>



Part of the [Gastroenterology Commons](#)

Recommended Citation

Trindade AJ, Rishi A. Delay in Diagnosis of Barrett's Esophagus Cancer During the COVID-19 Pandemic: Lessons Learned.. . 2020 Jan 01; 115(10):Article 6629 [p.]. Available from: <https://academicworks.medicine.hofstra.edu/publications/6629>. Free full text article.

This Article is brought to you for free and open access by Donald and Barbara Zucker School of Medicine Academic Works. It has been accepted for inclusion in Journal Articles by an authorized administrator of Donald and Barbara Zucker School of Medicine Academic Works. For more information, please contact academicworks@hofstra.edu.

Delay in Diagnosis of Barrett's Esophagus Cancer During the COVID-19 Pandemic: Lessons Learned

Arvind J. Trindade, MD¹ and Arvind Rishi, MD²

Am J Gastroenterol 2020;00:1–2. <https://doi.org/10.14309/ajg.0000000000000799>

A 58-year-old man underwent an esophagogastroduodenoscopy (EGD) for the evaluation of dyspepsia on February 28, 2020. Thickened folds were described in the distal esophagus. Biopsies revealed intestinal metaplasia with low-grade dysplasia (LGD) that was confirmed by our pathology department. The patient was referred to our center for further endoscopic evaluation. After discussion with the patient, the decision was made to repeat the

endoscopy after intensive antacid medication. The patient was scheduled for end of March. Because of the COVID-19 pandemic, the patient's procedure was rescheduled twice because (i) the pandemic at the time in New York was severe and endoscopy resources for management of nonemergent patients was low and (ii) guidelines have recommended that endoscopic management of Barrett's with LGD is low priority to semiurgent depending on the guideline (1,2). It should be noted that the American College of Gastroenterology guidelines recommended not to delay evaluation of premalignant conditions (3). However, Barrett's with LGD is not specifically mentioned unlike the aforementioned guidelines.

The patient eventually underwent EGD 13 weeks after the initial procedure, after much convincing because he was fearful to come to the hospital; because of ongoing COVID-19 infections being admitted to the hospital. A short segment of Barrett's was seen in the distal esophagus (Prague class C0M2). No raised lesions were seen, however, on narrow band imaging; a disrupted pit pattern was seen with a shallow ulcer consistent with neoplasia (Figure 1a) (4). The decision was made to perform band ligation endoscopic mucosal resection of the abnormal area. The histology was consistent with focal Barrett's intramucosal cancer in the background of high-grade dysplasia (Figure 1c) that was confirmed by 2 gastrointestinal pathologists experienced in Barrett's pathology in a high-volume Barrett's referral center. Surrounding biopsies and brushings were negative for dysplasia.

This patient's EGD was delayed 3 months because of the COVID-19 pandemic. Fortunately, the endoscopic mucosal resection was curative and the possible consequence from the delay was minimized. This case provides a few lessons for the management of Barrett's during the COVID-19 pandemic. First, every effort should be made not to delay evaluation of Barrett's with dysplasia. In this case, the degree of dysplasia was not appreciated on the first examination because of under sampling vs the full extent of the lesion not being appreciated. There was likely at least high-grade dysplasia present that was not appreciated on random biopsies. In cases of suspected dysplasia, adjunctive use of narrow band imaging may aid in detection and sampling. In addition, allowing sufficient time for proper inspection may also increase the yield of dysplasia detection (5). Second, cases of Barrett's with dysplasia that were delayed because of a stressed endoscopy resource should be scheduled as a priority, when endoscopy resumes after a pandemic. Third, patients should be educated not to self-delay evaluation of Barrett's with dysplasia; which almost occurred in this case. Fourth, as we are seeing in practice, even non-COVID-19 patients are affected by the pandemic. It has been estimated that delays to cancer diagnosis could lead to an additional 30,000 deaths in the United States (6). It is important that health systems triage delayed cases appropriately. Our large health system (with over 11,000 hospitalized COVID-19 patients treated)

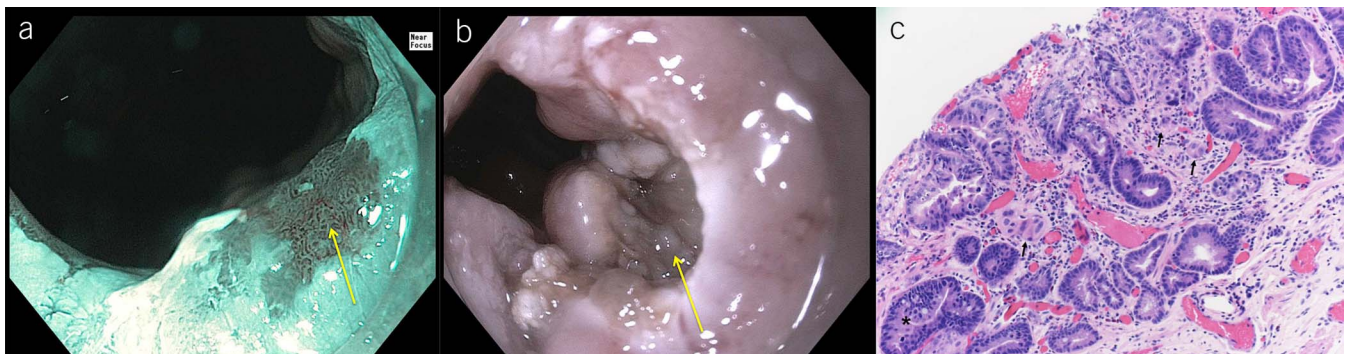


Figure 1. A delayed diagnosis of Barrett's cancer. (a) Narrow band imaging showing a disrupted pit pattern within a Barrett's segment (yellow arrow), (b) abnormal area postendoscopic resection (yellow arrow) and (c) histology showing a small foci of intramucosal adenocarcinoma with microscopic clusters of neoplastic cells infiltrating the lamina propria; arrows. Background of Barrett's metaplasia/intestinal metaplasia; asterisk (H&E stain $\times 200$).

identified all cases of potential gastrointestinal neoplasia diagnosis that were delayed and prioritized them when endoscopy services resumed.

CONFLICTS OF INTEREST

Guarantor of the article: Arvind J. Trindade, MD.

Specific author contributions: Conception and design (A.J.T.); Analysis and interpretation of the data (A.J.T., A.R.); Drafting of the article (A.J.T., A.R.); Critical revision of the article for important intellectual content (A.J.T., A.R.); Final approval of the article (A.J.T., A.R.).

Financial support: None to report.

Potential competing interests: A.J.T.: consultant for Olympus America and Pentax Medical. Research Support from Ninepoint Medical.

REFERENCES

1. European Society of Gastrointestinal Endoscopy, European Society of Gastroenterology and Endoscopy Nurses and Associates. ESGE and ESGENA Position Statement on gastrointestinal endoscopy and the COVID-19 pandemic. *Endoscopy* 2020;52(6): 483–90.
2. Chiu PWY, Ng SC, Inoue H, et al. Practice of endoscopy during COVID-19 pandemic: Position statements of the Asian Pacific Society for Digestive Endoscopy (APSDE-COVID statements). *Gut* 2020;69(6): 991–6.
3. Gastroenterology Professional Society guidance on endoscopic procedures during the COVID-19 pandemic. n.d. (<https://www.gastro.org/practice-guidance/practice-updates/covid-19/gastroenterology-professional-society-guidance-on-endoscopic-procedures-during-the-covid-19-pandemic>). Accessed April 23, 2020.
4. Singh R, Jayanna M, Wong J, et al. Narrow-band imaging and white-light endoscopy with optical magnification in the diagnosis of dysplasia in Barrett's esophagus: Results of the Asia-Pacific Barrett's Consortium. *Endosc Int Open* 2015;3:E14–8.
5. Gupta N, Gaddam S, Wani SB, et al. Longer inspection time is associated with increased detection of high-grade dysplasia and esophageal adenocarcinoma in Barrett's esophagus. *Gastrointest Endosc* 2012;76: 531–8.
6. Hayee B, Thoufeeq M, Rees CJ, et al. Safely restarting GI endoscopy in the era of COVID-19. *Gut* 2020;1–8.

¹Division of Gastroenterology and Hepatology, Long Island Jewish Medical Center, Zucker School of Medicine at Hofstra/Northwell, Northwell Health System, New Hyde Park, New York, USA; ²Division of Gastrointestinal Pathology, Long Island Jewish Medical Center, Zucker School of Medicine at Hofstra/Northwell, Northwell Health System, New Hyde Park, New York, USA. **Correspondence:** Arvind J. Trindade, MD. E-mail: arvind.trindade@gmail.com.