

2020

Severe Coronavirus Disease 2019 Infection in an Adolescent Patient After Hematopoietic Stem Cell Transplantation

G. Fislser

Northwell Health

A. Haimed

Northwell Health

C. F. Levy

Northwell Health

J. Stiles

Northwell Health

C. A. Capone

Northwell Health

See next page for additional authors

Follow this and additional works at: <https://academicworks.medicine.hofstra.edu/publications>

 Part of the [Pediatrics Commons](#)

Recommended Citation

Fislser G, Haimed A, Levy CF, Stiles J, Capone CA, Fish JD, Brochstein JA, Taylor MD. Severe Coronavirus Disease 2019 Infection in an Adolescent Patient After Hematopoietic Stem Cell Transplantation. . 2020 Jan 01; 158(4):Article 6715 [p.]. Available from: <https://academicworks.medicine.hofstra.edu/publications/6715>. Free full text article.

This Article is brought to you for free and open access by Donald and Barbara Zucker School of Medicine Academic Works. It has been accepted for inclusion in Journal Articles by an authorized administrator of Donald and Barbara Zucker School of Medicine Academic Works. For more information, please contact academicworks@hofstra.edu.

Authors

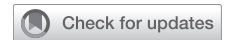G. Fisler, A. Haimed, C. F. Levy, J. Stiles, C. A. Capone, J. D. Fish, J. A. Brochstein, and M. D. Taylor



Since January 2020 Elsevier has created a COVID-19 resource centre with free information in English and Mandarin on the novel coronavirus COVID-19. The COVID-19 resource centre is hosted on Elsevier Connect, the company's public news and information website.

Elsevier hereby grants permission to make all its COVID-19-related research that is available on the COVID-19 resource centre - including this research content - immediately available in PubMed Central and other publicly funded repositories, such as the WHO COVID database with rights for unrestricted research re-use and analyses in any form or by any means with acknowledgement of the original source. These permissions are granted for free by Elsevier for as long as the COVID-19 resource centre remains active.

Severe Coronavirus Disease 2019 Infection in an Adolescent Patient After Hematopoietic Stem Cell Transplantation



Grace Fisler, MD; Abraham Haimed, MD; Carolyn Fein Levy, MD; Jessica Stiles, CPNP; Christine A. Capone, MD; Jonathan D. Fish, MD; Joel A. Brochstein, MD; and Matthew D. Taylor, MD

Infection with the severe acute respiratory syndrome coronavirus 2 causes severe acute lung injury in approximately 5% of infected adults, but few reports have been made of severe pediatric disease. We present an adolescent patient who contracted severe acute respiratory syndrome coronavirus 2 one week after a paternal haplo-identical hematopoietic stem cell transplant, with development of severe hyperferritinemic acute lung injury and macrophage activation-like syndrome. We present her case and a comparison of her laboratory data with those of a cohort of pediatric patients with coronavirus disease 2019 without severe disease.

CHEST 2020; 158(4):e139-e142

KEY WORDS: bone marrow transplant; COVID-19, macrophage activation-like syndrome; pediatric acute respiratory distress syndrome; pediatrics

The coronavirus disease 2019 (COVID-19) has infected 3 million people worldwide, with varying disease phenotype.¹ Data from China suggest that critical cases occur in 0.6% of infected children, and they have reported only one pediatric death.² This contrasts with adult data describing critical illness in 5% of patients and mortality rates of 2.3% to 7%.³⁻⁵ Patients who have hematopoietic stem cell transplantation (HSCT) are at high risk for severe infectious complications.

Case Report

A 15-year-old Hispanic girl in New York City developed pneumonitis 8 days after a paternal-donor haplo-identical HSCT for myelodysplastic syndrome. She had no other medical history before transplantation. Her conditioning regimen consisted of fludarabine 25 mg/m²

IV daily days -14 to -11, busulfan 0.8 mg/mg IV Q6 × 16 days -10 to -7, donor T cells on day -6, and cyclophosphamide 60 mg/kg IV daily days -3 and -2. She received CD34-selected peripheral blood stem cells. Graft-vs-host disease prophylaxis consisted of tacrolimus and mycophenolate mofetil.

She became febrile 8 days posttransplantation. She had no other complications from the pretransplantation or immediate posttransplantation period. Chest CT findings were consistent with those of COVID-19 (Fig 1).⁶ She was on biphasic positive airway pressure for 4 days, when escalating oxygen requirements necessitated intubation. She developed severe pediatric ARDS and presumed septic shock. A sputum sample tested positive for COVID-19 by polymerase chain reaction. All other infectious studies were negative.

ABBREVIATIONS: COVID-19 = coronavirus disease 2019; HSCT = hematopoietic stem cell transplant; MALS = Macrophage activation-like syndrome

AFFILIATIONS: From the Division of Pediatric Critical Care Medicine (Drs Fisler, Capone, and Taylor), the Department of Pediatrics (Drs Fisler, Haimed, Levy, Capone, Fish, Brochstein, and Taylor; and Ms Stiles), and the Division of Pediatric Hematology/Oncology, and Cellular Therapy (Drs Levy, Fish, and Brochstein; and Ms Stiles), Steven and Alexandra Cohen Children's Medical Center of New York, New Hyde Park, NY.

CORRESPONDENCE TO: Matthew Taylor, MD, Division of Pediatric Critical Care Medicine, Steven and Alexandra Cohen Children's Medical Center of New York, 269-01 76th Ave, New Hyde Park, NY 11040; e-mail: Mtaylor15@northwell.edu

Copyright © 2020 American College of Chest Physicians. Published by Elsevier Inc. All rights reserved.

DOI: <https://doi.org/10.1016/j.chest.2020.05.579>

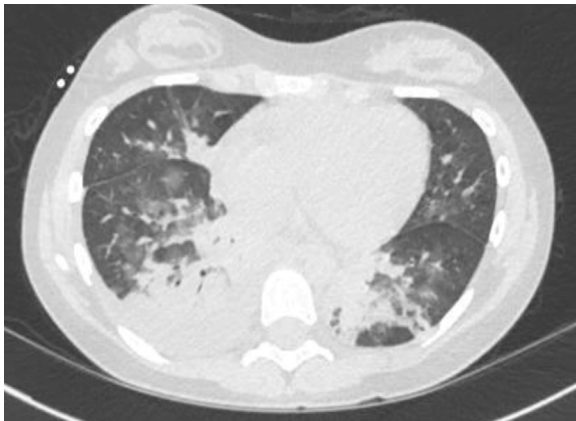


Figure 1 – CT of the chest showing bibasilar patchy ground glass opacities, a right lower lobe consolidation, and a right pleural effusion. The patchy lower-lobe ground glass appearance is typical of coronavirus disease 2019 seen in adults.

Adult medication dosing was used because she weighed 59 kg. Treatment began with hydroxychloroquine 400 mg twice daily and azithromycin 250 mg twice daily, as was common practice at that time. On intubation, she had features suggestive of macrophage activation-like syndrome (MALS) or secondary hemophagocytic lymphohistiocytosis with fever, splenomegaly, high ferritin, and elevated soluble IL-2 receptor. Anakinra 100 mg q6h and dexamethasone 10 mg/m² daily were started per secondary hemophagocytic lymphohistiocytosis institutional standards. Her C-reactive protein and ferritin decreased significantly (Fig 2). A 7-day course of remdesivir, an experimental antiviral, was given through compassionate use protocol.

There was an interruption in remdesivir because of a continuous renal replacement therapy requirement on ICU days 8 through 18 for oliguric renal failure. In the setting of severe PARDS and shock, there was concern for anakinra treatment failure, and tocilizumab 480 mg was administered (PICU day 10). Given her elevated D-dimer and reports of microthrombi in COVID-19, she was anticoagulated with therapeutic enoxaparin.⁷ Her renal function normalized. She underwent tracheostomy placement after 26 days of intubation and one failed extubation attempt. She awaits rehabilitation transfer with the goal of eventual decannulation.

Discussion

We present a teenage girl with immunosuppression due to HSCT who developed hyperferritinemic acute lung injury, multisystem organ dysfunction, and MALS secondary to COVID-19. She was treated with anakinra and dexamethasone, with some improvement in inflammatory markers.⁸ Because her clinical condition remained critical, tocilizumab was administered, using treatment protocols for cytokine release syndrome.⁹ Recent data suggest that early IL-6 blockade impairs host ability to suppress viral replication.¹⁰ Indications for and appropriate timing of IL-1 and IL-6 blockade in COVID-19-associated cytokine release syndrome remain to be established. Therapeutic enoxaparin was administered given reports of thrombi in COVID-19.⁷

With Northwell Health institutional review board approval (20-0318-CCMC), we compared the patient’s laboratory values with those of five randomly selected

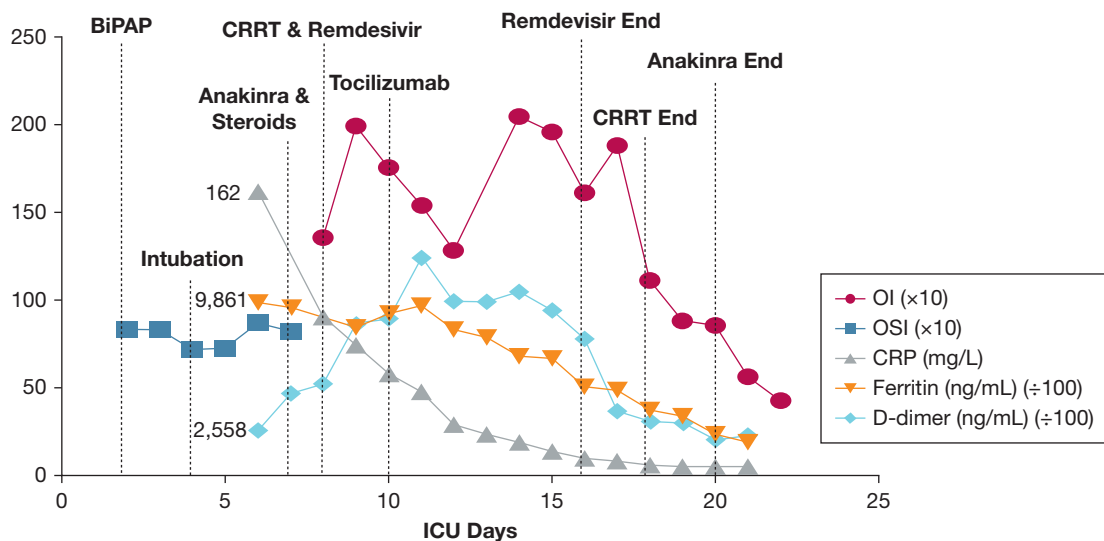


Figure 2 – Trend of inflammatory markers and oxygenation index over time. OI and OSI are powered to 10¹. CRP = C-reactive protein; CRRT = continuous renal replacement therapy; OI = oxygenation index; OSI = oxygen saturation index.

TABLE 1] Laboratory Values With Comparison With a Randomly Selected PICU Cohort With Mild Coronavirus Disease 2019

Laboratory Value	Peak Value (PICU Day)	Posttreatment (PICU Day 18)	Median Mild Disease Severity ICU Cohort (Range) (n = 5)	Laboratory Reference Value
CRP, mg/L	162 (6)	<5.0	14 (7.7-36)	<5.0
Ferritin, ng/mL	9,861 (6)	1,513	302 (127-579) (n = 3)	15-150
D dimer, ng/mL	12,396 (11)	1,021	300 (207-438) (n = 3)	<230
Fibrinogen, mg/dL	666 (7)	175	550 (500-601) (n = 2)	15-150
Triglycerides, mg/dL	526 (2)	103	119 (66-172) (n = 4)	10-149
LDH, U/L	795 (11)	689	361 (178-593)	135-225
Soluble IL-2 receptor, U/mL	1,096 (8)			137-838

CRP = C-reactive protein; LDH = lactate dehydrogenase.

PICU patients with COVID-19 who did not require mechanical ventilation and were discharged without complication. Her inflammatory markers were pointedly higher than those of the healthier cohort (Table 1).

Reports from China concluded that severe disease in children is rare.¹¹ Parri et al¹² described characteristics of 100 admitted Italian children; the median age was 3.3 years, and only one patient presented with hypoxia.¹² Our case contrasts with reports of pediatric disease in China and Italy, given the patient's age and severe disease. The United States has one of the highest uses of HSCT worldwide, with a rate six times that of China.¹³ The higher rates of comorbidities in American children may explain the seemingly higher rate of severe illness in the United States.¹⁴ The COVID-19 Global Rheumatology Alliance reported a mortality rate similar to that reported in general population studies in patients with autoimmune disorders, including those on immunosuppressive medications. Whether immunosuppression is associated with a more severe phenotype of COVID-19 remains unknown; some have postulated the cytokine storm of COVID-19 may be dampened in these patients.^{15,16}

COVID-19 has been reported in HSCT adult patients in Europe. Challenges exist in differentiating COVID-19 from other opportunistic infections in HSCT patients.¹⁷ There has been discussion of delaying or modifying chemotherapy in pediatric cancer patients during the pandemic.¹⁸ Given that the severity of disease herein was likely modified by the immune dysregulation associated with HSCT, delaying HSCT in nonemergent cases should be considered until the severe acute respiratory syndrome coronavirus 2 pandemic is better controlled.

Conclusion

We present a teenager post-HSCT with COVID-19-induced hyperferritinemic acute lung injury, multisystem organ dysfunction, and MALS. Further studies are needed to elucidate optimal therapy for these patients, because the patient received multiple targeted medications. This case suggests that infection in the immune-dysregulated adolescent can cause severe illness.

Acknowledgments

Financial/nonfinancial disclosures: The authors have reported to CHEST the following: C. F. L. has stock in Pfizer. M. D. T. receives NIGMS grant funding [K08GM132794]. None declared (G. F., A. H., J. S., C. A. C., J. D. F., J. A. B.).

Other contributions: CHEST worked with the authors to ensure that the Journal policies on patient consent to report information were met. We thank Dr Indira Sahdev for providing her insight into management decisions.

References

- Dong E, Du H, Garnder L. An interactive web-based dashboard to track COVID-19 in real time. *Lancet Infect Dis*. 2020;20(5):533-534.
- Dong Y, Mo X, Hu Y, et al. Epidemiology of COVID-19 among children in China. *Pediatrics*. 2020;145(6):e20200702.
- Novel coronavirus pneumonia emergency response epidemiology T. [The epidemiological characteristics of an outbreak of 2019 novel coronavirus diseases (COVID-19) in China]. *Zhonghua Liu Xing Bing Xue Za Zhi*. 2020;41(2):145-151.
- Guan WJ, Ni ZY, Hu Y, et al. Clinical characteristics of coronavirus disease 2019 in China. *N Engl J Med*. 2020;382:1708-1720.
- Onder G, Rezza G, Brusaferro S. Case-fatality rate and characteristics of patients dying in relation to COVID-19 in Italy. *JAMA*. 2020;323(18):1775-1776.
- Liu M, Song Z, Xiao K. High-resolution computed tomography manifestations of 5 pediatric patients with 2019 novel coronavirus. *J Comput Assist Tomogr*. 2020;44(3):311-313.
- Zhang T, Sun LX, Feng RE. [Comparison of clinical and pathological features between severe acute respiratory syndrome and coronavirus disease 2019]. *Zhonghua Jie He He Hu Xi Za Zhi*. 2020;43(0):E040.
- Kyriazopoulou E, Leventogiannis K, Norrby-Teglund A, et al. Macrophage activation-like syndrome: an immunological entity associated with rapid progression to death in sepsis. *BMC Med*. 2017;15(1):172.
- Zhang C, Wu Z, Li J-W, Zhao H, Wang G-Q. The cytokine release syndrome (CRS) of severe COVID-19 and Interleukin-6

- receptor (IL-6R) antagonist Tocilizumab may be the key to reduce the mortality. *Int J Antimicrob Agents*. 2020;55(5):105954.
10. McGonagle D, Sharif K, O'Regan A, Bridgewood C. The role of cytokines including interleukin-6 in COVID-19 induced pneumonia and macrophage activation syndrome-like disease. *Autoimmun Rev*. 2020;19(6):102537.
 11. Zheng F, Liao C, Fan QH, et al. Clinical characteristics of children with coronavirus disease 2019 in Hubei, China. *Curr Med Sci*. 2020;40(2):275-280.
 12. Parri N, Lenge M, Buonsenso D. Children with COVID-19 in pediatric emergency departments in Italy. *New Engl J Med*. 2020;383(2):187-190.
 13. Gratwohl A, Baldomero H, Aljurf M, et al. Hematopoietic stem cell transplantation: a global perspective. *JAMA*. 2010;303(16):1617-1624.
 14. COVID-19 Data: North American pediatric ICUs virtual pediatric systems: Children's Hospital Association. <https://covid19.myvps.org/>. Accessed July 8, 2020.
 15. Gianfrancesco MA, Hyrich KL, Gossec L, et al. Rheumatic disease and COVID-19: initial data from the COVID-19 Global Rheumatology Alliance provider registries. *Lancet Rheumatol*. 2020.
 16. Favalli EG, Ingegnoli F, De Lucia O, Cincinelli G, Cimaz R, Caporali R. COVID-19 infection and rheumatoid arthritis: Faraway, so close! *Autoimmun Rev*. 2020;19(5):102523.
 17. Sahu KK, Jindal V, Siddiqui AD, Cerny J. Facing COVID-19 in the hematopoietic cell transplant setting: a new challenge for transplantation physicians. *Blood Cells Mol Dis*. 2020;83:102439.
 18. Kotecha RS. Challenges posed by COVID-19 to children with cancer. *Lancet Oncol*. 2020;21(5):e235.