

2020

Management of COVID-19 myopericarditis with reversal of cardiac dysfunction after blunting of cytokine storm: a case report.

A. Li

Northwell Health

Y. Garcia-Bengochea

Northwell Health

R. Stechel

Zucker School of Medicine at Hofstra/Northwell, rstechel@northwell.edu

B. M. Azari

Zucker School of Medicine at Hofstra/Northwell, bazari@northwell.edu

Follow this and additional works at: <https://academicworks.medicine.hofstra.edu/articles>



Part of the [Cardiology Commons](#)

Recommended Citation

Li A, Garcia-Bengochea Y, Stechel R, Azari BM. Management of COVID-19 myopericarditis with reversal of cardiac dysfunction after blunting of cytokine storm: a case report. . 2020 Jan 01; 4(F11):Article 6776 [p.]. Available from: <https://academicworks.medicine.hofstra.edu/articles/6776>. Free full text article.

This Article is brought to you for free and open access by Donald and Barbara Zucker School of Medicine Academic Works. It has been accepted for inclusion in Journal Articles by an authorized administrator of Donald and Barbara Zucker School of Medicine Academic Works. For more information, please contact academicworks@hofstra.edu.

Management of COVID-19 myopericarditis with reversal of cardiac dysfunction after blunting of cytokine storm: a case report

Angela Li *, Youssef Garcia-Bengochea , Richard Stechel , and Bani M. Azari 

Department of Cardiology, North Shore University Hospital, Donald and Barbara Zucker SOM at Hofstra/Northwell, NY, USA

Received 4 May 2020; first decision 11 May 2020; accepted 23 June 2020; online publish-ahead-of-print 21 July 2020

Background

Coronavirus disease 2019 (COVID-19) is a syndrome that has been associated with multiple cardiac complications including myopericarditis. The pathophysiology and treatment for myopericarditis in the setting of COVID-19 infection is still under investigation.

Case summary

We present a case of a 60-year-old male admitted for dyspnoea due to COVID-19. He developed new ST-segment elevation, elevated cardiac enzymes, severe left ventricular dysfunction, and high inflammatory markers in the setting of haemodynamic and respiratory collapse from the viral illness. He was diagnosed with COVID-19-induced myopericarditis. He showed rapid clinical improvement with a rapid wean off pressure support, resolution of electrocardiogram (ECG) findings, and recovery of left ventricular systolic function following treatment with intravenous immunoglobulin (IVIG) and methylprednisolone.

Discussion

COVID-19's complex and devastating complications continue to create new challenges for clinicians. Cardiac complications, specifically, have been shown to be a signal for worse prognosis in these patients. IVIG and steroids can inhibit the inflammatory cascade and decrease myocardial injury, with implications in treatment of severe myopericarditis.

Keywords

COVID-19 • Myocarditis • Pericarditis • Myopericarditis • Cytokine storm • IVIG • Case report

Learning points

- COVID-19-associated myocarditis can be an indirect complication secondary to an inflammatory cascade.
- Recognition of the potential role of immunomodulation in rapid improvement of cardiac function and stabilization of haemodynamics in COVID-19 myocardial injury.

* Corresponding author. Department of Cardiology, Sandra Atlas Bass Heart Hospital, North Shore University Hospital, 300 Community Drive, 1 Cohen, Manhasset, NY 11030, USA. Tel: +1 201 486 0920, Email: ali10@northwell.edu

Handling Editor: Hatem Soliman Aboumarie

Peer-reviewers: Marcelo Haertel Miglioranza and Matteo Cameli

Compliance Editor: Christian Fielder Camm

Supplementary Material Editor: Ross Thomson

© The Author(s) 2020. Published by Oxford University Press on behalf of the European Society of Cardiology.

This is an Open Access article distributed under the terms of the Creative Commons Attribution Non-Commercial License (<http://creativecommons.org/licenses/by-nc/4.0/>), which permits non-commercial re-use, distribution, and reproduction in any medium, provided the original work is properly cited. For commercial re-use, please contact journals.permissions@oup.com

Introduction

COVID-19 infection caused by severe acute respiratory syndrome coronavirus 2 (SARS-CoV-2) is known to incite an inflammatory response impacting multiple organ systems, including cardiac injury, which manifests as elevated cardiac biomarkers with electrocardiographic (ECG) or echocardiographic abnormalities.¹

Myopericarditis is the clinical and pathological definition for concurrent pericardial and myocardial inflammation, mainly from cardiotropic viruses. Myocardial involvement can be varied, from focal to diffuse involvement of one or all four chambers, depending on the severity of illness.²

Timeline

Timeline	Description
Day 0	Patient admitted with acute hypoxic respiratory failure due to COVID-19.
Day 0: 4 h after admission	Patient intubated for worsening respiratory failure. ECG showed diffuse ST elevation, with evidence of acute inflammation and cardiac injury.
Day 1	Patient was started on IVIG and high-dose steroid therapy. TTE showed severe segmental LV dysfunction.
Day 2	Patient was weaned off pressor support with resolving shock.
Day 2–5	Laboratory values show improvement in inflammatory markers and cardiac biomarkers, and recovering organ dysfunction.
Day 6	Repeat TTE shows recovery of LV systolic function.
Day 13	Repeat ECG demonstrates resolution of ST segment abnormalities.
Day 17	Patient extubated to non-invasive ventilation support.
Day 20	Patient was reintubated and required tracheostomy for persistent respiratory failure due to aspiration.
Day 35	Full TTE confirms continued LV recovery.
Day 38	Tracheostomy was successfully decannulated.
Day 52	Patient was discharged from hospital to physical rehabilitation.

Case presentation

A 60-year-old male with past medical history of hypertension and hyperlipidaemia presented to the emergency department with 8 days of fevers, cough, and worsening dyspnoea, with mild abdominal pain and diarrhoea despite completing a 3-day course of azithromycin as an outpatient. He denied chest pain,

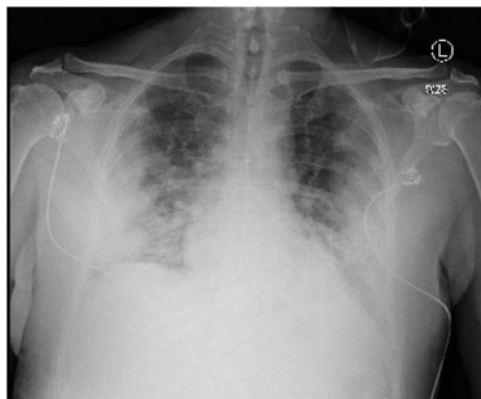

Figure 1 Chest radiograph with bilateral pulmonary infiltrates.

Table 1 Lab values on admission

Lab (units)	Reference range	Absolute value
White blood cell count ($\times 10^3$)	3.8–10.5	17.9
Absolute neutrophil count ($\times 10^3$)	1.8–7.4	16.5
Absolute lymphocyte count ($\times 10^3$)	1.0–3.3	1.1
Haemoglobin (g/dL)	11.5–15.5	14.6
Mean corpuscular volume (fL)	80.0–100.0	88.7
Platelet count ($\times 10^3/\mu\text{L}$)	150–400	282
Sodium (mmol/L)	135–145	138
Potassium (mmol/L)	3.5–5.3	6
Chloride (mmol/L)	98–107	100
Carbon dioxide – serum (mmol/L)	22–31	25
Blood urea nitrogen (mg/dL)	7–23	17
Creatinine (mg/dL)	0.5–1.3	0.96
Glucose – serum (mg/dL)	70–99	277
Calcium (mg/dL)	8.4–10.5	9.3
Protein total – serum (g/dL)	6.0–8.3	7.8
Albumin (g/dL)	3.3–5.0	3.4
Total bilirubin (mg/dL)	0.2–1.2	0.7
Alkaline phosphatase (μL)	40–120	137
Aspartate aminotransferase (μL)	4–32	134
Alanine aminotransferase (μL)	4–33	137
pH – arterial	7.32–7.43	7.09
Lactate (arterial) (mmol/L)	0.5–2.0	1.4
pCO ₂ (mmHg)	41–51	101
C-reactive protein (mg/dL)	<0.40	29.35
Ferritin (ng/mL)	15–150	6379
Lactate dehydrogenase (U/L)	135–225	588
Procalcitonin (ng/mL)	0.02–0.10	0.36
D-dimer (ng/mL)	<230	458
High-sensitivity troponin (ng/L)	<6 – 14	582
Creatine kinase, serum (U/L)	30–200	279
Creatine kinase-MB (ng/mL)	0–6.7	28.2
Serum pro-brain natriuretic peptide (pg/mL) ^a	0–300	15642

^aMeasured on hospital day 3.

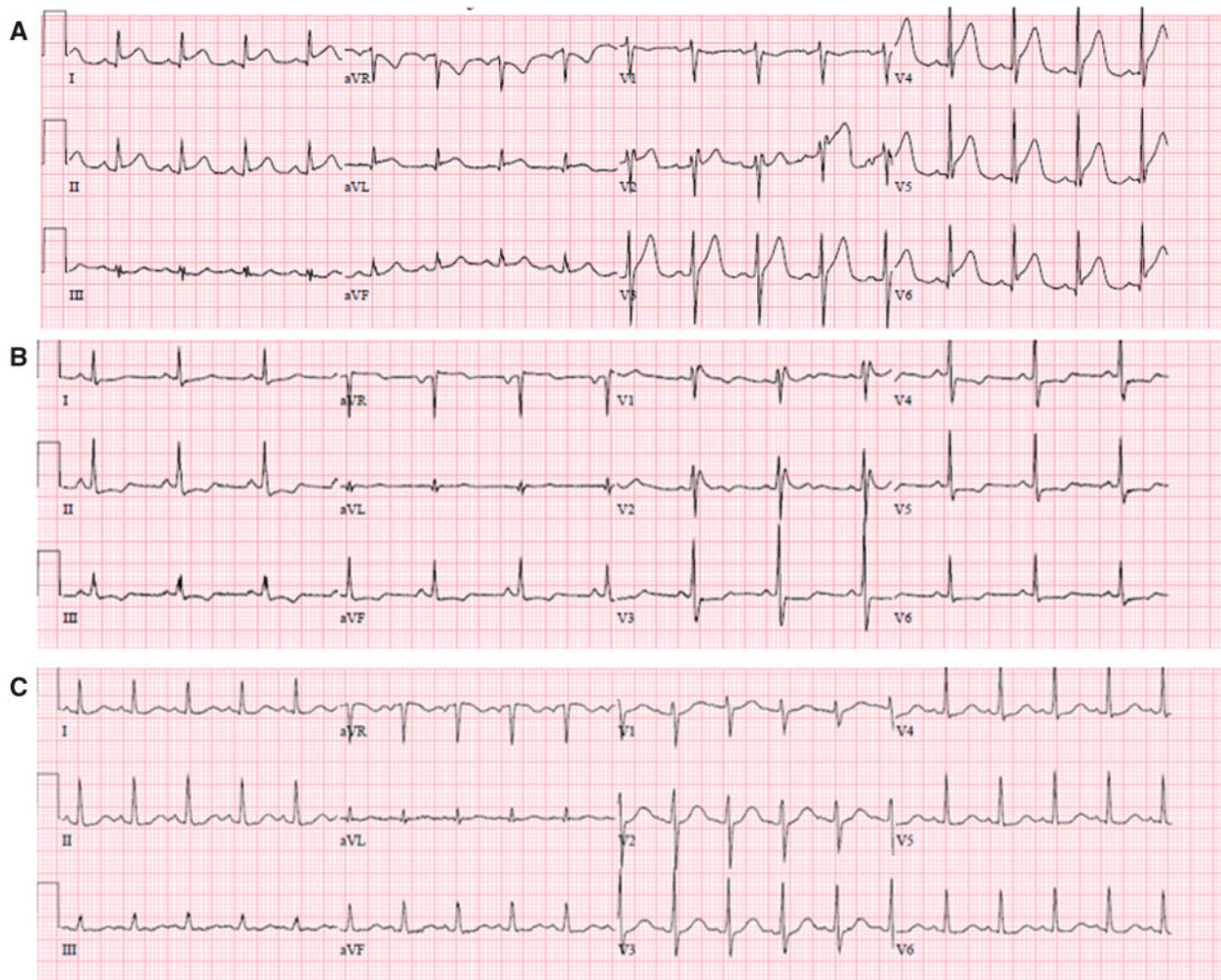


Figure 2 (A) ECG on day 1 shows diffuse ST elevation and PR depression in precordial and limb leads, reciprocal ST depression, and PR elevation in aVR. (B) Day 6 shows incomplete right bundle branch block and horizontal ST depression in precordial and limb leads. (C) Day 13 shows sinus tachycardia without ST or T wave abnormalities.

nausea, or vomiting. The patient was afebrile with maximum temperature of 37.4°C, heart rate at 96 b.p.m., and peripheral oxygen saturation (SpO₂) of 87%. The physical exam demonstrated clear lungs and tachypnoea.

The nasopharyngeal swab was positive for SARS-CoV-2 by reverse transcription–polymerase chain reaction (RT–PCR), and the chest radiograph showed severe bilateral opacities (Figure 1). Admission labs were significant for lymphocytopenia, elevated inflammatory markers, and liver dysfunction. Initial high-sensitivity troponin, creatine kinase, and creatine kinase-MB (CK-MB) were also elevated (Table 1).

The patient was initially placed on a non-rebreather mask with supplemental oxygen via nasal cannula and placed in the prone position, but SpO₂ remained at 82%. He was quickly intubated for acute hypoxaemic respiratory failure and started on hydroxychloroquine therapy for severe COVID-19 infection.

ECG obtained after admission demonstrated diffuse new ST-segment elevation, with QTc interval measured at 437 ms (Figure 2A). Transthoracic echocardiogram (TTE) was significant for severe segmental left ventricular (LV) systolic dysfunction, ejection fraction (EF) 15–20% with hypokinesia of the apex, distal anterior septum, and anterior and lateral walls, with a small pericardial effusion. Right ventricular size and function were normal (Figure 3; Supplementary material online, Videos 1 and 2).

Based on diffuse ECG changes suggestive of pericarditis, TTE findings, and laboratory evidence of systemic inflammation, the patient was initiated on treatment of fulminant myopericarditis on hospital day 1 with a 4-day regimen of intravenous immunoglobulin (IVIg) 20 g daily and methylprednisolone (50 mg every 6 h).

After the patient was intubated, haemodynamic support with epinephrine was initially started and weaned off 1 day after initiation of high-dose steroids and IVIg. Over the next few days,

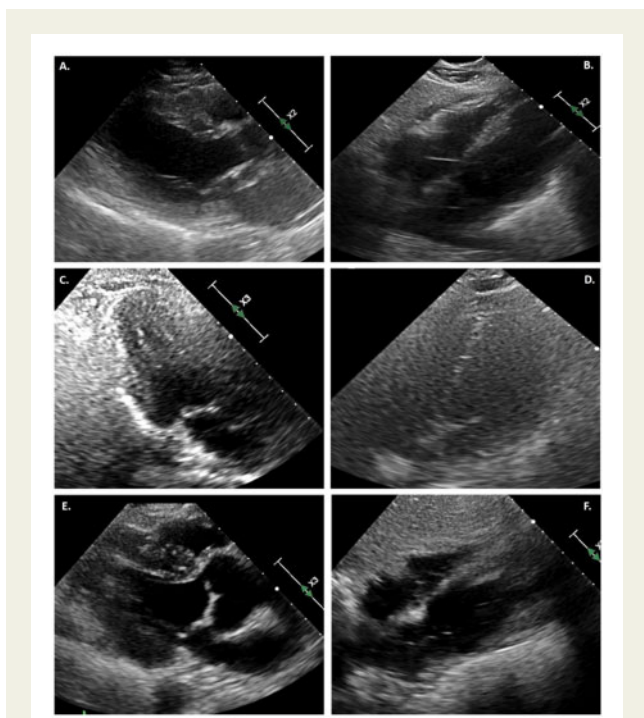


Figure 3 (A) TTE in parasternal long-axis view at end systole, demonstrating severe LV systolic dysfunction. (B) Subcostal view with small pericardial effusion. (C) Repeat echocardiogram on day 6 in three-chamber view at end systole, demonstrating normal LV function. (D) Resolution of pericardial effusion on hospital day 6. (E) TTE at day 35, showing continued normal systolic function in the parasternal long-axis view at end systole. (F) No further pericardial effusion on subcostal view.

he remained afebrile with improving haemodynamics. Laboratory values demonstrated recovery of organ perfusion and inflammation (Figure 4).

Follow-up limited TTE on hospital day 6 demonstrated recovery of LV systolic function, confirmed again with full TTE on day 35. Previous areas of regional hypokinesis were no longer appreciated (Figure 3; Supplementary material online, Videos 3 and 4). A repeat ECG on day 6 was noted with transient horizontal ST depressions across precordial and limb leads (Figure 2B), before resolution of all ST-T wave abnormalities on follow-up ECG on day 13 (Figure 2C). He remained off pressor support and was extubated on hospital day 17; however, he required reintubation within 3 days for persistent respiratory failure due to aspiration. A tracheostomy was performed which was successfully decannulated on hospital day 38. The patient was ultimately discharged for physical rehabilitation on hospital day 52.

Discussion

COVID-19 is known to cause elevated cardiac biomarkers, and levels are overall higher in more severe cases of patients infected with

SARS-CoV2. Cardiac injury, in turn, is associated with increased mortality.¹ ECG changes with a positive troponin that normally would proceed to coronary angiography are now evaluated on a case by case basis, as ST-segment elevation in patients with COVID-19 has a high association with non-obstructive coronary disease. Some of these cases were subsequently diagnosed and managed as myocarditis.³

Our patient's presentation was most consistent with COVID-19 myocarditis, with concurrent pericarditis diagnosed via diffuse ST-segment elevation on ECG and pericardial effusion. The diagnosis of stress cardiomyopathy and septic cardiomyopathy was entertained; however, our patient did not have the classic regional wall motion abnormalities⁴ or LV dilation⁵ typically seen in those cases of cardiac dysfunction, respectively.

Although cases of COVID-19 myocarditis and myopericarditis have been reported in the literature,⁶⁻⁸ the overall prevalence and pathophysiology of this disease manifestation are not well understood. Proposed mechanisms for acute myocardial injury include direct invasion via angiotensin-converting enzyme 2 (ACE2) expressed in the heart, or as a result of an overwhelming cytokine storm.⁹ The use of immunosuppressive therapies such as IVIG and steroids for other forms of myocarditis has been well studied, with a reported decrease in inflammatory markers and improvement in LVEF.¹⁰ In the COVID-19 literature, a case series successfully used IVIG in patients with rapid clinical deterioration and elevated inflammatory markers to suppress the inflammatory cascade.¹¹ Another case report documents a patient with myocarditis who was treated with IVIG and steroids with favourable results.¹²

Our case uniquely demonstrates rapid reversal of cardiac injury associated with COVID-19 after the patient was started on immunomodulating treatment, and a correlating trend with decreasing inflammatory markers. Taken together, this supports the hypothesis of myocardial injury as a result of cytokine storm. Targeted treatment of inflammation with IVIG and steroids led to simultaneous reduction in inflammatory markers and cardiac enzyme levels, after which there was demonstrated improvement in cardiac function both clinically and by echocardiogram. Targeted anti-inflammatory therapy for myocardial injury in severe COVID-19 infection may improve the high mortality rates usually associated with elevated troponin levels in these patients. Our patient also demonstrated improvement in non-cardiac COVID-19 symptoms after therapy with IVIG, with reduced oxygen requirements following 1 day of treatment. This timeline for clinical improvement is significantly more accelerated than what is usually observed with hydroxychloroquine and steroid treatment alone.^{13,14}

Conclusion

The natural history of cardiac injury related to SARS-CoV2 infection is not well understood, and usual diagnostic tools such as TTE, advanced imaging, and angiography are often limited in use to decrease the spread of infection exposure. In patients with increasing cardiac biomarkers, evidence of systemic inflammation and a low suspicion for acute coronary syndrome, inhibiting the

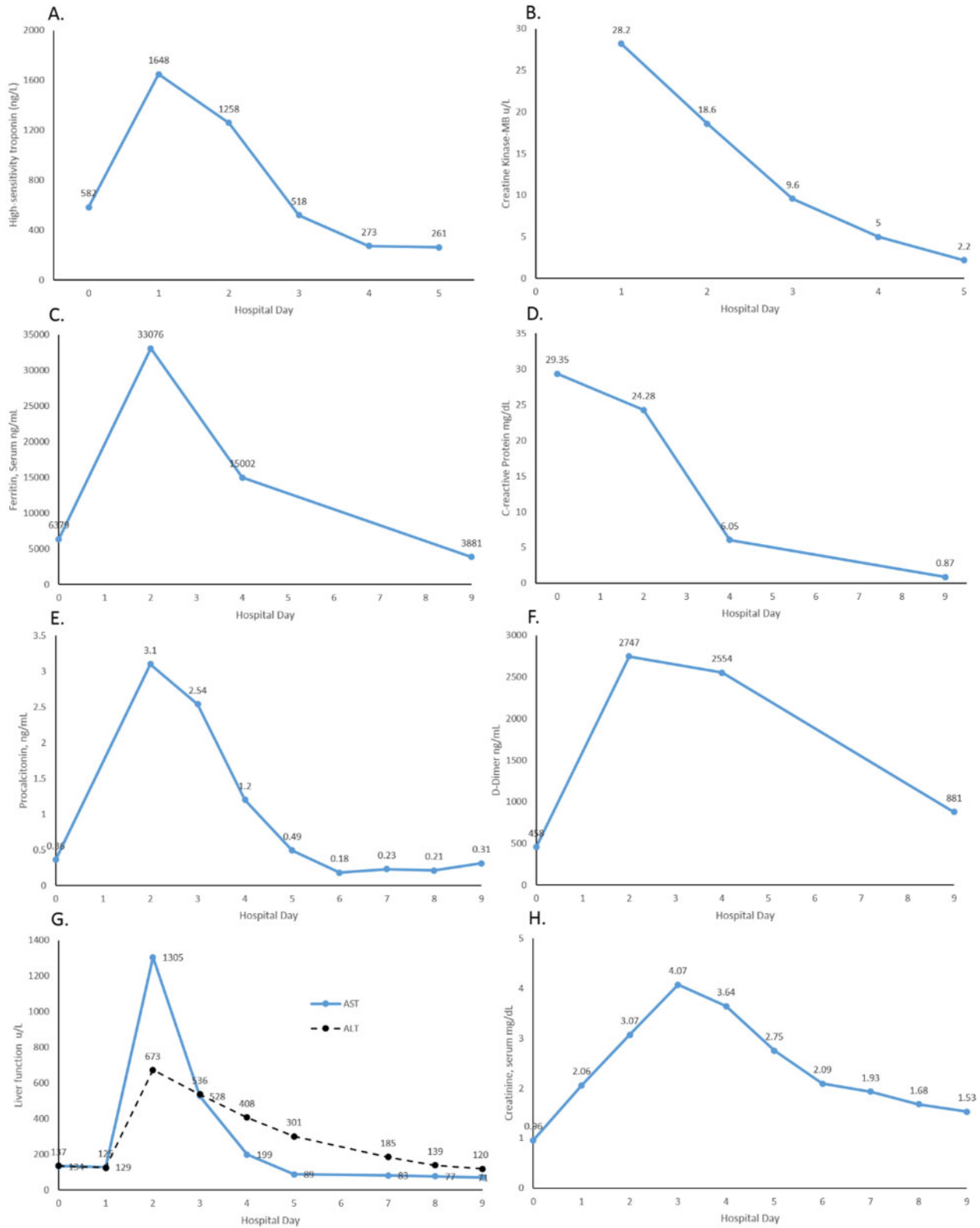



Figure 4 Graphs of laboratory values following steroid and IVIG treatment. Decreasing cardiac biomarker trends through Day 5: (A) high-sensitivity troponin; (B) CK-MB. Decreasing inflammatory markers through Day 9: (C) ferritin; (D) C-reactive protein; (E) procalcitonin; (F) D-dimer. Initial worsening then improvement through Day 9 of (G) hepatic function; (H) renal function.

inflammatory cascade may also treat the resulting myocarditis and reverse cardiac injury.

Lead author biography



Angela Li is a second year cardiology fellow at North Shore University/Long Island Jewish Medical Center in New York. She received her undergraduate degree from Johns Hopkins University and her medical degree from Penn State College of Medicine. She completed her Internal Medicine-Pediatrics residency at Rush University Medical Center in Chicago, Illinois. She has a special interest in interventional cardiology, structural heart disease and adult congenital heart disease.

Supplementary material

Supplementary material is available at *European Heart Journal – Case Reports* online.

Acknowledgements

We would like to acknowledge the contributions of the Northwell Health COVID-19 Research Consortium.

Slide sets: A fully edited slide set detailing this case and suitable for local presentation is available online as Supplementary data.

Consent: The author/s confirm that written consent for submission and publication of this case report including image(s) and associated text has been obtained from the patient in line with COPE guidance.

Conflict of interest: none declared.

References

- Li J-W, Han T-W, Woodward M, Anderson CS, Zhou H, Chen Y-D, Neal B. The impact of 2019 novel coronavirus on heart injury: a systematic review and meta-analysis. *Prog Cardiovasc Dis* 2020;doi: 10.1016/j.pcad.2020.04.008.
- Imazio M, Trincherò R. Myopericarditis: etiology, management, and prognosis. *Int J Cardiol* 2008;**127**:17–26.
- Bangalore S, Sharma A, Slotwiner A, Yatskar L, Harari R, Shah B, Ibrahim H, Friedman GH, Thompson C, Alviar CL, Chadow HL, Fishman GI, Reynolds HR, Keller N, Hochman JS. ST-segment elevation in patients with Covid-19—a case series. *N Engl J Med* 2020;**382**:2478–2480.
- Chazal HMD, Buono MGD, Keyser-Marcus L, Ma L, Moeller FG, Berrocal D, Abbate A. Stress cardiomyopathy diagnosis and treatment. *JACC State-of-the-Art Review. J Am Coll Cardiol* 2018;**72**:1955–1971.
- Sato R, Nasu M. A review of sepsis-induced cardiomyopathy. *J Intensive Care* 2015;**3**:48.
- Inciardi RM, Lupi L, Zaccone G, Italia L, Raffo M, Tomasoni D, Cani DS, Cerini M, Farina D, Gavazzi E, Maroldi R, Adamo M, Ammirati E, Sinagra G, Lombardi CM, Metra M. Cardiac involvement in a patient with coronavirus disease 2019 (COVID-19). *JAMA Cardiol* 2020;doi: 10.1001/jamacardio.2020.1096.
- Zeng JH, Liu YX, Yuan J, Wang FX, Wu WB, Li JX, Wang LF, Gao H, Wang Y, Dong CF, Li YJ, Xie XJ, Feng C, Liu L. First case of COVID-19 complicated with fulminant myocarditis: a case report and insights. *Infection* 2020;doi: 10.1007/s15010-020-01424-5.
- Monmeneu JV, Dominguez Mafe E, Andres Soler J, Ventura Perez B, Solsona Caravaca J, Broseta Torres R, García-Gonzalez P, Higuera Ortega L, Lopez-Lereu M, Maceira AM. Subacute perimyocarditis in a young patient with COVID-19 infection. *Eur Heart J Case Rep* 2020;doi: 10.1093/ehjcr/yttaa157.
- Zheng Y-Y, Ma Y-T, Zhang J-Y, Xie X. COVID-19 and the cardiovascular system. *Nat Rev Cardiol* 2020;**17**:259–260.
- Magnani JW, Dec GW. Myocarditis. *Circulation* 2006;**113**:876–890.
- Cao W, Liu X, Bai T, Fan H, Hong K, Song H, Han Y, Lin L, Ruan L, Li T. High-dose intravenous immunoglobulin as a therapeutic option for deteriorating patients with coronavirus disease 2019. *Open Forum Infect Dis* 2020;doi: 10.1093/ofid/ofaa102.
- Hu H, Ma F, Wei X, Fang Y. Coronavirus fulminant myocarditis treated with glucocorticoid and human immunoglobulin. *Eur Heart J* 2020;doi: 10.1093/eurheartj/ehaa190.
- Sarma P, Kaur H, Kumar H, Mahendru D, Avti P, Bhattacharyya A, Prajapat M, Shekhar N, Kumar S, Singh R, Singh A, Dhibar DP, Prakash A, Medhi B. Virological and clinical cure in COVID-19 patients treated with hydroxychloroquine: a systematic review and meta-analysis. *J Med Virol* 2020;**92**.
- Wu C, Chen X, Cai Y, Xia JA, Zhou X, Xu S, Huang H, Zhang L, Zhou X, Du C, Zhang Y, Song J, Wang S, Chao Y, Yang Z, Xu J, Zhou X, Chen D, Xiong W, Xu L, Zhou F, Jiang J, Bai C, Zheng J, Song Y. Risk factors associated with acute respiratory distress syndrome and death in patients with Coronavirus disease 2019 pneumonia in Wuhan, China. *JAMA Intern Med* 2020;doi: 10.1001/jamainternmed.2020.0994.