

2020

Fatty Metaplasia within a Chronic Myocardial Infarction: Multimodality Correlation between Echocardiography and Computed Tomography.

A. Ganguly
Northwell Health

M. Lapa
Northwell Health

S. G. Saba
Zucker School of Medicine at Hofstra/Northwell

Follow this and additional works at: <https://academicworks.medicine.hofstra.edu/publications>

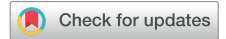 Part of the [Cardiology Commons](#)

Recommended Citation

Ganguly A, Lapa M, Saba SG. Fatty Metaplasia within a Chronic Myocardial Infarction: Multimodality Correlation between Echocardiography and Computed Tomography. . . 2020 Jan 01; 4(5):Article 6997 [p.]. Available from: <https://academicworks.medicine.hofstra.edu/publications/6997>. Free full text article.

This Article is brought to you for free and open access by Donald and Barbara Zucker School of Medicine Academic Works. It has been accepted for inclusion in Journal Articles by an authorized administrator of Donald and Barbara Zucker School of Medicine Academic Works. For more information, please contact academicworks@hofstra.edu.

Fatty Metaplasia within a Chronic Myocardial Infarction: Multimodality Correlation between Echocardiography and Computed Tomography



Anupriya Ganguly, MD, Matthew Lapa, MD, and Shahryar G. Saba, MD, *Manhasset, New York*

INTRODUCTION

Differences in temporal, spatial, and tissue resolution among noninvasive cardiovascular imaging modalities determine their indications, with some degree of overlap. The temporal resolution of echocardiography, in addition to considerations regarding safety, cost, and feasibility, justify its use as the first-line assessment for ventricular and valvular function. However, echocardiography lacks the ability to characterize myocardial tissue in contrast with cardiovascular magnetic resonance and computed tomography. Both cardiovascular magnetic resonance and computed tomography demonstrate the ability to accurately identify intramyocardial fat, a known occurrence in both ischemic and nonischemic cardiomyopathies. In this report we describe echocardiographic evidence of a chronic myocardial infarction with fatty metaplasia and correlate this finding with computed tomography and invasive coronary angiography.

CASE PRESENTATION

A 67-year-old man with an ischemic cardiomyopathy presented to the hospital with volume overload. Transthoracic echocardiography showed akinesis of the basal to mid inferoseptal (Figures 1A and 1B, Videos 1 and 2) and inferior (Video 3) segments of the left ventricle, which appeared hyperechoic relative to the other myocardial segments. The study revealed a sharp delineation in echogenicity and wall motion between the akinetic mid inferoseptum and the apical septum, which demonstrated normal wall thickening and echodensity. The echogenicity of the basal to mid inferoseptum appeared similar to the anterior aspect of the interatrial septum, a known region of lipomatous infiltration. Computed tomography (Figure 1C) of the abdomen performed for evaluation of abdominal distension partially imaged the inferior aspect of the heart. The study revealed tissue of fat density (negative Hounsfield units in the range of fat) in the basal to mid inferoseptal segments, correlating with the hyperechoic and akinetic region noted on echocardiography (Figures 1A and 1B, Videos 1 and 2). Computed tomography also demonstrated a clear demarcation between the low-attenuation fat and the normally enhancing

From the Department of Medicine (A.G., M.L.), Department of Cardiology (S.G.S.), and Department of Radiology (S.G.S.), North Shore University Hospital, Northwell Health, Zucker School of Medicine at Hofstra/Northwell, and the Multimodality Cardiovascular Imaging Laboratory, North Shore University Hospital, Northwell Health (S.G.S.), Manhasset, New York.

Keywords: Echogenicity, Hyperechoic, Tissue characterization, Fatty metaplasia
Conflicts of interest: The authors report no conflicts of interest relative to this document.

Copyright 2020 by the American Society of Echocardiography. Published by Elsevier Inc. This is an open access article under the CC BY-NC-ND license (<http://creativecommons.org/licenses/by-nc-nd/4.0/>).

2468-6441

<https://doi.org/10.1016/j.case.2020.07.007>

VIDEO HIGHLIGHTS

Video 1: Transthoracic echocardiography, four-chamber cine. The echocardiogram shows hyperechoic basal to mid inferoseptal segments and normal echogenicity in the apical septum. The basal to mid inferoseptum demonstrates similar echogenicity to the anterior aspect of the interatrial septum, a known region of lipomatous infiltration.

Video 2: Transthoracic echocardiography, interventricular septum. The echocardiogram reveals a sharp demarcation in echogenicity between the hyperechoic basal to mid inferoseptum and the apical septum, which appears normal in echogenicity. The clear demarcation in echogenicity corresponds with segmental wall motion findings. The hyperechoic segments appear akinetic, while the apical septum shows normal wall motion. As correlated with computed tomography and invasive coronary angiography, the hyperechoic segments represent myocardial infarction with fatty metaplasia.

Video 3: Transthoracic echocardiography, short-axis mid-ventricular cine. The short-axis view at the level of papillary muscle shows an akinetic, hyperechoic inferior segment.

Video 4: Invasive coronary angiography. Right coronary artery angiography shows total occlusion of the proximal vessel.

[View the video content online at www.cvcasejournal.com.](http://www.cvcasejournal.com)

myocardium in the apical septum, as well as fat in the anterior aspect of the interatrial septum. Review of prior invasive coronary angiography (Figure 1D, Video 4) revealed total occlusion of the proximal right coronary artery.

DISCUSSION

The process of fatty metaplasia may occur within fibrotic scar tissue that develops secondary to a myocardial infarction. The ability to characterize myocardial tissue by cardiovascular magnetic resonance and to some extent computed tomography allows for the recognition of fatty metaplasia within infarcted myocardium. Limitations in echocardiography, however, tend to preclude specific assessment of the underlying myocardial tissue. In this report we provide a correlation between myocardial echogenicity in a region of chronically infarcted myocardial tissue and evidence of fatty metaplasia on computed tomography.

A prior study in healthy subjects with no history or echocardiographic evidence of heart disease demonstrated increased echogenicity within the interventricular septum.¹ The authors evaluated

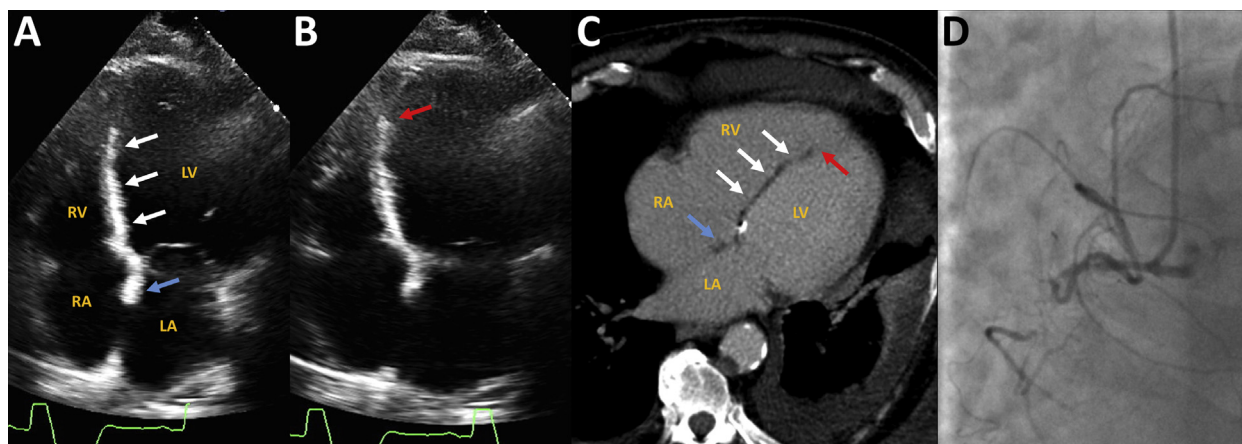


Figure 1 Transthoracic echocardiography in the four-chamber view at end-diastole (**A**) and end-systole (**B**) demonstrates a hyperechoic, akinetic, hyperechoic region in the basal to mid inferoseptum (*white arrows*). A sharp demarcation exists between the hyperechoic, akinetic basal to mid inferoseptal segments and the apical septum, which demonstrates normal wall motion (*red arrow*). The anterior aspect of the interatrial septum demonstrates similar echogenicity to the hyperechoic region of the inferoseptum (*blue arrow*). (**C**) Contrast-enhanced computed tomography shows a region of low density compatible with fat in the interventricular septum (*white arrows*) that correlates with the hyperechoic zone noted on echocardiography. Computed tomography also shows a clear delineation between the fat in the interventricular septum and the normally enhancing myocardium in the apical septum (*red arrow*), as well as lipomatous infiltration of the anterior interatrial septum (*blue arrow*). (**D**) Invasive coronary angiography reveals total occlusion of the proximal right coronary artery.

differences in strain between the left and right ventricular aspects of the interventricular septum. Their findings supported the hypothesis that the linear zone of increased echogenicity may result from the acoustic interface at an abrupt change in fiber direction.

In this case, however, the multimodality imaging findings suggest that the hyperechoic segments at least partially represent fat. The hyperechoic region extends transmurally toward the left ventricular aspect of the interventricular septum and sharply terminates at the border of the akinetic and normally thickening myocardium. The hyperechoic area also spatially correlates with the region of fat noted on computed tomography.

The differential diagnosis for hyperechoic myocardium also includes other pathologic processes that occur in a chronic myocardial infarction, such as fibrosis and calcification. Fibrotic tissue replaces necrotic myocardium after a myocardial infarction. Increased myocardial echogenicity reflects the collagen content of scarred myocardium.² Myocardial calcification may also appear in chronic myocardial infarctions, with a reported occurrence of 8% in infarcts >6 years of age.³

Lipomatous metaplasia develops within the majority of chronic myocardial infarctions. Su *et al.*⁴ reported that among 168 healed myocardial infarctions detected in explanted hearts of patients undergoing transplantation for ischemic cardiomyopathy, 141 (84%) demonstrated histologic evidence of fat within the healed infarct. In patients with a history of myocardial infarction who underwent cardiovascular computed tomography, Ichikawa *et al.*⁵ showed that 33 of 53 patients (62%) demonstrated evidence of fat deposition in the left ventricle. Moreover, computed tomography detected evidence of fat in 30 of the 35 patients (86%) with infarcts ≥ 3 years of age.

The hyperechoic myocardium we observed therefore likely reflects the combination of lipomatous metaplasia and replacement fibrosis in a chronic myocardial infarction. In the appropriate clinical context, the

combination of akinesis and hyperechogenicity may prompt the consideration of a chronic myocardial infarction with fatty metaplasia and indicate correlation with other imaging modalities.

CONCLUSION

Myocardial hyperechogenicity may reflect underlying pathology in a chronic myocardial infarction with fatty metaplasia.

SUPPLEMENTARY DATA

Supplementary data related to this article can be found at <https://doi.org/10.1016/j.case.2020.07.007>.

REFERENCES

1. Boettler P, Claus P, Herbots L, McLaughlin M, D'hooge J, Bijnens B, et al. New aspects of the ventricular septum and its function: an echocardiographic study. *Heart* 2005;91:1343-8.
2. Montant P, Chenot F, Goffinet C, Poncelet A, Vancraeynest D, Pasquet A, et al. Detection and quantification of myocardial scars by contrast-enhanced 3D echocardiography. *Circ Cardiovasc Imaging* 2010;3:415-23.
3. Nance JW Jr, Crane GM, Halushka MK, Fishman EK, Zimmerman SL. Myocardial calcifications: pathophysiology, etiologies, differential diagnoses, and imaging findings. *J Cardiovasc Comput Tomogr* 2015;9:58-67.
4. Su L, Siegel JE, Fishbein MC. Adipose tissue in myocardial infarction. *Cardiovasc Pathol* 2004;13:98-102.
5. Ichikawa Y, Kitagawa K, Chino S, Ishida M, Matsuoka K, Tanigawa T, et al. Adipose tissue detected by multislice computed tomography in patients after myocardial infarction. *J Am Coll Cardiol Img* 2009;2:548-55.