

2020

Erratum: A large right ventricle and severe hypoxemia. Use of bedside transesophageal echocardiography to assess cardiopulmonary failure (Annals of the American Thoracic Society (2020) 17 (112-115) DOI: 10.1513/AnnalsATS.201904-316CC)

A. Agrawal

Northwell Health, aagrawal1@northwell.edu

M. Frank

A. Tsegaye

Zucker School of Medicine at Hofstra/Northwell, atsegaye@northwell.edu

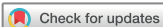Follow this and additional works at: <https://academicworks.medicine.hofstra.edu/articles>

 Part of the [Internal Medicine Commons](#)

Recommended Citation

Agrawal A, Frank M, Tsegaye A. Erratum: A large right ventricle and severe hypoxemia. Use of bedside transesophageal echocardiography to assess cardiopulmonary failure (Annals of the American Thoracic Society (2020) 17 (112-115) DOI: 10.1513/AnnalsATS.201904-316CC). . 2020 Jan 01; 17(4):Article 7318 [p.]. Available from: <https://academicworks.medicine.hofstra.edu/articles/7318>. Free full text article.

This Article is brought to you for free and open access by Donald and Barbara Zucker School of Medicine Academic Works. It has been accepted for inclusion in Journal Articles by an authorized administrator of Donald and Barbara Zucker School of Medicine Academic Works. For more information, please contact academicworks@hofstra.edu.



Erratum: A Large Right Ventricle and Severe Hypoxemia. Use of Bedside Transesophageal Echocardiography to Assess Cardiopulmonary Failure

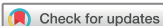The authors would like to make a correction to the legends of Videos 1 and 3 in their article published in the January 2020 issue of *AnnalsATS* (1). The definition for the abbreviation TEE in these video legends should read “transesophageal echocardiogram.” For the convenience of our readers, *AnnalsATS* is replacing the online version

of the article with a corrected version; we apologize for the error.

Reference

- 1 Agrawal A, Frank M, Tsegaye A. A large right ventricle and severe hypoxemia. Use of bedside transesophageal echocardiography to assess cardiopulmonary failure. *Ann Am Thorac Soc* 2020;17:112–115.

Copyright © 2020 by the American Thoracic Society



Erratum: What is the Source? Identifying the Cause of Septic Shock in a Patient


The authors would like to correct the author order in their article published in the February 2020 issue of *AnnalsATS* (1). The correct author order should be as follows: Nimrita Sidhu, Noor Ul-Ain Baloch, and Yonatan Greenstein. For the convenience of our readers, *AnnalsATS* is replacing the online

version of the article with a corrected version; we apologize for the error.

Reference

- 1 Sidhu N, Baloch NU, Greenstein Y. What is the source? Identifying the cause of septic shock in a patient. *Ann Am Thorac Soc* 2020;17:236–239.

Copyright © 2020 by the American Thoracic Society

 This article is open access and distributed under the terms of the Creative Commons Attribution Non-Commercial No Derivatives License 4.0 (<http://creativecommons.org/licenses/by-nc-nd/4.0/>). For commercial usage and reprints, please contact Diane Gern (dgern@thoracic.org).