

2020

Carbapenemase producing *Klebsiella pneumoniae* (KPC) meningitis from chronic otitis media

S. Anwar
Northwell Health

S. Acharya
Northwell Health

S. Thapa

J. Rabadi

N. Mobarakai
Zucker School of Medicine at Hofstra/Northwell

Follow this and additional works at: <https://academicworks.medicine.hofstra.edu/publications>

 Part of the [Infectious Disease Commons](#)

Recommended Citation

Anwar S, Acharya S, Thapa S, Rabadi J, Mobarakai N. Carbapenemase producing *Klebsiella pneumoniae* (KPC) meningitis from chronic otitis media. . 2020 Jan 01; 22():Article 7322 [p.]. Available from: <https://academicworks.medicine.hofstra.edu/publications/7322>. Free full text article.

This Article is brought to you for free and open access by Donald and Barbara Zucker School of Medicine Academic Works. It has been accepted for inclusion in Journal Articles by an authorized administrator of Donald and Barbara Zucker School of Medicine Academic Works. For more information, please contact academicworks@hofstra.edu.



Carbapenemase producing *Klebsiella pneumoniae* (KPC) meningitis from chronic otitis media

Shamsuddin Anwar*, Sudeep Acharya, Sakura Thapa, Jacob Rabadi, Neville Mobarakai

Staten Island University Hospital, Northwell Health, United States

ARTICLE INFO

Article history:

Received 7 September 2020

Received in revised form 20 September 2020

Accepted 20 September 2020

Keywords:

Infectious disease

Klebsiella pneumoniae

Meningitis

ABSTRACT

Meningitis and brain abscess caused by carbapenemase-producing *Klebsiella pneumoniae* (KPC) is rarely described in the medical literature. Such infections have been described after neurosurgical medium or post-trauma. We describe an unusual case of KPC meningitis originating from with long term intravenous antibiotics.

© 2020 The Authors. Published by Elsevier Ltd. This is an open access article under the CC BY-NC-ND license (<http://creativecommons.org/licenses/by-nc-nd/4.0/>).

Introduction

Carbapenemase producing enterobacteriaceae such as *Klebsiella pneumoniae* are well recognized infections across the globe. These infections have gained importance because it is not only resistant to many antimicrobials; they pose a serious challenge for clinicians for effective treatment options. We report an unusual case of chronic otitis media leading to meningitis in a patient presenting from home.

Abstract

Meningitis and brain abscess caused by carbapenemase-producing *Klebsiella pneumoniae* (KPC) is rarely described in the medical literature. Such infections have been described after neurosurgical medium or post-trauma. We describe an unusual case of KPC meningitis originating from chronic otitis media and subsequent resolution with long term intravenous antimicrobials.

Case report

A 68-year old female with a past medical history of stable chronic obstructive pulmonary disease, hypertension, non-small cell lung carcinoma in remission, aortic aneurysmal repair, and splenectomy presented from home with acute left-sided worsening otalgia. The patient gradually developed symptoms three months prior to the presentation which worsened over the past

week and was prescribed amoxicillin-clavulanate and eardrops with no improvement of the symptoms. The pain was constant sharp, severe, involving the left side of her face with no relieving factors and affecting the left side hearing. No other motor or sensory deficits and nuchal rigidity were reported. On physical examination, the patient was found to have pre and post auricular tenderness with no temporal tenderness. The ear canal was clear with no visible drainage, tympanic membrane was mildly erythematous.

Vital signs were within normal limits (temperature 36.7 C, respiratory rate 12 with SpO2 99 % on room air, heart rate 88 bpm, and blood pressure 165/80 mmHg) with no evidence of SIRS on admission. The initial blood workup had a white cell count of 8,000 / μ L with normal neutrophil, lymphocyte count, hemoglobin on 10.8 g/dL, and platelet 350,000/ μ L along with a normal comprehensive metabolic panel.

Emergent computed tomographic study of the head was obtained which demonstrated clouding of the left mastoid air cells associated with fluid in the left middle ear suggestive of acute left mastoiditis and otitis media. Blood cultures were obtained, and the patient was prophylactically started on vancomycin and cefepime with ofloxacin ear drops. Given the unusual presentation of unilateral facial pain, trigeminal neuralgia was considered as a differential diagnosis and she was initially kept on carbamazepine. A CT scan with intravenous contrast of the orbits re-demonstrated left-sided mastoiditis and otitis media without osseous erosion however, the left petrous apex showed inflammation suggestive of meningitis (with no clinical evidence of meningeal signs) and cranial fossa osteomyelitis (Fig. 1). The patient underwent lumbar puncture and CSF analysis (Table 1) with cultures were obtained.

* Corresponding author.

E-mail address: shamsduhs15@gmail.com (S. Anwar).

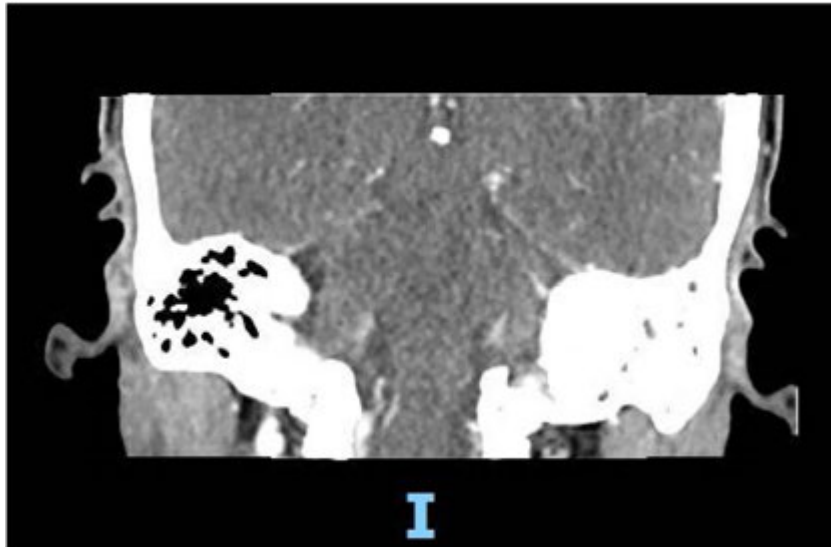


Fig. 1. CT orbits with contrast.

Table 1
CSF Analysis.

CSF color	Slight Pinkish
Appearance	Clear
Total CSF Nucleated Cell count	22
CSF RBC	397
CSF Neutrophils	40 %
CSF Lymphocytes	52 %
CSF Macrophages/Monocytes	8 %
CSF Lactate dehydrogenase	29

When the preliminary blood and lumbar tap cultures grew gram-negative rods, the cefepime was switched to meropenem. The patient was also initiated on prophylactic valproic acid anti-epileptic and a 20-minute electroencephalogram was obtained to rule out seizures secondary to infectious etiology. A magnetic resonance imaging (MRI) of the head with and without gadolinium was obtained (Fig. 2) which demonstrated left-sided otomastoiditis and petrous apicitis with 1 cm abscess formation in the left petrous apex. Dural enhancement was also noted on the left

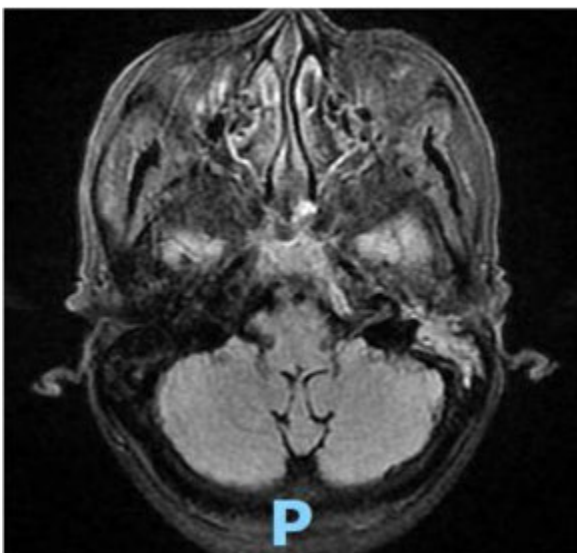


Fig. 2. MRI with and without contrast showing abscess.

Table 2
Blood culture sensitivities.

ANTIBIOTICS	SENSITIVITIES
Amikacin	S< = 16
Ampicillin	R>16
Ampicillin/Sulbactam	R>16
Aztreonam	R>16
Cefazolin	R>16
Cefepime	R>16
Cefoxitin	S< = 8
Ceftazidime/Avibactam	S< = 4
Ceftolozane/Tazobactam	R 8
Ceftriaxone	R>32
Ciprofloxacin	R 2
Gentamicin	S< = 2
Imipenem	I 2
Levofloxacin	I 1
Meropenem	S< = 1
Piperacillin/Tazobactam	R 64
Tigecycline	S< = 2
Tobramycin	S< = 2
Polymyxin B	S< = 0.25
Colistin	S 1

Table 3
CSF culture sensitivities.

ANTIBIOTICS	SENSITIVITIES
Amikacin	S< = 16
Ampicillin	R>16
Ampicillin/Sulbactam	R>16
Aztreonam	R>16
Cefepime	R>16
Ceftazidime/Avibactam	S< = 4
Ceftolozane/Tazobactam	R 8
Ceftriaxone	R>32
Gentamicin	S< = 2
Meropenem	S< = 1
Tobramycin	S< = 2

middle cranial fossa and left cerebellopontine angle cistern extending into the internal auditory canal, left prepontine cistern, and left tentorium consistent with meningitis.

When initial blood and CSF cultures resulted in carbapenemase-producing *Klebsiella pneumoniae* (KPC), the antibiotic coverage was switched to polymyxin and ceftazidime/avibactam

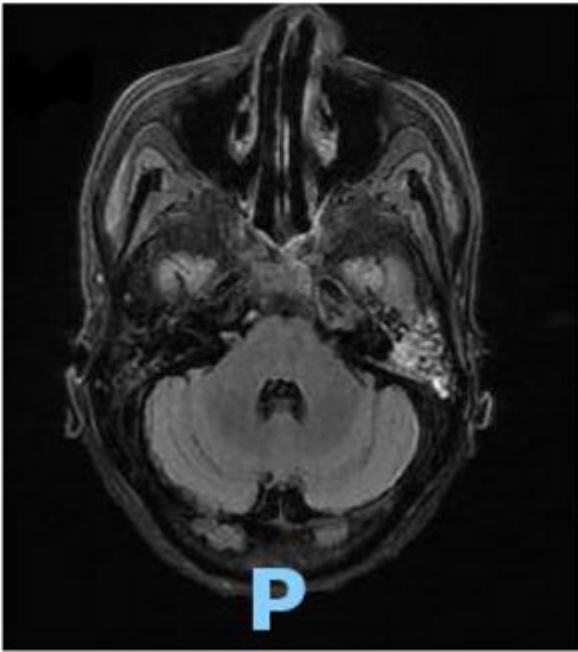


Fig. 3. Repeat MRI showing resolution of the abscess.

with improvement in the symptoms. When the final cultures resulted (Tables 2 and 3) the patient was transitioned to polymyxin and meropenem/vaborbactam. The blood cultures and lumbar puncture was repeated to document clearance of bacteremia and infection in the CSF fluid. All the repeat cultures were resulted in negative. An external ear canal culture was also collected to check for colonization was negative. The patient was discharged home to complete the antibiotic course of polymyxin for two weeks and ceftazidime/avibactam for six weeks from the first day of negative blood and CSF culture along with outpatient follow up at the infectious disease clinic.

The patient was followed up after finishing the antibiotic course. She demonstrated no new complaints with the resolution of her symptoms. A repeat MRI of the head was obtained which showed interval improvement of the leptomeningeal enhancement (Fig. 3).

Description

Antimicrobial resistance to carbapenem through carbapenem hydrolyzing beta-lactamase (carbapenemase) in a gram-negative organism is well-known in current infectious disease literature. This antimicrobial resistance on the molecular level has been classified based on various sub-groups- Class A, D, and B including NDM-1. In the United States, carbapenemase-producing *Klebsiella* (KPC) infections are most reported which belongs to Class A. The epicenter for Class B, NDM-1 is described in Europe and Indian subcontinents whereas Class D is noted in Europe and the Middle East [1].

Class A organisms are characterized by their unique beta-lactam hydrolytic enzymes conferring them with resistance to penicillin, cephalosporins, and carbapenems. These features may either be chromosomally encoded or transmitted via plasmids. KPC has acquired the resistance through the transmissible plasmids and a spectrum of KPC enzymes have been identified providing a variety of susceptibility profiles to antibiotics in these carbapenem-resistant organisms [2]. KPC has been described as a causative agent for serious nosocomial infections like pneumonia, urinary tract infections, intra-abdominal

infections, and septicemia. Some evidence is also available suggesting intestinal and nasopharyngeal mucous membrane colonization and subsequent emergence as an opportunistic infection in critically ill patients, however, the risk factors are not properly understood. Community-acquired infections due to KPC are less commonly reported [3,4]. An ear canal culture of our patient was obtained to check for colonization with KPC, which was negative.

Several common characteristics have been described of individuals with KPC infection which include age >70 years, comorbidities like COPD, diabetes, renal insufficiency, malignancy, immunocompromised states, and residence at skilled nursing and long-term facilities. Though it is interesting to note approximately 28 % population presenting with KPC can come from a community with no recent exposure to healthcare-related facilities [5]. Our patient who presented from home had several of these characteristic risk factors—COPD, history of non-small cell carcinoma in remission, and immunocompromised state due to splenectomy. KPC meningitis majorly results as a post neurosurgical/traumatic complication. The most unique fact about our clinical scenario was that meningitis and abscess formation occurred as an ascending infection from possible chronic otitis media, such presentation and occurrence of community-acquired meningitis has not been described in medical literature to the best of our knowledge [6,7].

The optimal treatment of carbapenemase-producing organisms like KPC is dependent upon the available antibiotic susceptibility data. The use of novel beta lactam-beta lactamase inhibitor combination like ceftazidime/avibactam agents has shown promising results due to better safety profile, reliable dosing, and appropriate susceptibility rates [8]. Serious infections with carbapenemase-producing organisms such as meningitis are often associated with a very high mortality rate and the rationale to use combination therapy has shown to improve the survival benefit [9]. Our patient showed significant improvement in combination therapy with polymyxin and ceftazidime/avibactam, supporting its use for KPC infections.

Conclusion

In this case report, we discuss an unusual case of KPC bacteremia and meningitis without evident clinical symptoms and signs and originating likely from chronic otitis media. The patient was successfully managed with long term intravenous antibiotics in combination therapy. The medical literature suggests that complicated KPC infections pose a serious threat with a high mortality rate. Our case report stands among the few clinical cases with good clinical outcomes.

Authorship contributions

Category 1

Conception and design of study: S. Anwar, S. Acharya, N. Mobarakai.

Acquisition of data: J. Rabadi, S. Thapa.

Analysis and/or interpretation of data: S. Anwar, N. Mobarakai.

Category 2

Drafting the manuscript: S. Anwar, S. Acharya, S. Thapa.

revising the manuscript critically for important intellectual content: N. Mobarakai, J. Rabadi.

Category 3

Approval of the version of the manuscript to be published (the names of all authors must be listed): S. Anwar, S. Acharya, S. Thapa, J. Rabadi, N. Mobarakai.

Acknowledgements

All persons who have made substantial contributions to the work reported in the manuscript (e.g., technical help, writing and editing assistance, general support), but who do not meet the criteria for authorship, are named in the Acknowledgements and have given us their written permission to be named. If we have not included an Acknowledgements, then that indicates that we have not received substantial contributions from non-authors.

References

- [1] van Duin D, Doi Y. The global epidemiology of carbapenemase-producing Enterobacteriaceae. *Virulence* 2017;8(4):460–9, doi:http://dx.doi.org/10.1080/21505594.2016.1222343.
- [2] Wolter DJ, Kurpiel PM, Woodford N, Palepou MF, Goering RV, Hanson ND. Phenotypic and enzymatic comparative analysis of the novel KPC variant KPC-5 and its evolutionary variants, KPC-2 and KPC-4. *Antimicrob Agents Chemother* 2009;53(2):557–62, doi:http://dx.doi.org/10.1128/AAC.00734-08.
- [3] Martin RM, Bachman MA. Colonization, infection, and the accessory genome of *Klebsiella pneumoniae*. *Front Cell Infect Microbiol* 2018;8:4, doi:http://dx.doi.org/10.3389/fcimb.2018.00004 Published 2018 Jan 22.
- [4] Khatri A, Naeger Murphy N, Wiest P, et al. Community-acquired pyelonephritis in pregnancy caused by KPC-Producing *Klebsiella pneumoniae*. *Antimicrob Agents Chemother* 2015;59(8):4375–8, doi:http://dx.doi.org/10.1128/AAC.00553-15.
- [5] van Duin D, Perez F, Rudin SD, et al. Surveillance of carbapenem-resistant *Klebsiella pneumoniae*: tracking molecular epidemiology and outcomes through a regional network. *Antimicrob Agents Chemother* 2014;58(7):4035–41, doi:http://dx.doi.org/10.1128/AAC.02636-14.
- [6] Xu M, Fu Y, Fang Y, et al. High prevalence of KPC-2-producing hypervirulent *Klebsiella pneumoniae* causing meningitis in Eastern China. *Infect Drug Resist* 2019;12:641–53, doi:http://dx.doi.org/10.2147/IDR.S191892 Published 2019 Mar 18.
- [7] Samuel Sophie, Edwards Nancy J, et al. Ceftazidime-Avibactam for the treatment of post-neurosurgical meningitis caused by a *Klebsiella pneumoniae* carbapenemase (KPC)-producing *Klebsiella pneumoniae*. *Open Forum Infectious Diseases* 2016;3(December (suppl_1)):1182, doi:http://dx.doi.org/10.1093/ofid/ofw172.885.
- [8] van Duin D, Lok JJ, Earley M, et al. Colistin Versus Ceftazidime-Avibactam in the treatment of infections due to carbapenem-resistant enterobacteriaceae. *Clin Infect Dis* 2018;66(2):163–71, doi:http://dx.doi.org/10.1093/cid/cix783.
- [9] Qureshi ZA, Paterson DL, Potoski BA, et al. Treatment outcome of bacteremia due to KPC-producing *Klebsiella pneumoniae*: superiority of combination antimicrobial regimens. *Antimicrob Agents Chemother* 2012;56(4):2108–13, doi:http://dx.doi.org/10.1128/AAC.06268-11.